



Study Of Supratrochlear Foramen Of Humerus And Its Applied Aspects

Archana Chaudhary¹, Vineeta Tiwari², R. K. Verma³, Geetanjali Srivastava⁴, Tahsin Munsip⁵

¹Tutor, ²Professor, ³Associate Professor, ^{4,5}Assistant Professor,

Department of Anatomy,

¹Government Medical College, Azamgarh

^{4,5}Era University, Lucknow

³KGMU, Lucknow

***Corresponding Author:**

Archana Chaudhary

Tutor, Department of Anatomy, Government Medical College, Azamgarh

Type of Publication: Original Research Paper

Conflicts of Interest: Nil

Abstract

Introduction: The supratrochlear foramen is a variable shaped perforation present in the bony septum, which separates the olecranon fossa and coronoid fossa at the distal end of the humerus between the two epicondyles. This bony septum can be either opaque or translucent and in some cases, may be perforated to form a foramen called supratrochlear foramen. Supratrochlear foramen has been designated by a variety of names such as olecranon foramen, septal aperture or epitrochlear foramen. This foramen lies between the two humeral condyles that is why it is also known as intercondylar foramen. This foramen predominantly occurs in two shapes: oval and round with oval being the most common shape.

Materials and Methods: The present study was conducted in Department of anatomy at ERA University, Lucknow in collaboration with Department of Anatomy KGMU, Lucknow. A Total of 250 dried humeri of unknown sex and age were studied. The presence of supratrochlear foramen was noted. Various shapes of this foramen were studied and its vertical and transverse diameter were measured by using digital Vernier calipers.

Results: Out of 250 bones, the supratrochlear foramen was present in 37 humeri, showing the incidence as 14.8% humeri. We observed various type of shapes of foramen in our study.

Conclusion: The supratrochlear foramen was present in 14.8% of humeri. The oval shape supratrochlear foramen was found to be the most prevalent type among all shapes

Keywords: Supratrochlear foramen, supratrochlear notch, humeri

Introduction

The humerus is the longest and largest bone in the upper limb and has expanded ends and a shaft. The distal end of the humerus is a modified condyle, it is wider transversely and has articular and non-articular parts.⁽¹⁾ The articular part articulates with the radius and the ulna at the elbow joint, and is divided by a faint groove into a lateral capitulum, and a medial trochlea. The nonarticular part of the condyle includes the medial and lateral epicondyles, olecranon, coronoid and radial fossae.

The olecranon fossa is a deep hollow on the posterior surface of the condyle, immediately above the trochlea. It lodges the tip of the olecranon process of the ulna when the elbow is extended. A similar but smaller hollow lies immediately above on the anterior surface of the condyle and is termed the coronoid fossa. A very slight depression lies above the capitulum on the lateral side of the coronoid fossa.⁽¹⁾

The supratrochlear foramen is present in the bony septum, which separates the olecranon fossa and

coronoid fossa at the distal end of the humerus between the two epicondyles.⁽²⁾ This bony septum can be either opaque or translucent and in some cases, may be perforated to form a foramen called supratrochlear foramen.⁽³⁾ This septum is present till 7 year of age, there after it is occasionally absorbed to form supratrochlear foramen.⁽³⁾ Supratrochlear foramen has been designated by a variety of names such as olecranon foramen, septal aperture or epitrochlear foramen.⁽²⁾ This foramen lies between the two humeral condyles, also known as intercondylar foramen. The incidence of supratrochlear foramen varies between 6-60% in different races of humans.⁽⁴⁾ This foramen predominantly occurs in three shapes: oval, triangular and round with oval being the most common shape.⁽⁵⁾ Reniform shape is also very common according to the study of Mathew et al.⁽²⁾

There are two theories regarding the formation of the supratrochlear foramen- the mechanical theory and the genetic theory.⁽⁵⁾ The mechanical theory proposes that the supratrochlear foramen is formed as a consequence of the perforation of the bony septum caused by the articulation of the ulna and distal aspect of the humerus during extension and flexion. This foramen may occur, either unilaterally or bilaterally. In unilateral cases, the supratrochlear foramen is predominantly present on the left humerus.⁽⁵⁾ The genetic theory states that supratrochlear foramen is an inherited trait. Frequencies of occurrence in different population favour this theory.⁽²⁾

The detailed knowledge of supratrochlear foramen is important for surgeon during the pre-operative planning for treatment of most common supracondylar fracture of humerus.⁽⁴⁾ Verification of the presence of supratrochlear foramen is helpful for successful surgical correction of fractures of the humerus. For example, corrective surgery of a fracture involving intramedullary fixation, insertion of a nail/rod into the vertical length of the humerus to stabilize the fracture site. In humerus with a supratrochlear foramen, the medullary canal tends to be shorter and have a narrower diameter than without foramen. This shorter medullary canal and narrowing may pose difficulties in intramedullary

fixation.⁽⁵⁾ In cases of humeral fractures of the supratrochlear foramen, the surgeon should keep in mind that it is better to perform an antegrade medullary nailing than a retrograde one; as there is higher chance of a secondary fracture due to the extreme narrowness of the canal at the distal portion of humerus with the supratrochlear foramen.

Prior anatomical knowledge about the presence of supratrochlear foramen may lead to erroneous interpretation of x-rays,⁽⁶⁾ as it appear as a radiolucent structure and may be mistaken for cystic or osteolytic lesion.⁽⁴⁾ The knowledge of foramen is of great help to the anthropologists who claim it as one of the important points in establishing relationship between man and lower animals.⁽⁴⁾ The knowledge of supratrochlear foramen may be beneficial for anthropologists, orthopaedic surgeons and radiologists in day to day clinical practice.⁽⁷⁾

Materials And Methods

The present study was conducted in the Department of Anatomy, Era University, Lucknow in collaboration with the Department of Anatomy, KGMU Lucknow. A total of 250 (137 right side +113 left side) dried humeri of unknown sex and age were studied. The presence of supratrochlear foramen was noted and its various shapes were studied. The vertical and transverse diameters were also measured by using Digital Vernier Calipers. The statistical analysis was carried out by using ANOVA- test. The method of collection of data for the present study was based on the study done by A B. Mahitha et al.⁽⁸⁾ Transverse diameter (TD) of the supratrochlear foramen was measured from the maximal width of the supratrochlear foramen measured along the maximum concavity from the medial margins to the lateral margins. Vertical diameter (VD) of the supratrochlear foramen was taken by the maximal vertical distance from the superior to inferior margins of the supratrochlear foramen. The present study was done over a duration of one year. It was an observational study. In this study, 250 dried adult humeri were analyzed. The study was done to assess the prevalence of morphological and morphometric variations of supratrochlear foramen in Indian population and its comparison with previous studies

Observation And Results

The photographs of variation in shapes of supratrochlear foramen found in the humeri were given below

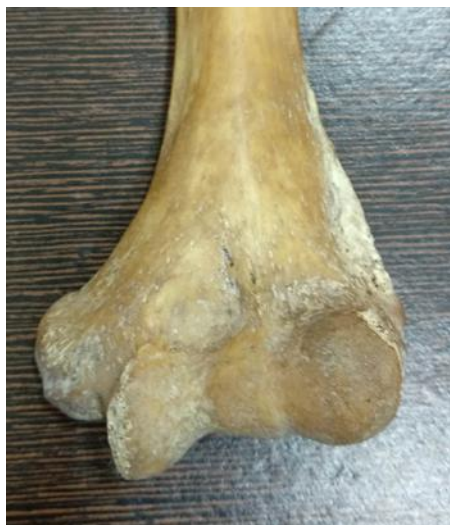

Fig1: Absence of supratrochlear foramen

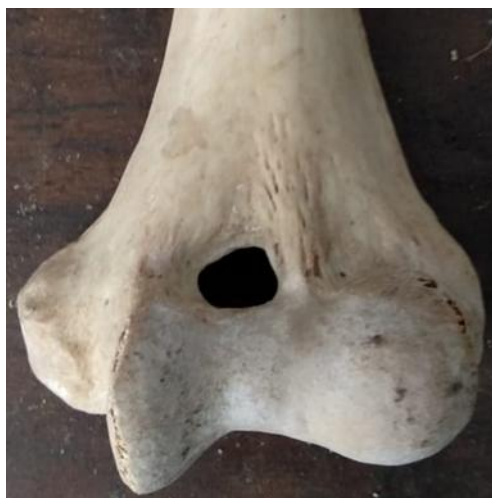

Fig2: Irregular shape

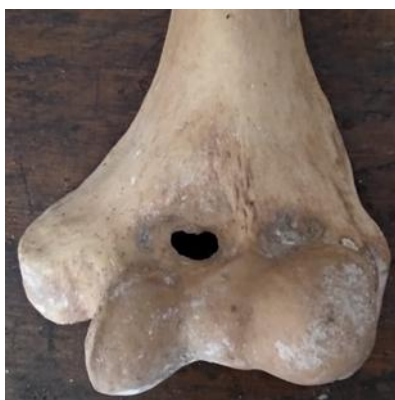

Fig 3: Reniform shape



Fig4: Round shape



Fig5: Triangular shape

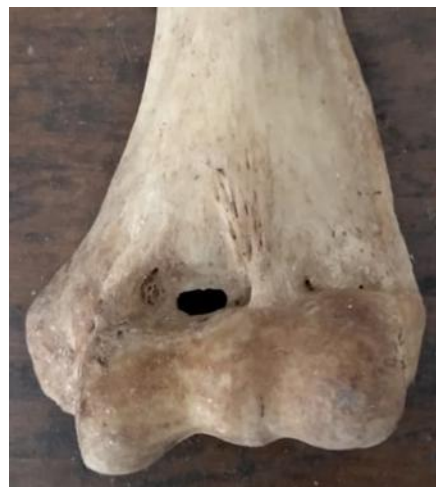

Fig6: Rectangular shape



Fig7: Oval shape

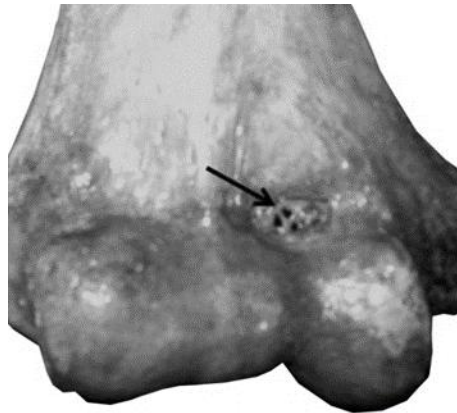


Fig 8: Seive shape

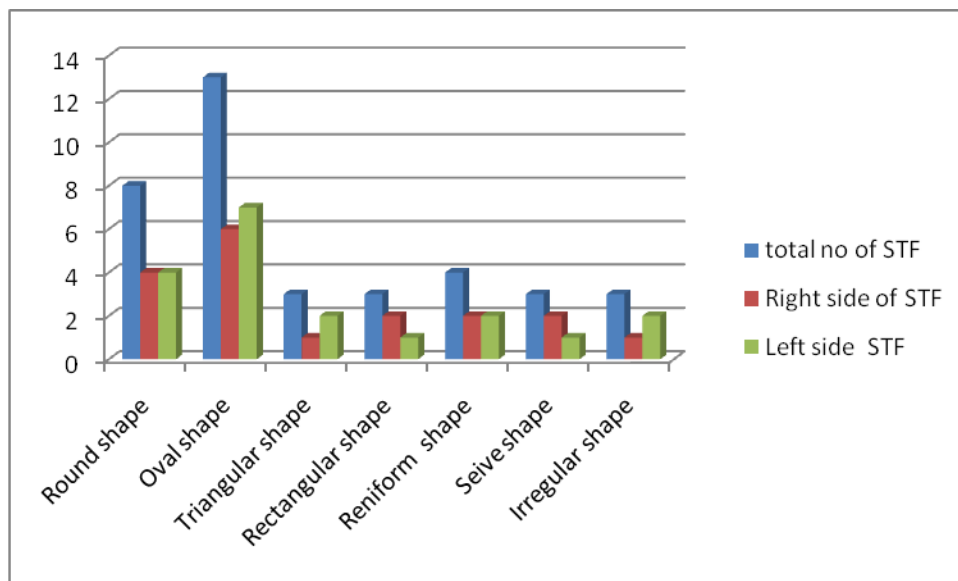


Fig 9: Bar diagram showing proportionate ratio of presence of supratrochlear foramen (STF) of right side and left side

Table 1. Classification of humerus (n=250) according to shape of supratrochlear foramen

S.N.	Shape of supratrochlear foramen	Total Number of STF(37)	Right side STF (18)	Left side (19)
1	Round shape	8 (3.2%)	4 (1.6%)	4 (1.6%)
2	Oval shape	13 (5.2%)	6 (2.4%)	7 (2.8%)
3	Triangular shape	3 (1.2%)	1 (0.4%)	2 (0.8%)
4	Rectangular shape	3 (1.2%)	2 (0.8%)	1 (0.4%)
5	Reniform shape	4 (1.6%)	2 (0.8%)	2 (0.8%)
6	Seive shape	3 (1.2%)	2 (0.8%)	1 (0.4%)
7	Irregular shape	3 (1.2%)	1(0.1%)	2 (0.8%)

Discussion

The Supratrochlear foramen is present at the lower end of the humerus and on the upper aspect of the trochlea. The lower end represents the fossae for the articulation with the olecranon and the coronoid process of the ulna and the head of the radius. A bony septum is present between the olecranon and the coronoid fossae. This septum regresses to form a foramen which is called as supratrochlear foramen.

The high incidence of supratrochlear foramen of humerus has been the subject of many studies. According to Hirsh, the thin plate of bone is always

present between olecranon and coronoid fossa up to 7 years. This bony plate may occasionally get absorbed to form the supratrochlear foramen.(9) Most foramen provide the passage for neurovascular structures but none of the neurovascular structure passes through the supratrochlear foramen.

In the present study, 250 humeri (137 right side+113 left side) were studied for the presence of supratrochlear foramen, out of which only 37 humeri (14.8%) showed the presence of foramen. It was present in 19 left sided humeri and 18 right sided humeri

Table2: The morphology of supratrochlear foramen of humerus was studied in different population by various authors which is given below. Several morphological variations of the supratrochlear foramen were reported in these study population.

Authors	Population	Number of Humeri	Number of supratrochlear foramen and percentage
Present Study	North Indian	250	37(14.8%)
Nayak et al. (2008)	Indian	384	132(34.3%)
Mahajan.(2011)	Northwestern Indian	100	26(26%)
Ndou et al.(2012)	South African	1076	256(23.7%)
Sejal . et al. (2013)	Westen Indian	565	133(23.5%)

Jaswinder Kaur <i>et al</i> (2013)	South Indian	80	22(27%)
Myuri <i>et al.</i> (2013)	-	76	31(40%)
Diwan <i>et al.</i> (2013)	North Indian	1776	428(24.1%)
Erdogmus <i>et al.</i> (2014)	Turkish	260	50(19.2%)
Varalakshmi <i>et al.</i> (2014)	Indian	85	22(25.8%)
Kumar <i>et al.</i> (2015)	South Indian	270	57(26%)
Kumar R <i>et al.</i> (2015)	South Indian	355	76 (21%)
Mathew <i>et al.</i> (2016)	-	244	60(24.5%)
B.Mahitha <i>et al</i> (2016)	South Indian	96	18 (18.7%)
Nagajyothi <i>et al.</i> (2017)	-	108	34(31.4%)
Jagdish <i>et al.</i> (2017)	North Indian	110	30(27%)
Deshmukh <i>et al.</i> (2018)	South Indian	122	20 (16.3%)

In the present study, the shapes of the supratrochlear foramen were- oval 13(5.2%), round 8(3.2%), triangular 3(1.2%), rectangular 3(1.2%), reniform 4(1.6%), seive 3(1.2%) and irregular 3(1.2%). In the present study, oval shaped supratrochlear foramen was the commonest type, which is similar to the findings of Mathew *et al.*,⁽²⁾ Diwan *et al.*,⁽⁶⁾ Mayuri *et al.*,⁽¹²⁾ and Kumar *et al.*⁽²¹⁾ The second most common shape was round in the present study, which is in contrary to the study done by Deshmukh *et al.*,⁽⁹⁾ Shivaleela C.,⁽²⁴⁾ and Jagdish *et al.*,⁽²⁵⁾ in which they found oval shape as the second most common shape. The third common shape was reniform in present study, which is very close to the finding of Mathew *et al.*,⁽²⁾ and Deshmukh *et al.*⁹ But it is not in accordance with the study done by Mayuri *et al.*,⁽¹²⁾ Kumar *et al.*,⁽¹⁴⁾ and Diwan *et al.*,⁽⁶⁾ in which triangular shape was the third commonest type. In the present study triangular, rectangular, seive, irregular shapes were the least common type of foramen but according to the Savitha *et al.*,⁽¹⁵⁾ sieve shaped foramen is commonly present.

In the present study, the mean vertical diameter (VD) of supratrochlear foramen was observed to be

4.06±1.95mm on the left side and 3.65±1.54mm on the right side. Transverse diameter (TD) was found to be 4.75±2.26mm on the left side and 4.51±2.62mm on the right side. We found that the mean transverse diameter of supratrochlear foramen on the left side was more than the right side, which is similar to the finding of study done by Nayak *et al.*,⁽⁷⁾ Raghavendra *et al.*,⁽²⁰⁾ and Udaya kumar *et al.*,⁽²¹⁾ but in contrary to the study done by Chagas *et al.*,⁽²³⁾ Shivaleela *et al.*,⁽²⁴⁾ and Cibikkarthik *et al.*,⁽²⁶⁾ in which the diameter was larger on the right side.

The mean transverse diameter in the present study was almost similar to the study done by Mathew *et al.*,⁽²⁾ and Shivaleela *et al.*⁽²⁴⁾ In the study done by Nayak *et al.*,⁽⁷⁾ Raghavendra *et al.*,⁽²⁰⁾ Udaya kumar *et al.*,⁽²¹⁾ and Jagdish *et al.*,⁽²⁵⁾ they found diameter of higher range while Cibikkarthik *et al.*,⁽²⁶⁾ found diameter in lower range as compared to our study. The mean vertical diameter in the present study is very much similar to the study done by Nayak *et al.*,⁽⁷⁾ Raghavendra *et al.*,⁽²⁰⁾ and Kumar *et al.*⁽²¹⁾

The variability in findings can be explained on the basis of different ethnic and racial groups and could also be due to difference in the age, sex. Different

methodologies used in the studies conducted by various authors.

The knowledge of the supratrochlear foramen is of great help to the anthropologists who claim it as one of the important points in establishing relationship between man and lower animals. The presence of supratrochlear foramen is also important for radiologists and orthopaedicians for proper interpretation of x –ray as they appear radiolucent and may be mistaken for cystic or osteolytic lesion.

Conclusion

All the humerus does not present the supratrochlear foramen. In this study the supratrochlear foramen was present only in 14.8% of humeri. The shape of the supratrochlear foramen was not fixed. The different shapes of supratrochlear foramen were round, oval, triangular, rectangular, reniform, seive and irregular shaped. The oval shape supratrochlear foramen was found to be the most prevalent type among all shapes. It was found that the vertical and transverse diameters of supratrochlear foramen depend upon the shapes of it.

References

1. Standarding S Gray's Anatomy. The Anatomical basis of clinical Practice, 41th ed. London: Elsevier Churchill Livingstone;2005, p 838-839.
2. Asha Joselet Mathew , Geetha Sulochana Gopidas , Tintu Thottiyil Sukumaran. A Study of the Supratrochlear Foramen of the Humerus: Anatomical and Clinical Perspective, DOI: 10.7860/JCDR/2016/17893.7237.
3. Agarwal P, Zaidi SHH. Study of supratrochlear foramen of humerus: Amorphometric study. Internation journal of Advanced and Integrated medical sciences, Jan2017, 2(1):8-10.
4. Varalakshmi K.L ,Sweekritha Shetty, Qudsia Sulthana. Study of Supratrochlear Foramen of Humerus and Its Clinical Importance. IOSR Journal of Dental and Medical Sciences (IOSR-JDMS) e-ISSN: 2279-0853, p-ISSN: 2279-0861. Volume 13, Issue 7 Ver. II (July. 2014), PP 68-70
5. Ndou R, Smith P, Gemell R, Mohatla O. The supratrochlear foramen of the humerus in a South African dry bone sample. Clinical Anat. 2013;26:870–74
6. Diwan RK, Rani A, Chopra J, Srivastava AK, Sharma PK, Verma RK, et al. Incidence of Supratrochlear foramen of Humerus in North Indian Population. Biomedical Research. 2013;24(1):142-45.
7. Nayak SR, Das S, Krishnamurthy A, Prabhu LV, Potuic BK. Supratrochlear foramen of the humerus: An anatomico-radiological study with clinical implications. Ups J Med Sci. 2009; 114:90-94.
8. B.Mahitha., R Jitendra., V Janaki., T.Navakalyani, Supra-trochlear Foramen of humerus in telangana state: A Morphometric Study, IJAR 2016; Vol 4(2); 2450-53.
9. Deshmukh VR, Arathala R, Seth S, "The supra-trochlear foramen of the humerus : formation and clinical implication" IJSR, Feb 2018, Issue-2, Vol-7, ISSN No. 2277- 8179.
10. Paraskevas GK, Papaziogas B, Tzaveas A, Giaglis G, Kitsoulis P, Natsis K. The supratrochlear foramen of the humerus and its relation to the medullary canal: A potential surgical application. Med Sci Monit. 2010;16:BR119-23.
11. Mahajan A, Batra AP, Khurana BS. Supratrochlear foramen study of humerus in North Indians .Prof Med J2011;18:128-32.
12. Jadhav M, Tawte A, Pawar P, Mane S. Anatomical study of Supratrochlear foramen of Humerus. J Res Med Den Sci. 2013;1(2):33-35.
13. Erdogmus S. The importance of the supratrochlear foramen of the humerus in humans: an anatomical study. Med Sci Monit. 2014;20:2643-50.
14. Arun kumar K R, Manoranjitham R, Raviraj K, Dhanalakshmi V. Morphological study of supratrochlear foramen of humerus and its clinical implication. IJSR, Aug2015, Vol-3, ISSN No-2321-4221.
15. Savitha V, K R Dakshayani, "Study of Supra-trochlear foramen of humerus" IJAR 2016; vol 4/(4): 2979-83.
16. D.Nagajyothi, S. Saritha, N.Hima Bindu, T.V. Ramani, Gayatri P; Study of incidence of supra-trochlear foramen in humeri and its surgical and orthopedic significance in Telangana region, Indian journal of clinical Anatomy and Physiology, Jan2017(1), 4(1):16-19.

17. Christos P, Marios P, Apostolos S. 2011. Rare cases of humerus septal apertures in Greeks, Trends Med Res 6:178-183.
18. Patel SV, Sutaria LK, Nayak TV, Kanjiya DP, Patel BM, Aterkar SH, Morphometric study of supratrochlear foramen of humerus. International Journal of Biomedical and Advance Research. 2013;24(1);142-145.
19. Kaur J, Sing Z, Supratrochlear foramen of humerus-A Morphometric Study, Indian Journal of Basic & Applied Medical Research; June 2013:Issue-7,vol-2,P 651-654.
20. Raghavendra K, Anil Kumar Reddy Y, Shirol VS, Daksha Dixith, Desai SP. Morphometric analysis of septal aperture of humerus. Int J Med Res Health Sci, 3 (2): 269-272, (2014).
21. Udaya Kumar P., Sukumar C.D., Sirisha V., Rajesh V., Murali Krishna S., Kalpana T. Morphologic and morphometric study of supratrochlear foramen of dried human humeri of Telangana region. IJCRR-Vol 07 Issue 09, may
22. Li J, Mao Q, Li W, Li X, An anatomical study of the supratrochlear foramen of the Jining population. Turk J Med Sci, 2015;45:1369-73.
23. Carlos AA Chagas, Schlesinger GG, Tulio Leite, Lucas AS Pires, Julio G. Silva. Anatomical and Radiological Aspects of the Supratrochlear Foramen in Brazilians. Journal of clinical and Diagnosis Research, 2016 Sep, Vol-10(0); AC:10-AC13.
24. Shivaleela C., Khizer Hussain A, Lakshmiprabha S., An osteological study of supratrochlear foramen of humerus of South Indian population with reference to anatomical and clinical implication. 2016 Dec 31. doi:10.5111/acb. 2016.49.4.249.
25. Jagdis P, Kumar S., A Morphometric study of supratrochlear foramen of humerus in North Indian population. Vol -6 ISSUE-9 Sep - 2017. ISSN NO2277-8160.
26. T. Cibikkarthik, K. Yuvaraj Babu, Karthik Ganesh Mohanraj. Morphometric analysis of supratrochlear foramen and its clinical implication in dry humerus bone. Vol-10. Issue 10. 2018.
27. Silveira FC, Junior VM, Fazan VPS: Anthropometric evaluation of the humerus in the presence and absence of the septal foramen. Int J Morphol, 2007;158
28. Singhal S, Rao V: Supratrochlear foramen of the humerus. Anat Sci Int, 2007;82:105-7
29. Kate BR, Dubey PN, A Note on the septal apertures in the humerus of central Indians. Eastern Anthropologist, 1970;33:105-10
30. Singhal S, Rao V Supratrochlear foramen of the humerus. Anat Sci Int 2007;82:105-7.
31. Das S. Supratrochlear foramen of the humerus of the humerus. Anat Sci Int 2008;83:120