(International Print/Online Journal)

SJIF IMPACT FACTOR: 5.565
PUBMED-National Library of Medicine ID-101739732

ISSN (Print): 2209-2870
ISSN (Online): 2209-2862

International Journal of Medical Science and Current Research (IJMSCR)
Available online at: www.ijmscr.com
Volume 4, Issue 6, Page No: 406-413
November-December 2021

IJMSCR

Role of HRCT and 3D VR CT Images In the Evaluation of Temporal Bone Pathologies

Dr. Shamima Banu. A[1], Dr. G. Balachandiran[2]
Post Graduate[1], Professor[2]
Department of Radiology, Rajah Muthiah Medical College and Hospital, Chidambaram.

***Corresponding Author:**
Dr. Shamima Banu. A
Department of Radiology, Rajah Muthiah Medical College and Hospital, Chidambaram.

Type of Publication: Original Research Paper
Conflicts of Interest: Nil

Abstract

Background: Temporal bone contains complex anatomical organs such as organ of hearing and balance. HRCT and 3D VR images play a major role in evaluating temporal bone pathologies.

Method: A total of 75 cases were used in this study to assess the effectiveness of HRCT in the identification of temporal bone disease in the Department of Radiodiagnosis at the Rajah Muthiah Medical College & Hospital from October 2019 to October 2021.

Results: Common age group of presentation was 30-40 years with no gender predilection. Most common pathology was inflammatory (Otitis media and otomastoiditis - 45.2%) followed by fracture (18.6%) and cholesteatoma (8%). Middle ear ossicles involvement were seen in 14.6% of the study population. Incus was the most frequently eroded temporal bone structure among the ear ossicles followed by scutum (13.3%). HRCT had significant correlation with surgery for demonstrating erosions of most of the ear bone parts except SCC. Most common part of temporal bone to be fractured in this study was squamous part (50%). VR 3D demonstrated pathology in 17.1% cases. VR 3D satisfactorily demonstrated fractures and erosions due to tumor. Most common tumor was acoustic neuroma. Peak age of presentation was 30-40 years.

Conclusion: Before planning for a surgery, clinical examination alone is not enough in recent days due to complications & recurrences of various diseases, Imaging has a major role in the treatment.

Keywords: HRCT-high resolution computed tomography, VR-volume rendered, 3D-three dimensional, SCC-superior semi-circular canal

Introduction

Out of various imaging modalities, CT & MRI are the most used technique1 in the evaluation of temporal bone. HRCT, a modification of routine CT, gives an excellent resolution and hidden minute structures such as sinus tympani, semicircular canal, facial nerve canal & otic capsule can be well seen in the HRCT.2 Along with HRCT, reconstructed 3D Volume Rendered images are used for better visualisation of temporal bone in case of trauma and erosion.

The purpose of this prospective study is to detect the temporal bone pathologies using HRCT & 3D Volume Rendered reconstruction techniques and to correlate with the surgical findings.

Aims And Objectives

1. To study the extent of middle ear pathologies and their complications using HRCT.
2. To compare the HRCT finding with 3D VR images in case of trauma.
3. To study the normal variants, congenital anomalies, tumors, traumatic and infective pathologies of temporal bone using HRCT.
4. To compare the HRCT findings with surgical findings.

Materials & Methods

A total of 75 cases were used in this study to assess the effectiveness of HRCT in the identification of temporal bone disease. Patients who were having symptoms related to middle ear pathologies were subjected to HRCT of the temporal bone.

This study took place in the Department of Radiodiagnosis at the Rajah Muthiah Medical College & Hospital from October 2019 to October 2021.

All of the HRCT scans were done at our hospital on a 16 slice Toshiba Aquilion Lightning computed tomography equipment.The axial and coronal (supine or prone) axes were scanned on the patients. Before beginning the scan, all patients had scouting films taken. Scanning began at the inferior margin of the external auditory meatus and progressed upward to the arcuate prominence of the superior semicircular canal as observed on the lateral topogram. To avoid gantry tilt and to shield the lens from radiation, the head was slightly extended. From the cochlea to the posterior semicircular canal, coronal pictures were taken perpendicular to the axial plane. At a 120KV tube voltage, contiguous 1mm thick slices were created at 3mm intervals using an ultra high algorithm with a scan duration of 4 seconds. The chosen mA was 100. The noise level is lower at 120KV, bone penetration is better, and beam hardening is minor.Soft tissue differentiation is better at 100 mA. While a scan length of 4 seconds improves image sharpness, it also increases the risk of motion artefacts. CT scans are typically obtained or shown in two planes: axial and coronal. Sections are taken at a plane 300 degrees above the anthropologic base line for axial imaging.

From obtained HRCT data sets, VR 3D images were created in VITREA software workstation. To identify the pathologies, VR 3D photos were analysed in all planes and angles and interpreted using axial and coronal images.VR parameter changes are made utilising the given options, which include basic, bone, and soft tissue. To correlate with HRCT pictures, the best possible choice that could illustrate the pathology was used.

Results

The mean age of males was 33.8±17.3 years and females were 34.9±15.8 years. The difference of mean ages was not statistically significant (P>0.05). The mean age of the total subjects was 34.3 ±16.6 years with range of 2-70 years.

The majority of the individuals in the research had more than one clinical indication.The most frequent symptom was ear pain (N=30, 31.9%), which was followed by ear discharge (N=25, 26.5%). Hearing loss has been discovered in 14.8%.

ig-1: Percentage of HRCT Diagnosis Distribution

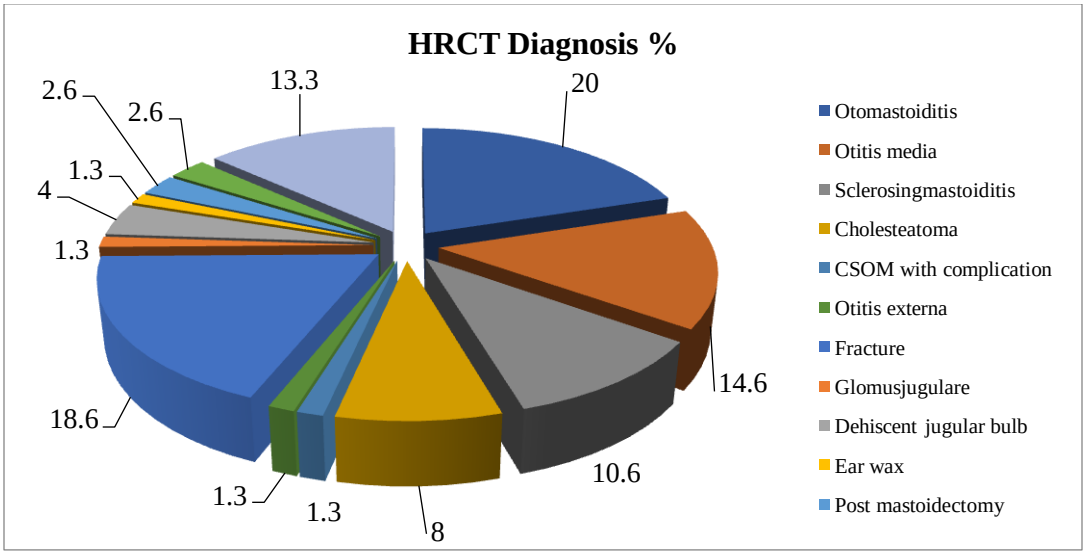

Most common HRCT diagnosis was otomastoiditis (20%) followed by fracture (18.6%) and otitis media (14.6%). Other frequent pathologies are cholesteatoma, sclerosing mastoiditis and dehiscent jugular bulb

Volume 4, Issue 6; November-December 2021; Page No 406-413

Fig-2: Percentage of Demonstration of VR 3D Reconstruction

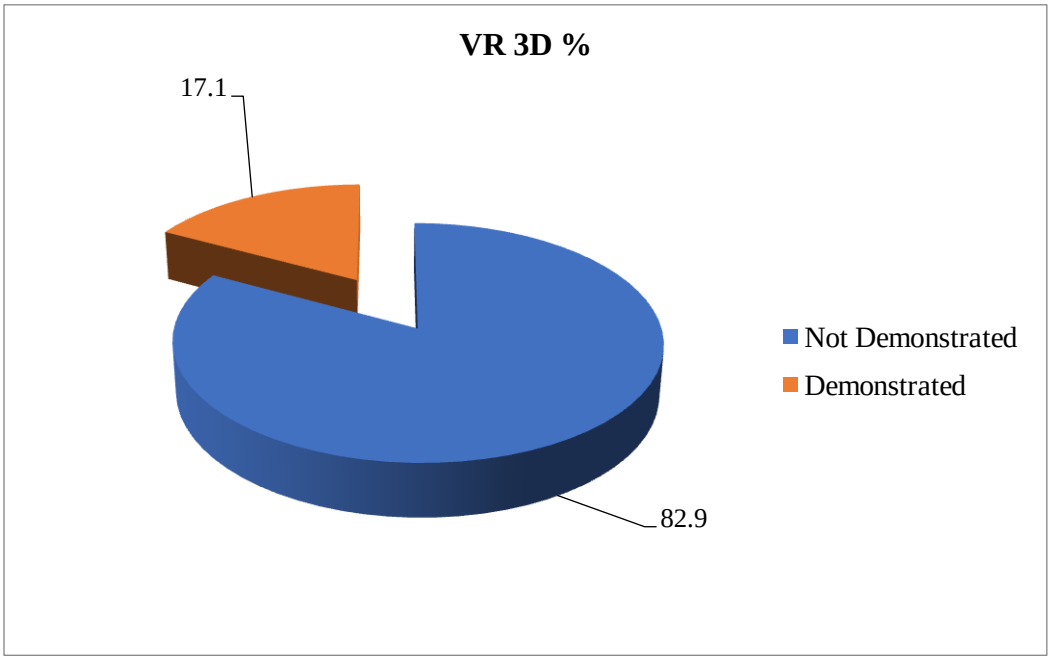

VR 3D images were demonstrated in 17.1% cases of which most of the cases were fracture and glomus jugulare.

The 31.6% of them were performed surgery and 68.4% were not performed with surgery. The difference between them was statistically very highly significant (P<0.001).

Fig-3: Percentage of Fracture distribution

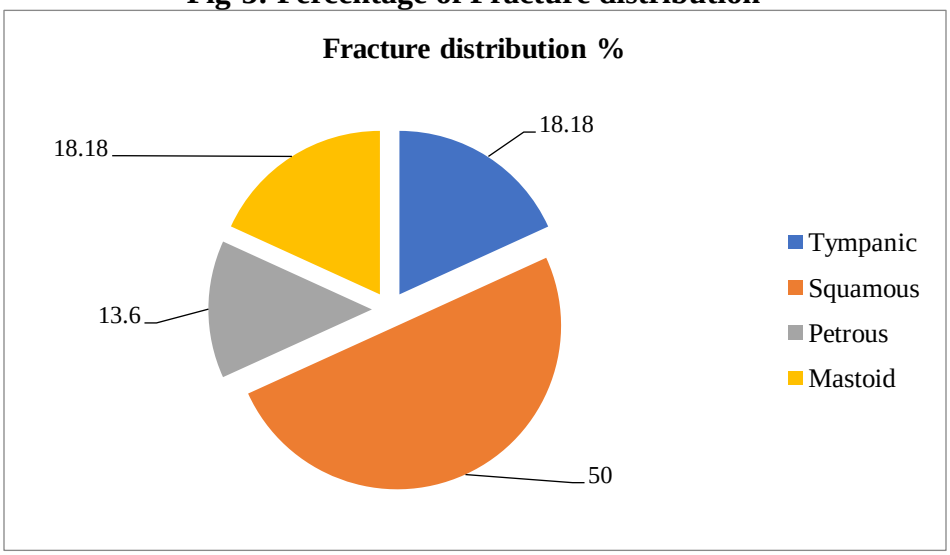

Fracture distribution was commonly seen in squamous part (N=11, 50%) followed by tympanic and mastoid part representing 18.1%

Volume 4, Issue 6; November-December 2021; Page No 406-413

Fig-4: HRCT appearance and operative findings

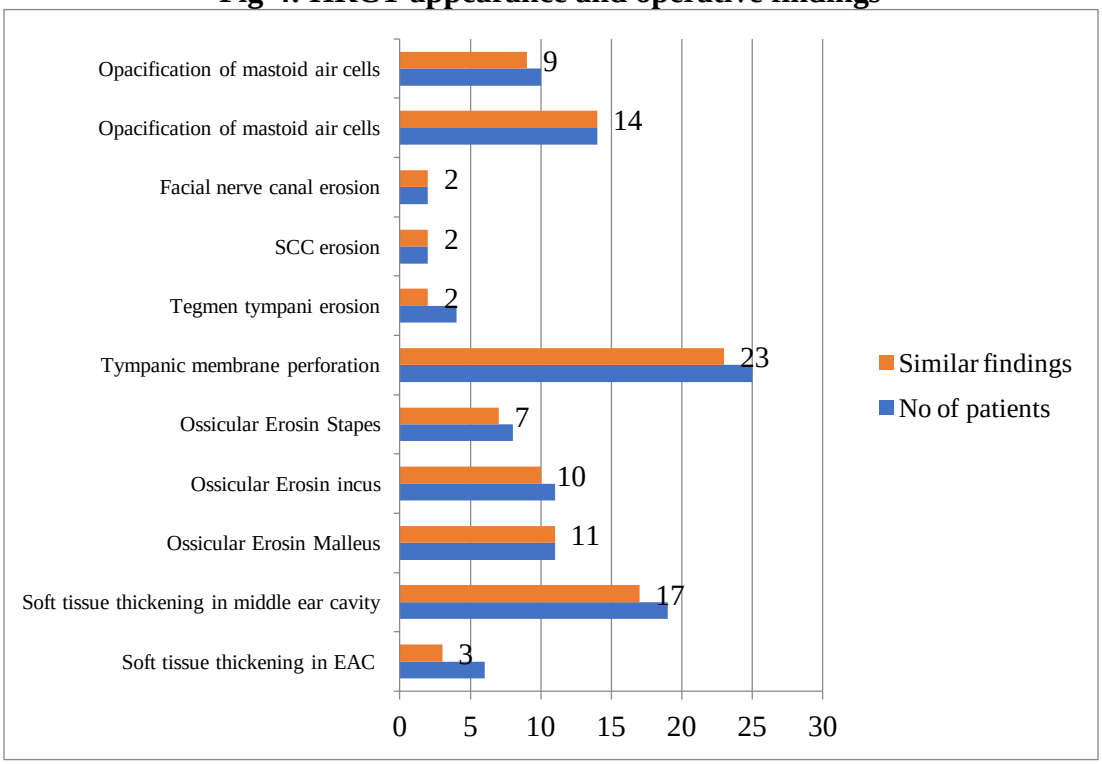

Most of the cases have similar operative findings compared to HRCT findings. Ossicular involvement was most commonly seen in incus and malleus

Fig-5: VR 3D image showing fracture in the squamous part and zygomatic process of temporal bone

Volume 4, Issue 6; November-December 2021; Page No 406-413

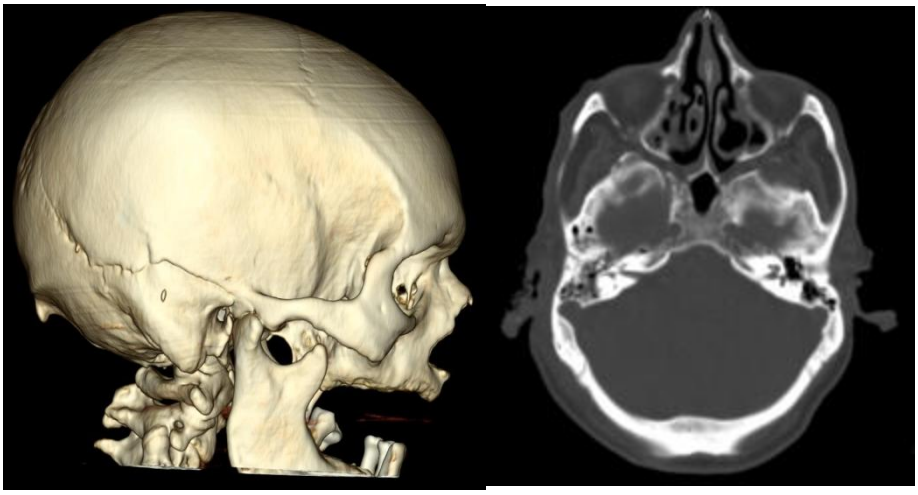

Fig-6:3D VRimage showing fracture line in the mastoid part of right temporal bone. HRCT axial image showing fracture in the mastoid part of right temporal bone and hemotympanum

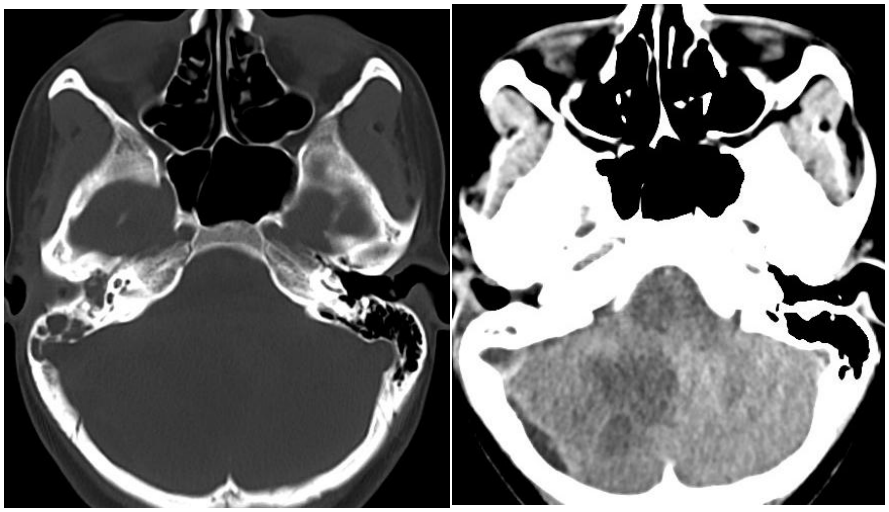

Fig-7: Axial CT image bone windowshowing soft tissue opacification seen in right middle ear cavity and mastoid air cells. On brain window shows subdural collection along the lateral aspect of right cerebellum with a hypodense collection seen within the right cerebellum

Volume 4, Issue 6; November-December 2021; Page No 406-413

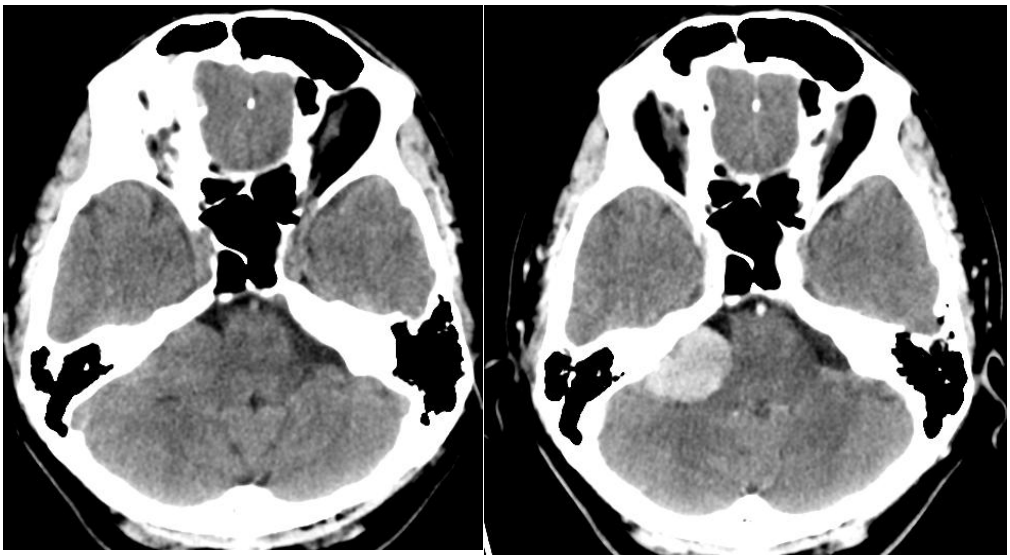

Fig-8: Axial CT image shows vestibular schwannoma-isodense mass lesion at the right cerebellopontine angle. On contrast it enhances strongly

Fig-9: Coronal CT image showing soft tissue opacification in left middle ear with erosion of long process of incus, blunting of scutum and tegmen tympani erosion

Discussion

This study of 75 cases had most patients of the age group 30-40yrs without any major difference for gender predilection for temporal bone involvement. Temporal bone pathologies evaluated by Vivek R et al3 by studying 50 patients had similar age group 20-40yrs as the most affected with slight male preponderance for temporal pathologies.

Majority had unilateral ear involvement right (42.6%) being the most involved ear. Bilateral involvement were seen in 18.6% of cases. Varied incidence is seen about bilateral involvement in literatures. 3.57% bilateral involvement was reported by Gomaa et al.4

Ear pain (31.9%) followed by ear discharge (26.5) and hearing loss (14.8) was the common clinical indication for HRCT in the present study. Bagu.M et al5 studied 120 cases had hearing loss (65%) as the most common clinical presentation followed by ear discharge (58%).

Frequent pathology in this study was inflammatory (45.2%), followed by fracture (18.6%) and cholesteatoma (8%). The reason for the increased inflammatory pathology could be due to late presentation of the cases to our institute which receives referral from surrounding rural areas.

Middle ear ossicles involvement were seen in 14.6% of the study population. Incus was the most frequently eroded temporal bone structure and middle ear ossicle was followed by scutum (13.3%). This is in accordance with Mafee et al6 study incus as the most common ossicle involved due to least ligamentous support.

Volume 4, Issue 6; November-December 2021; Page No 406-413

As discussed by Anbarasu et al7 practically, middle ear non dependant soft tissue with bone erosions or ossicular destruction is almost always cholesteaoma and middle ear soft tissue with intact ossicles, with history of ear discharge the diagnosis is most commonly otomastoiditis. Based on literature, in our study cholesteatoma and otomastoiditis were diagnosed using HRCT.

Mohammad F. Maffee et al6 (1988) used computed tomography to look at cholesteatoma in 48 patients before surgery. The surgical findings of these patients were compared to CT results in all of them. A soft tissue mass in the attic and mastoid antrum, as well as smooth bony expansion, scalloping of the mastoid, erosion of the lateral wall of the attic, and erosion of the ossicles, are all hallmarks of cholesteatoma on CT scans. When they compared imaging alterations in the attic with surgical results, they discovered that in 90% of the cases, the radiographic interpretation and surgical findings were in agreement. Similar significant correlation was made in our study for cholesteatoma.

CT scans of ears with chronic drainage revealed aberrant soft tissue densities in the middle ear or mastoid. It was unable to tell whether or not cholesteatoma was present if the soft tissue mass was not coupled with bone erosion.

The soft tissue lumps were occasionally found to be granulation tissue or mucosal hypertrophy. The presence of aberrant soft tissue densities with bone erosion has a higher predictive value in the diagnosis of cholesteatoma. Thickening and perforations of the tympanic membrane were difficult to detect on HRCT and were better detected with otoscopy.

Neoplasm account for 2.6 percent of our findings, which differs from the findings of GAS Lloyd et al (1980)8, who claimed that neoplasms were the most common lesions. The patients in our study ranged in age from 30 to 50 years old.

Acoustic neuroma which were hypodense to isodence to the surrounding brain with dense augmentation on contrast administration. In his study, Taylor S (1982)9 found bone erosion on CT in up to 87 percent of cases. This discrepancy could be due to a variety of factors.

In this study middle, inner ear abnormalities were not clearly demonstrated in VR 3D as the tools like auto segmentation, which help in removal of separate bone parts were not available for study. Moreover most of the studies showing excellent depiction of middle and inner ear structures used higher slice MDCT machines which could provide sub millimetre collimation, less than 0.5mm slice interval and still more increased spatial resolution. Further these studies had used different software application, developed specifically for 3D imaging.10,11

Fractures, erosions of temporal bone margins demonstrated by VR 3D in this study is in accordance with the study of Howard JD et al12 describing VR 3D perspectives of demonstrating complex destructive lesions.

Conclusion

HRCT clearly reveals common pathological changes and aids in determining the abnormalities in the middle and external ears. Preoperative HRCT is a guiding path for surgeons due to the good correlation between HRCT and surgical findings of cholesteatoma. VR 3D images can demonstrate fractures and bone erosions in case of tumors. HRCT is an important technique in the management of patients with temporal bone complaints because it accurately identifies those who need surgery.

References

1. Chat virapongse, Mohammad Sarwar, Sultan Bhimani, Clarence Sasaki, Robert Chapiro, computed tomography of temporal bone pneumatisation. AJNR July- Aug 1985; 6: 551-559.
2. Virapongse C, Rothman slg, Kier EL, Sarwar M. computed tomographic anatomy of the temporal bone. AJR 1982; 139:739-749.
3. Mahammod F Mafee, Barry C Levin, Edward L Applebaum, Maiocampos, and Charles F JAMES. Cholesteatoma of the middle ear and mastoid. J. Otolaryngologic Clinics of North America 1988 May; 21 (2):265-293.
4. Gupta Vineet, Gupta Abhay, Sevarajan K. Chronic Suppurative Otitis Media Aerobic Micro biological study. Ind J Otol 1998; 4:79-82.
5. Paparella MM, Kim CS. Mastoidectomy: Larangoscope 1977: 87:1977-88.
6. Allan P Wolff, Michael A Mikhael Evanston IL and Ivan S Clric. Current concepts in

Volume 4, Issue 6; November-December 2021; Page No 406-413

neuroradiological diagnosis of acoustic neuromas. J Laryngoscope 1987 April; 97:471-476.

7. Hugh D Curtin and Peter M Som. The petrous apex. Otolaryngologic Clinics of North America 1995 June; 28: (3):473-495.
8. Lloyds GAS, Phelps PD and Du Boulay GH. High resolution computerized tomography of the petrous bone. Brit. J. Radiology 1980; 53:631.
9. TaylorS.Thepetroustemporalbone(includingthecerebello-pontineangle).Radiol Cling north Am 1982; 20: 67-86.
10. Davidson MJC, Ewing's sarcoma of the temporal bone - A case report Oral Surg Oral Med Oral Pathol 1991 Nov; 72 (5): 534-6.
11. Fitzer PM, Steffy WR. Brain and bone scans in primary Ewing's sarcoma of the petrous bone. J Neurosurgery May 1976;44.
12. Dehner LP, Peripheral and central primitive neuro ectodermal tumors. A nosological concept seeking a consensus. Arch Pathol Lab Med 1986; 110: 997-1005.

Volume 4, Issue 6; November-December 2021; Page No 406-413