(International Print/Online Journal)

SJIF IMPACT FACTOR: 5.565
PUBMED-National Library of Medicine ID-101739732

ISSN (Print): 2209-2870
ISSN (Online): 2209-2862

International Journal of Medical Science and Current Research (IJMSCR)
Available online at: www.ijmscr.com
Volume 4, Issue 6, Page No: 357-361
November-December 2021

IJMSCR

Adenoid Cystic Carcinoma of Lung: Primary or Metastatic? – A Case Report

Dr. Vishnu. K. R.[1], Dr. Jaimie Anandan.[2], Dr. Nandakumar. G.[3]
[1]Junior Resident, [2]Assistant Professor, [3]Professor,
Department of Pathology, Government Medical College, Thiruvananthapuram, Kerala

***Corresponding Author:**
Dr. Vishnu. K. R
Junior Resident, Department of Pathology, Government Medical College, Thiruvananthapuram, Kerala

Type of Publication: Case Report
Conflicts of Interest: Nil

Abstract

Adenoid cystic carcinoma occurs as primary as well as metastatic carcinoma in the lung. But a primary salivary gland adenoid cystic carcinoma metastasizing to the lung is more common than a primary adenoid cystic carcinoma of the lung. We report a case of metastasis from salivary gland adenoid cystic carcinoma to the lung.

Clinical Presentation: A 60-year-old female patient presented with cough and chest pain that was present for the 1 year before admission. Physical examination revealed reduced breath sounds over right lower lung areas (fields).

Chest X-Ray and CT Thorax revealed multiple heterogeneously enhancing lesions in both lungs, pleura and liver.

CT guided biopsy showed an infiltrating neoplasm arranged in cribriform and tubular patterns. Cells are dark staining, angulated basaloid type with scanty cytoplasm. Immunophenotype is consistent with adenoid cystic carcinoma.

Conclusions: Adenoid cystic carcinoma in lung poses a great diagnostic challenge in distinguishing between primary and secondary origins. Hence it should be correlated clinically, radiologically and histopathologically for accurate reporting

Keywords: Adenoid cystic carcinoma, Lung

Introduction

Adenoid cystic carcinoma is a malignant tumor of secretory epithelial cells of salivary glands. They occur as primary in other sites like - lung, breast, esophagus, cervix and skin appendages. More than 50% of these tumors show distant metastasis, most commonly to the lung, followed by bone, liver and brain.

In spite of having cribriform and glandular appearance, adenoid cystic carcinomas have poor prognosis. Hence identifying a primary lesion elsewhere is of prime prognostic importance whenever this lesion is encountered in the lung.

Case Presentation

We would like to report a case of metastatic adenoid cystic carcinoma.

A 60-year-old lady presented with cough of 1 year duration, with increasing intensity for the past 1 month. Associated left sided chest pain was present. On detailed evaluation, a previous history of conservative parotidectomy with post operative radiotherapy (60Gy) done 13 years back was elicited. On examination in the OPD, patient was conscious, oriented and afebrile. Breath sounds were reduced over right infra-scapular and infra-axillary areas. A chest X Ray - PA View was done, which shows multiple ovoid opacities involving bilateral lung fields. Trachea shows shift to the right. (Refer Figure

1) CT Thorax - Plain and contrast was also done. The findings were as follows. Multiple large heterogeneously enhancing lesions in both lung fields with mass effect. Section of upper abdomen shows a targetoid lesion in segment V of liver, suspicious of metastasis. The above features were in favor of a metastatic lung malignancy with mass effect. For histopathology correlation, a CT guided biopsy was taken from the lesion. (Refer Figure 2). Six linear cores of tissue were received for histopathology, and sections show fragments of a neoplasm composed of cells arranged in cribriform pattern, tubules and nests. Individual cells are oval to polygonal with scant eosinophilic cytoplasm, angulated hyperchromatic nucleus. Myoepithelial cells seen admixed with the neoplasm. Stroma shows eosinophilic basement membrane material also. (Refer Figure 3). Immunohistochemistry reveals that the tumor cells are positive for TTF-1 and CD117 (Refer Figure 4 and Figure 6). Myoepithelial cells are positive for SMA. (Refer Figure 5).Clinically and radiologically, the patient is being worked up for metastatic tumor. The patient is under regular follow up.

Images

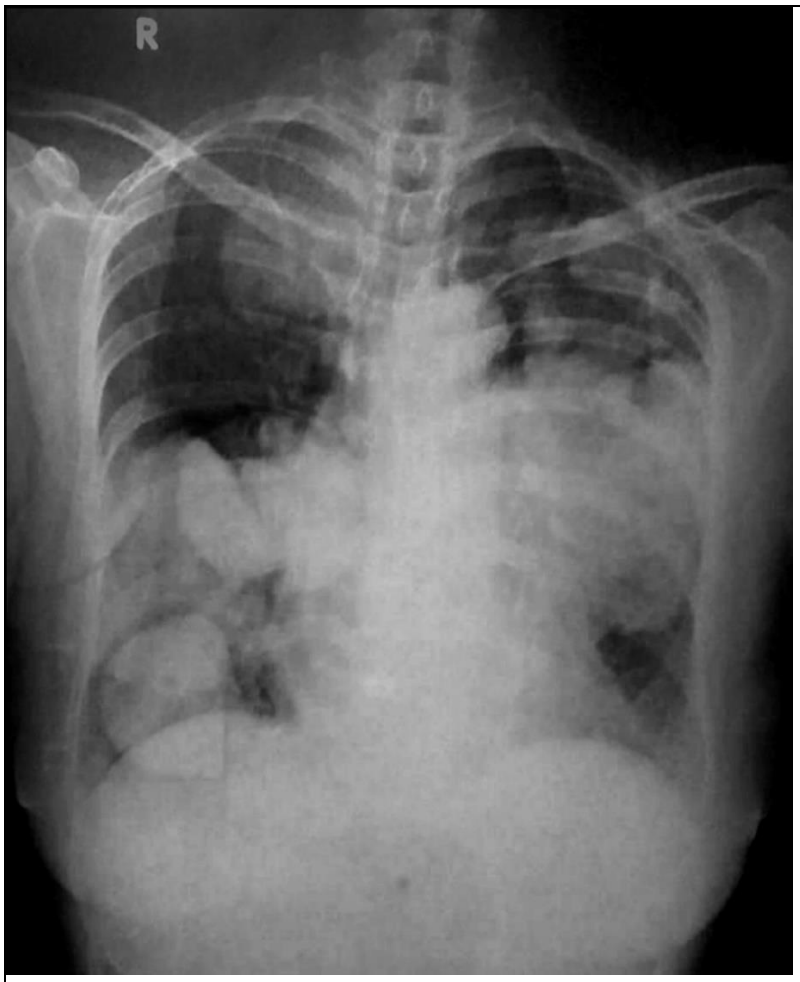

Figure 1: Chest X-Ray showing multiple opacities in bilateral lung fields.

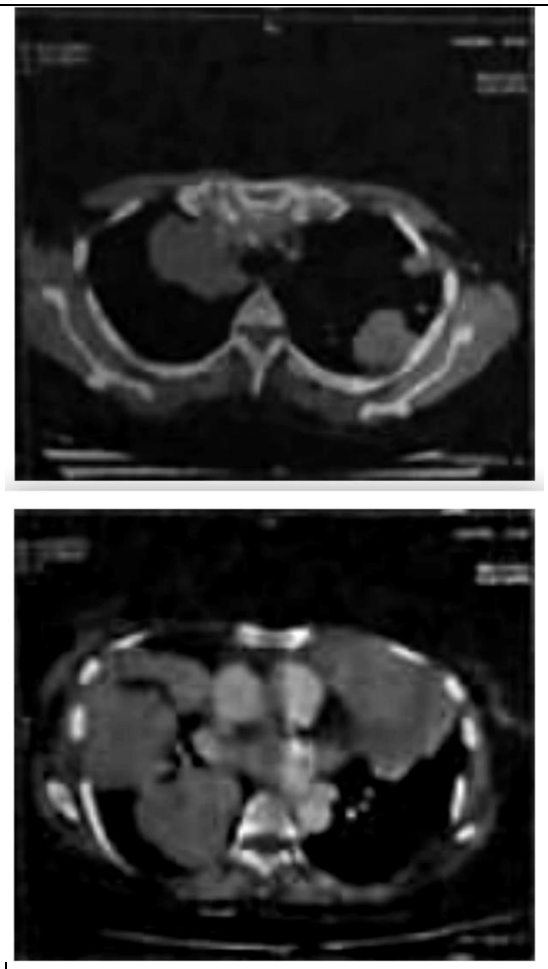

Figure 2: CECT showing multiple enhancing lesions in bilateral lung fields.

Volume 4, Issue 6; November-December 2021; Page No 357-361
© 2021 IJMSCR. All Rights Reserved

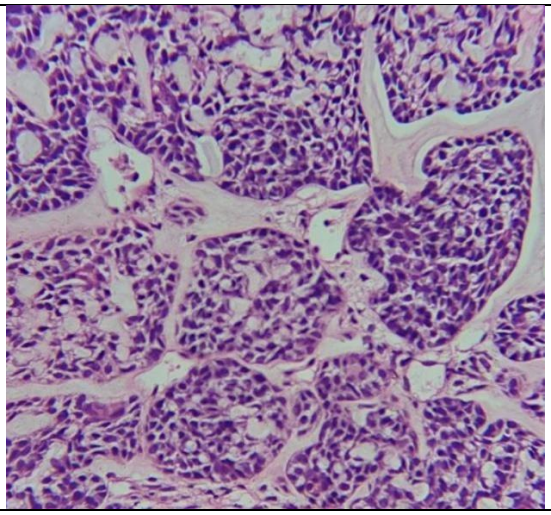

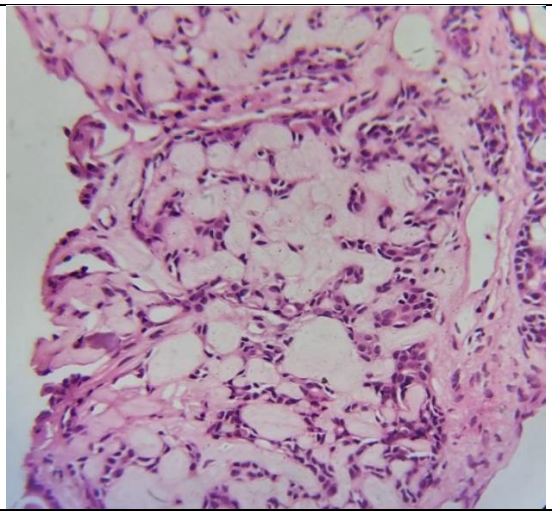

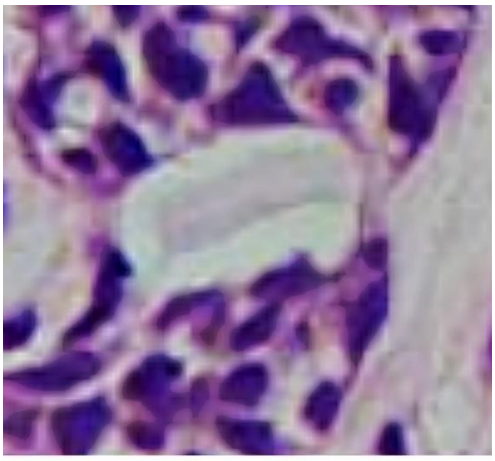

Figure 3: Microscopy of adenoid cystic carcinoma

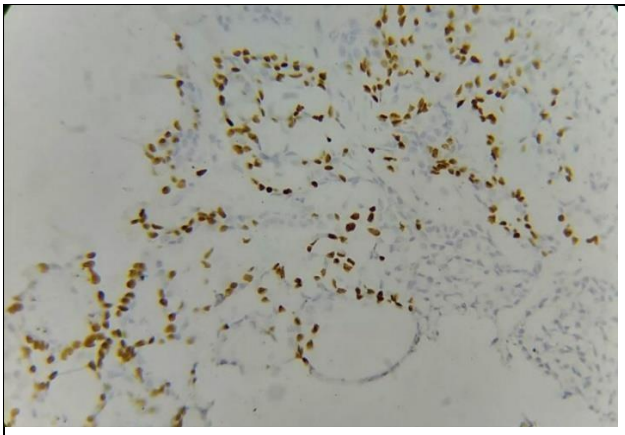

Figure 4: TTF1

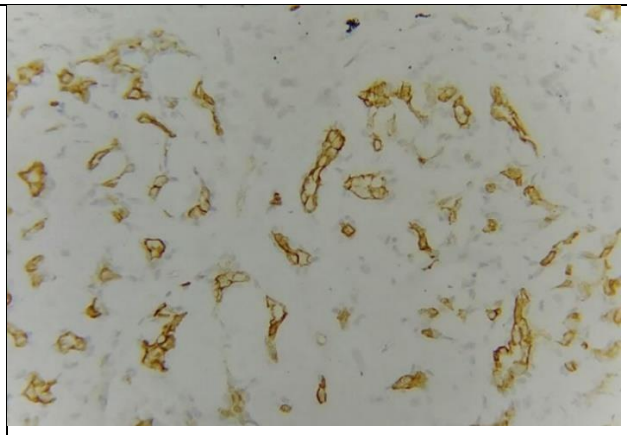

Figure 5: SMA

Volume 4, Issue 6; November-December 2021; Page No 357-361
© 2021 IJMSCR. All Rights Reserved

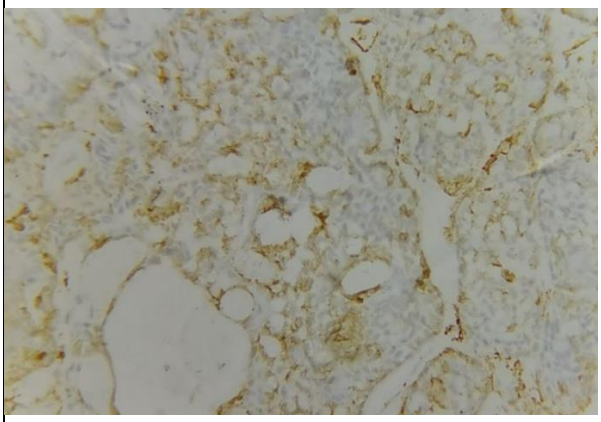

Figure 6: CD117

Discussion

Primary adenoid cystic carcinomas can occur in salivary gland, upper aerodigestive tract, lung, breast, skin appendages and cervix. For lung, it comes under malignant salivary gland type tumors. But they constitute less than 1% of all lung malignancies1. On the other hand, metastasis from primary salivary gland adenoid cystic carcinoma is relatively less rare. Adenoid cystic carcinoma is known for its propensity to late and multiple distant metastasis[2].

Metastasis to lung is common for primary salivary gland adenoid cystic carcinomas; although it constitutes only a fraction among all metastatic lesions to lung. The late onset of metastasis makes differential diagnosis more difficult[3].

In a study done by Seok J et al on 112 patients with primary salivary adenoid cystic carcinomas, 48% had distant metastasis; 94.4% of whom had lung metastasis4. Metastasis to lung from this type of neoplasm clinically presents as respiratory symptoms, reduced breath sounds on bilateral lung fields. Bilaterality and radiological findings can contribute to diagnosing it as metastasis. Radiologically, they appear as multiple targetoid nodules in both lung fields. The onset of pulmonary symptoms may take up to 16 years after previous salivary gland intervention, which warrants a very detailed history taking and examination of records from the side of the clinician[5].

A CT guided biopsy is recommended in such cases. Microscopically, the tumor is fairly circumscribed, consists of solid cellular and stromal components. Cellular areas are well demarcated from stroma by shrinkage spaces and peripheral clear cells. Cellular areas are composed of cribriform tubules of epithelial cells, admixed with clear myoepithelial cells. Longitudinal sections through these tubules appear as enclavements, and show long amorphous to fibrillary material[6].

Von Geison is used to stain the myoepithelial cells, and PAS is used to stain the fibrillary material, which hints about the content being basement membrane material[6].

Immunophenotypically, different markers are used to stain different components. The basaloid epithelial cells stain positive for Pancytokeratin, CK7, CK8/18, EMA, CD117 and CK14. Clear myoepithelial cells are positive for P63, S100, Calponin and SMA7. A particular study by Zheng Huang et al suggested lack of S100 expression in myoepithelial cells of metastatic adenoid cystic carcinomas[7].

Genetics of Adenoid cystic carcinoma is explained by MYB or MYBL1 translocations (28% - 59%), and a long list of minor mutations. In a study by Allen Ho et al in 2019, 1045 cases of adenoid cystic carcinomas were analyzed for genetic alterations. 177 of them were primary salivary gland cases and 868 were recurrent or metastatic lesions at different sites. It shows significant increase in alterations in NOTCH1, NOTCH2, NOTCH3, NOTCH4, KDM6A, KMT2C/MLL3, ARID1B and TERT promoter mutations in contrast to MYB/MYBL1 fusions[8].

The tumor has a very bad prognosis when compared to rest of salivary gland tumors. Tumors with

Volume 4, Issue 6; November-December 2021; Page No 357-361
© 2021 IJMSCR. All Rights Reserved

metastasis to lung have an even worse prognosis than another distant organ involvement9. As in our case, the patient is unfortunately having multiple lung metastatic nodules, and a resection of metastases is not planned. She is on regular follow up for any progressive worsening of symptoms.

Conclusion

In conclusion, we describe a case of metastatic adenoid cystic carcinoma of the lung, primary of which is from her salivary gland that has underwent conservative parotidectomy and post operative radiotherapy 13 years ago. The histopathological picture and immunophenotype cannot differentiate between a primary or metastatic adenoid cystic carcinoma. So, the pathologist should always think about a possible primary in the salivary glands before writing a report of primary adenoid cystic carcinoma of the lung.

Acknowledgments

I extend my thanks to Dr. Shayisha, Resident of Pathology department, Government medical college, Trivandrum for providing all the details of imaging studies done on the patient.

References

1. Board WHOCWHOCTE. Thoracic Tumours: WHO Classification of Tumours. International Agency for Research on Cancer (I A R C) (UN); 2021. https://books.google.co.in/books?id=nNdhzgEACAAJ
2. Huang H chun, Zhao L, Cao X hui, Meng G, Wang Y jun, Wu M. Primary salivary gland tumors of the lung: Two cases date report and literature review. Respiratory Medicine Case Reports. 2021;32. doi:10.1016/j.rmcr.2020.101333
3. El-Naggar AK, Chan JKC, Grandis JR, Takata T, Slootweg PJ. WHO Classification of Head and Neck Tumours. International Agency for Research on Cancer; 2017. https://books.google.co.in/books?id=EDo5MQAACAAJ
4. Seok J, Lee DY, Kim WS, et al. Lung metastasis in adenoid cystic carcinoma of the head and neck. Head & Neck. 2019;41(11). doi:10.1002/hed.25942
5. Ito M, Okita R, Tsutani Y, et al. Lung metastasis of adenoid cystic carcinoma, which mimicked primary lung cancer.Thoracic cancer. 2013;4(3). doi:10.1111/j.1759-7714.2012.00147.x
6. Osborn DA. Morphology and the natural history of cribriform adenocarcinoma (adenoid cystic carcinoma). Journal of Clinical Pathology. 1977;30(3). doi:10.1136/jcp.30.3.195
7. Huang Z, Pan J, Chen J, et al. Multicentre clinicopathological study of adenoid cystic carcinoma: A report of 296 cases. Cancer Medicine. 2021;10(3). doi:10.1002/cam4.3707
8. Ho AS, Ochoa A, Jayakumaran G, et al. Genetic hallmarks of recurrent/metastatic adenoid cystic carcinoma. The Journal of clinical investigation. 2019;129(10):4276-4289. doi:10.1172/JCI128227
9. van der Wal JE, Becking AG, Snow GB, van der Waal I. Distant metastases of adenoid cystic carcinoma of the salivary glands and the value of diagnostic examinations during follow-up. Head & Neck. 2002;24(8):779-783. doi:https://doi.org/10.1002/hed.10126

© 2021 IJMSCR. All Rights Reserved