



Rhino Sinonasal Maxillary Mucormycosis: A Rare Case Report

¹Dr. Priya Kumari, ²Dr. Satya Prakash Gupta, ³Dr. Ashutosh Kumar Gupta

^{1,2}Asst. Prof., ³M.D.S

Department Of Oral & Maxillofacial Surgery, Chandra Dental College & Hospital, Barabanki, India

***Corresponding Author:**

Dr. Sudhanshu Agrawal

drsudhanshu_bds@hotmail.com

Type of Publication: Case Report

Conflicts of Interest: Nil

Abstract

Zygomycosis of the class Zygomycetes which is more commonly called as Mucormycosis, is an opportunistic fungal infection, which mainly infects immunocompromised patients. Even now a days it is being increasingly recognized in COVID recovered patients. Mucormycosis is the most suddenly occurring fatal infection which spreads through nose, sinuses and even sometimes involves the brain which can lead to reduced blood supply and necrosis. Its very important for oral health care providers to diagnose the case in early phase to reduce the mortality. A similar case of 54 yr old male of mucormycosis of maxilla was reported in our clinic which has been presented in the article.

Keywords: Mucormycosis, Maxilla

INTRODUCTION

Paultauf in 1885, first used the term mucormycosis for a acute life-threatening opportunistic fungal infection which was caused by a filamentous fungi of class Zygomycetes.

Mucormycosis is not a very common fungal infection like candidiasis and aspergillosis which occurs in the oral cavity, it basically starts from nose and spreads to involve sinuses and sometimes brain leading to necrosis and death. Patients with uncontrolled diabetes mellitus, malignancies and other systemic infections which compromises hosts immunity are more prone to have these infections. Even acquired immune deficiency syndrome, chemotherapy and long-term steroids are high risk factors this infection.

As mucormycosis is an opportunistic infection it gets inoculated in an immunocompromised host leading to formation of thrombi and necrosis of blood vessels. It's very important for oral health care providers to diagnose the case in early phase to reduce the mortality. Therefore, this article with the help of a case report encompasses complete review on the

nomenclature, risk factors, virulent traits, early diagnostic methods and treatment modalities associated with mucormycosis.

CASE REPORT

A 54-year-old male visited to a dental clinic with a chief complaint of pain and roughness over the hard palate for 2 months, which was gradually increasing in size. He also reported regurgitation from nose while drinking and nasal stuffiness with black discharge from nose. He was diabetic in the last 5 years with poor control. On general examination there was swelling of right side of face and was unable to open his right eye in the last 3 days. [Figure 1].

In Intraoral examination there was a well-defined ulcer on right side of the palate which measured 5cm x 3cm x 0.5 cm in depth. It was covered with yellowish black slough. On hard tissue examination 16 was missing which was extracted 1 month back only. [Figure 2].

Routine blood investigations were carried out to rule out HIV, Hepatitis-B and diabetes mellitus, which showed a high blood sugar level and poor diabetic control. Computed tomography revealed areas of necrosis in maxilla suggestive of maxillary involvement. MRI of brain with orbit was also done which suggested that there were areas of necrosis and extensive extra sinus inflammation in periantral and pterigomaxillary region with hard palate, orbital and optic nerve involvement. [Figure 4,5].

Histopathology of the ulcer from the hard palate showed hyperplastic squamous epithelium with subepithelial fibrosis and chronic inflammatory cells. There was degenerating food particles and numerous non-septate branching fungal hyphae suggestive of mucormycosis.

He was started on amphotericin B (0.8 mg/kg/day) along with insulin. Presently, his sugar levels are under control and he is showing good response to therapy.

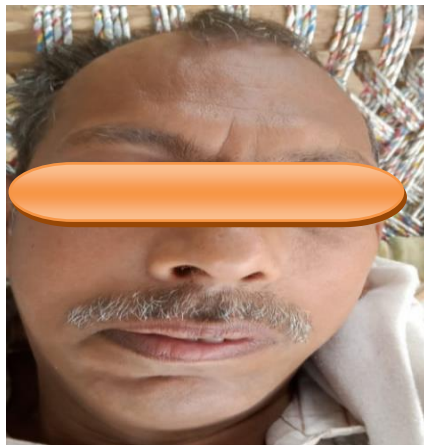

FIG 1: Extra Oral Examination

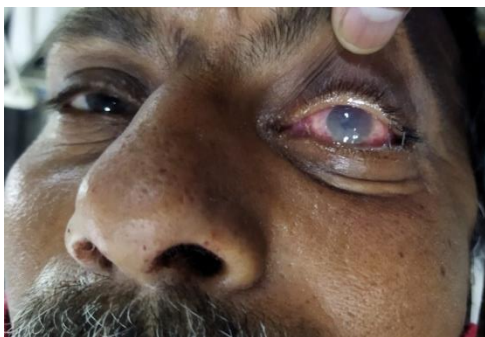

FIG 2 : Ocular Examination

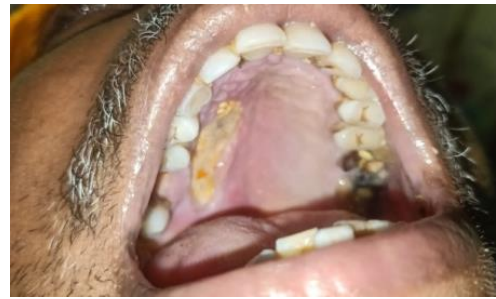

FIG. 3: Clinical Examination Showing Lesion Covered with Grayish White Slough

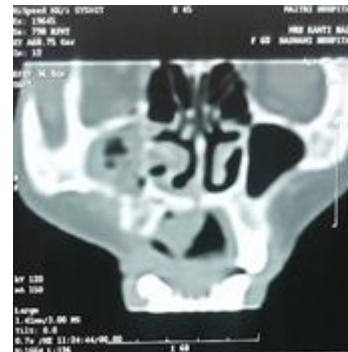

FIG. 4; CT scan Showing Bone Involvement Upto Lateral Nasal Wall

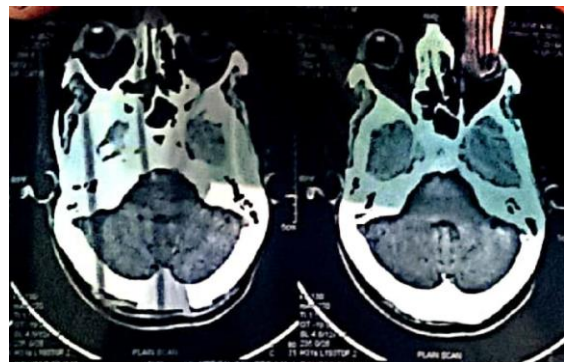


Fig. 5: MRI Showing Extensive Inflammation.

Discussion

Mucormycosis is an aggressive fungal infection. It gets inoculated by inhalation or sometimes by ingestion. The disease mostly targets patients with uncontrolled diabetes who are mostly seen in developing countries. Similarly, patients with malignancies and other systemic infections which compromises hosts immunity are more prone to have these infections. Even acquired immune deficiency syndrome, chemotherapy and long-term steroids are high risk factors this infection. In these patients' phagocytic response is the major factor for spores' inoculation.

Germination continues if the phagocytic response fails, leading to the development of hyphae; thereby, infection becomes established.

The patient who has been discussed in the case report was already an immunocompromised host as with uncontrolled diabetes mellitus, the infection started with nose and spread involving the maxilla and paranasal sinuses causing palatal ulceration and inflammation, as in cases of rhinomaxillary mucormycosis showing necrotic maxillary bone with black discoloration of mucosa of right side. After confirming the clinical findings similar to mucormycosis, it was necessary to get radiological (CT scan of the maxilla) and histopathological examinations done to rule out the suspicion of Cavernous Sinus Thrombosis. MRI was also done in our patient which also showed inflammatory changes. The Histopathological findings of mucormycosis include non-septate hyphae with tissue necrosis.

It is very necessary for health care workers to work in different fields to rule out this infection with proper diagnosis and treatment so that complications can be avoided. Treatment should be a combined effort of medicinal and surgical therapy as needed. For prevention of the disease underlying predisposing disorder, should be ruled out and treated. Since the disease has been noticed in 1885 amphotericin B is the best possible treatment which has been found to reduce the infection effectively with a survival rate of up to 72%, and survival rate of 80% when the drug is combined with surgery. But sometimes a serious complication of blindness or cranial nerve palsy can also occur. In the present case report the patient was treated with Amphotericin B and he showed a good response.

We hereby stress the importance of early diagnosis of mucormycosis to limit the dissemination of infection, thereby preventing morbidity and mortality.

Conclusion:

Mucormycosis is the most suddenly occurring fatal infection involving nose and sinuses. This is commonly seen in diabetics and immune compromised individuals. To get a 100 % result in the treatment of the disease and to reduce the

mortality rate, much more studies are needed to be performed worldwide so that patients suffering from oral mycoses are benefited and live a healthy life.

References

1. Farmakiotis D, Kontoyiannis DP. Mucormycoses. *Infect Dis Clin North Am.* 2016;30(1):143–63.
2. Brown J. Zygomycosis: an emerging fungal infection. *Am J Health Syst Pharm.* 2005;62(24):2593–6.
3. Koe Z, Koe F, Yerdelin D, Dogu O, H. Rhino-Orbital-Cerebral Mucormycosis with Different Involvement. Infarct , hemorrhage and ophthalmoplegia. *Int J Neurosci.* 2007;117(12):1677–90.
4. Bhansali A, Bhadada S, Sharma A, Suresh VP, Gupta A, Singh P, et al. Presentation And Outcome Of Rhino-Orbital-Cerebral Mucormycosis In Patients With Diabetes. *Post Grad Med J.* 2004;80(949):670–4.
5. Cohen SG, Greenberg MS. Rhinomaxillary mucormycosis in a kidney transplant patient. *Oral Surg, Oral Med, Oral Pathol.* 1980;50(1):33–38.
6. Rickerts V, Just-Nübling G, Konrad F, Kern J, Lambrecht E, Böhme A, et al. Diagnosis of invasive aspergillosis and mucormycosis in immunocompromised patients by seminested PCR assay of tissue samples. *Eur J Clin Microbiol Infect Dis.* 2006;25(1):8–13.
7. Levinson W, Jawetz E. Medical Microbiology & Immunology. 6th ed. Lange Medical Books; 2000.
8. Kirk PM, Cannon PF, David JC, Staplers JA. Ainsworth and Bisby's Dictionary of Fungi. 9th ed. Wallingford, UK: CAB International; 2001.
9. James TY, Kauff F, Schoch CL, Matheny PB, Hofstetter V, Cox CJ. Reconstructing The Early Evolution Of Fungi Using A Six Gene Phylogene. *Nature.* 2006;443(7113):818–22.
10. Keeling PJ. Congruent Evidence From Alpha-Tubulin And Beta Tubulin Gene Phylogenies For A Zygomycete Origin Of Microsporidia. *Fungal Genet Biol.* 2003;38(3):298–309.
11. Hammond SP, Badu LR, Marty FM. Mortality In

- Hemaltologic Malignancy And Hemopoietic Stem Cell Transplant Patients With Mucormyosis. *Antimicrob Agents Chemother.* 2001;55(11):5018–21.
12. Chung KJK. Taxonomy Of Fungi causing Mucormycosis And Entomophthoramycosis (Zygomycosis) And Nomenclature Of Disease; Molecular Mycologic Persepective. *Clin Infect Dis.* 2012;54(1):S8–15.
 13. Kontoyiannes DP, Lionakis MS, Lewis RE, Chamilos G, Healy M, Perego C, et al. Zygomycosis In A Tertiary-Cancer Center in Era Of Aspergillois-Active Fungal Therapy: A Case Control Observational Study Of 27 Recent Cases. *J Infect Dis.* 2005;191(8):1350–60.
 14. Chung KJK, Varma A, Edman JC, Bennett JE. Selection of *ura5* and *ura3* mutants from the two varieties of *Cryptococcus neoformans* 5-fluoroorotic acid medium. *Medical Mycology.* 1992;30(1):61–9.
 15. Hoog GSD, Guarro J, Figuera GJ, J M. Atlas of clinical fungi. 2nd ed. Utrecht, Netherlands: Centraalbureau voor Schimmelcultures (CBS); 2011.
 16. Schwartze VU, Hoffmann K, Nyilasi I, Papp T, Vágvölgyi C, d Hoog S, et al. Lichtheimia Species Exhibit Differences in Virulence Potential. *PLoS One.* 2012;7(7):e40908.
 17. Ibrahim AS, Spellberg B, Edwards J. Iron acquisition: a novel perspective on mucormycosis pathogenesis and treatment. *Curr Opin Infect Dis.* 2008;21(6):620–5.
 18. Binder U, Maurer E, Flörl CL. Mucormycosis – from the pathogens to the disease. *Clin Microbiol Infect.* 2014;20(6):60–6.
 19. Ibrahim AS. Host cell invasion in mucormycosis: role of Iron. *Curr Opin Microbiol.* 2011;14(6):406–11.
 20. Teixeira CA, Medeiros PB, Leushner P, Almeida F. Rhinocerebral mucormycosis: literature review apropos of a rare entity. *BMJ Case Rep.* 2013;.
 21. Bitar D, Cauteren DV, Lanternier F, Dannaoui E, Cha D, Dromer F, et al. Increasing incidence of zygomucosis (Mucormycosis). *Emerg Infect Dis.* 1997;15(9):1395–401.
 22. Sun HY, Singh N. Mucormycosis: Its Contemporary Phase and Management Strategies. *Lancet Infect Dis.* 2011;11(4):301–11.
 23. Walsh TJ, Gamaletsou MN, McGinnis MR, Hayden RT, Kontoyiannis DP. Early Clinical and Laboratory Diagnosis of Invasive Pulmonary, Extrapulmonary, and Disseminated Mucormycosis (Zygomycosis). *Clin Infect Dis.* 2012;54(1):S55–60.
 24. Ibrahim AS, Spellberg B, Walsh TJ, Kontoyiannis DP. *Cin Infect Dis.* 2012;54(1):S16–22.
 25. Franquet T, Giménez A, Hidalgo A. Imaging of opportunistic fungal infections in immunocompromised patient. *European Journal of Radiology.* 2004;51(2):130–8.