(International Print/Online Journal)

SJIF IMPACT FACTOR: 5.565
PUBMED-National Library of Medicine ID-101739732

ISSN (Print): 2209-2870
ISSN (Online): 2209-2862

International Journal of Medical Science and Current Research (IJMSCR)
Available online at: www.ijmscr.com
Volume 4, Issue 4, Page No: 451-454
July-August 2021

IJMSCR

Leiomyosarcoma of Lumbosacral Spine: Case report And Literature review

Dr. Ritu Sharma [1], Dr. Kaalindi Singh [2], Dr. RR Negi [3]
[1] Resident Doctor, [2] Assistant Professor [3] Professor
MD Radiotherapy, Department of Radiotherapy, SLBSMC Mandi

***Corresponding Author:**
Dr. Ritu Sharma
MD Radiotherapy, SLBSMC, Mandi, H.P, India

Type of Publication: Case Report
Conflicts of Interest: Nil

Abstract

Primary leiomyosarcoma of vertebral and paraspinal region is extremely rare. Due to rarity its diagnosis, treatment and clinical outcome remains controversial. Main stay of treatment is surgery, with or without adjuvant radiotherapy. The total en block resection is preferred surgical approach. Recurrence requires a multimodality approach of surgery adjuvant radiotherapy and chemotherapy. Here we present a case report of 42 year old lady of recurrent leiomyosarcoma of lumbosacral spine, treated with surgery twice, adjuvant radiotherapy, adjuvant chemotherapy.

Keywords: Leiomyosarcoma, leiomyoma, lumbosacral spine

INTRODUCTION

Leiomyosarcoma is an aggressive soft tissue sarcoma that originates typically from smooth muscle cells of uterus, abdominal organs, retroperitoneum and extremities. The diagnosis of primary leiomyosarcoma of spine requires exclusion of other possibilities of spinal metastasis from other primary tumor. Tissue biopsy and IHC are gold standard in establishing the diagnosis. Despite an aggressive surgical approach and use of radiation therapy and/or chemotherapy, the local recurrence rate and distant metastasis is high. In this case report we describe recurrent leiomyosarcoma arising in posterior paraspinal plane at lumbosacral region.

CASE REPORT:

A 41-year-old lady presented with complaints of low backache for 2 years, insidious and progressive. Pain radiated to both lower limbs but not associated with limb weakness, numbness with normal bowel and bladder habits. On clinical examination, a 6×6cm firm lesion in lumbar region, no sensory/ motor deficit and normal powers in all limbs. She had no co-morbidities and base line investigations were with in normal limit. MRI of whole spine showed a large well defined heterogeneous mass in posterior paraspinal deep subcutaneous plane at S1-S2 level in midline with infiltration into deep facial plane.

Patient was taken up for surgery with pre-op diagnosis of lumbosacral soft tissue tumor. She underwent wide local excision with 2cm margin. Grossly on HPE there was grey white tumor with multiple nodules. On microscopy tumor was composed of spindle cells which were SMA positive on immuno-staining. Overall diagnosis was cutaneous leiomyoma.

Patient again presented with complaint of swelling over superior aspect of operated region after 11 months of surgery. MRI evaluation of whole spine revealed T2 hypointense heterogeneous large ill-defined mass in paraspinal muscles in midline at L5-S1 level. Redo-excision was done. Histopathology diagnosis was leiomyosarcoma.

She was taken up for adjuvant radiotherapy after PET scan which revealed no metastatic lesion. Radical radiotherapy was delivered by 3D CRT technique to

the dose 50Gy /25fraction @ 2Gy/ fraction. There were no treatment breaks and no complications during radiotherapy course.

She was further taken up for adjuvant chemotherapy containing doxorubicin (30mg/m2/day), ifosfamide (3,750mg/m2/day) and mesna (750mg/m2). Adriamycin (45mg) was given from D1-D3, Ifospfamide (2gm) D1-D3, and mesna (600mg) at 0, 4,8hr D1-D3. Cycle repeated after 3 weeks. She receives 4 cycles of chemotherapy at our institute. She remained asymptomatic with no new growth, but expired after receiving fourth cycle at local hospital due to unknown cause.

DISCUSSION:

Leiomyosarcoma arise commonly from smooth muscle cells of abdominal viscera, retroperitoneal space, soft tissue of extremities and uterus. Leiomyosarcoma of spinal and paraspinal region is extremely uncommon. First case report on primary leiomyosarcoma of spine was published by Lo et al. in 1995 with an eighth thoracic vertebrae lesion and spinal cord compression 1.

Exclusion of metastatic carcinoma to spine and paraspinal region is critical before the diagnosis of primary leiomyosarcoma of spine is made. Diagnosis can be achieved through clinical and radiological investigations. X-ray, CT, MRI and PET-CT are recommended before the diagnosis of primary leiomyosarcoma spine is made. Histological examination with IHC plays crucial role in the diagnosis of leiomyosarcoma. Generally it is an aggressive tumor which is characterized by extensive infiltration with metastasis which develops in first few years after diagnosis. IHC staining often shows that leiomyosarcoma is uniformly positive for SMA and desmin, but negative for S-100 and keratin protein 2. Also, differentiation between leiomyoma and leiomyosarcoma is important to make right diagnosis especially when patient is having history of leiomyoma.

There are 11 reported cases of leiomyosarcoma of spine in literature 3. Among these 3 were male and 9 were female patients. Thoracic vertebrae was most common site with 6 patients, 2 patients had cervical vertebral involvement, 2 patients with lumbar and 2 patients with sacral vertebral involvement. Most of patients present with pain in the region of involvement.

Surgery is the main stay of treatment that can relieve symptoms and improve prognosis 4. Negative margins are required to achieve optimal outcomes but, gross total tumor resection is hindered by tumor anatomy and desire to preserve neurological functions 5. Patients with residual/recurrent tumor, adjuvant radiotherapy may help in achieving local control but not overall survival 6.

Adjuvant chemotherapy is not standard treatment in soft tissue sarcoma. However, it can be considered if the risk of relapse is high. Combination chemotherapy has demonstrated improved response rates in patients treated with doxorubicin and ifosfamide 7. Our patient was treated extensively with surgery twice, radical radiotherapy and adjuvant chemotherapy. Despite all this patient expired after 4 cycles of chemotherapy due to unknown cause at local hospital. it is consistent with the literature that there is no benefit for adjuvant chemotherapy in patients with non-metastatic leiomyosarcomas 8.

REFERENCES:

1. Lo TH, van Rooij WJ, Teepen JL, Verhagen IT. Primary leiomyosarcoma of the spine. Neuroradiology. 1995;37:465–467. [PubMed] [Google Scholar]
2. Sasaguri T, Tanimoto A, Kimura S, et al. Primary leiomyosarcoma of the vertebra: case report and review of the literature. Pathol Int 2004;54:73–6.View Full Text | PubMed | CrossRef
3. Dohi O, Hatori M, Ohtani H, et al. Leiomyosarcoma of the sacral bone in a patient with a past history of resection of uterine leiomyoma. Ups J Med Sci 2003;108:213–20.Cited Here PubMed | CrossRef
4. Primary Leiomyosarcoma of the Lumbar Spine: A Case Report and Literature Review Eric Luis, Vasanthie Balakrishnan , Zainur Anuar, bin Kamarul
5. Bahrin Bilsky MH, , Boland PJ, , Panageas KS, , Woodruff JM, , Bren-nan MF, & Healey JH: Intralesional resection of primary and metastatic sarcoma involving the spine:

Volume 4, Issue 4; July-August 2021; Page No 451-454

outcome analysis of 59 patients. Neurosurgery 49:1277–1287, 2001

6. Mahdavi A, , Monk BJ, , Ragazzo J, , Hunter MI, , Lentz SE, & Vasilev SA, et al. : Pelvic radiation improves local control after hysterectomy for uterine leiomyosarcoma: a 20-year experience. Int J Gynecol Cancer 19:1080–1084, 2009
7. Leyvraz S, , Zweifel M, , Jundt G, , Lissoni A, , Cerny T, & Sessa C, et al. : Long-term results of a multicenter SAKK trial on high-dose ifosfamide and doxorubicin in advanced or metastatic gynecologic sarcomas. Ann Oncol 17:646–651, 2006
8. Adjuvant Chemotherapy in Uterine Leiomyosarcoma: Trends and Factors Impacting Usage Dhara Patel 1, Elizabeth Handorf 2, Margaret von Mehren 3, Lainie Martin 3, Sujana Movva 3

FIGURE LEGENDS:

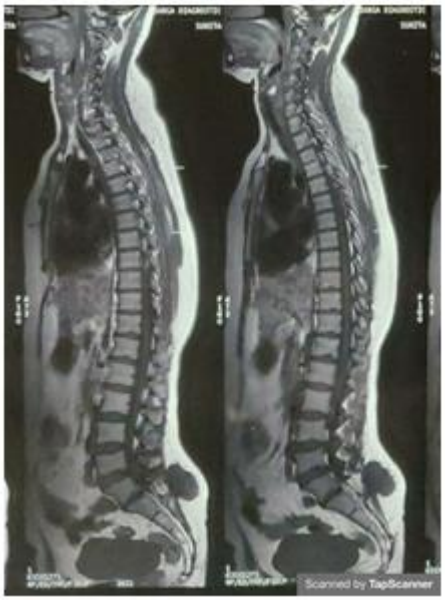

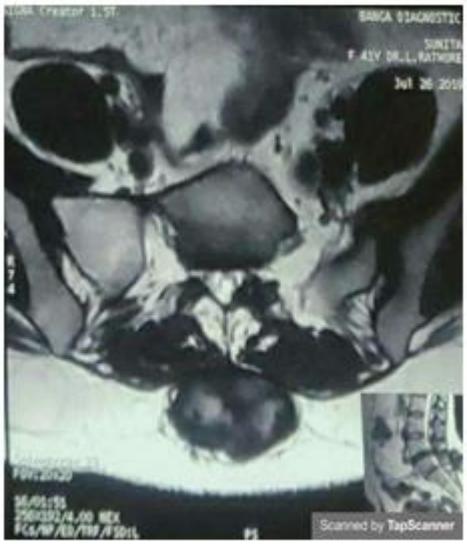

Fig-1 A well-defined mass in paraspinal deep sub-cutaneous plane at S-1, S-2 level

Fig-2 Axial MRI section showing paraspinal mass infiltrating deep facial plane.

Volume 4, Issue 4; July-August 2021; Page No 451-454

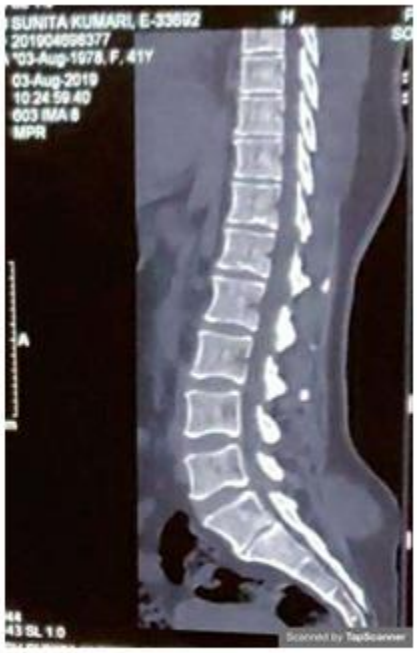

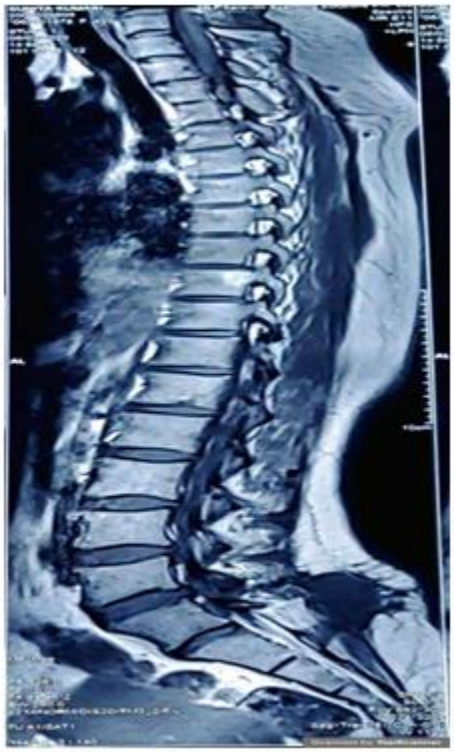

Fig-3: CECT image showing recurrent mass at S1/S2 region

Fig-4: MRI image showing ill-defined para- spinal mass L5-S1

Volume 4, Issue 4; July-August 2021; Page No 451-454