(International Print/Online Journal)

SJIF IMPACT FACTOR: 5.565
PUBMED-National Library of Medicine ID-101739732

ISSN (Print): 2209-2870
ISSN (Online): 2209-2862

International Journal of Medical Science and Current Research (IJMSCR)
Available online at: www.ijmscr.com
Volume 4, Issue 4, Page No: 26-37
July-August 2021

IJMSCR

The Role of Cell Blocks In Conjunction with Conventional Cytosmears in Microscopic Evaluation of Liver Mass Lesions

Dr. Utkarsh Sharma[1]*, Dr. Jayesh Saha[2], Dr. Arpita Jindal[3], Dr. Ranjana Solanki[4], Dr. Ajay Yadav[5]
[1]Senior Resident, [2]Fellow (Molecular Pathology), [3]Professor, [4,5]Senior Professor
[1, 3, 4, 5:] Department of Pathology, Sawai Man Singh Medical College, JLN Marg, Jaipur, Rajasthan
[2:] Department of Pathology, Malabar Institute of Medical Sciences, Kerala

***Corresponding Author:**
Dr Utkarsh Sharma
208, Tower 1, Riddhi Siddhi Residency, behind SKIT, Jagatpura, Jaipur, 302017

Type of Publication: Original Research paper
Conflicts of Interest: Nil

ABSTRACT

Background: Fine needle aspiration cytology (FNAC) from a liver space occupying lesion has procedural advantages over a core biopsy. Occasionally, conventional cytosmears lack sufficient information and diagnostic challenges are encountered. Concomitant use of thromboplastin-plasma cell blocks (TPCBs) can provide additional architectural details and allows convenient application of immunocytochemistry (ICC) which aids to the cytosmear diagnosis. The present study evaluates the role of TPCBs in conjunction with conventional cytosmears for enhancing diagnostic yield and subtyping of malignancy in liver space occupying lesions, with emphasis on differentiating hepatocellular carcinoma from metastasis.

Methods: Eighty cases of USG (Ultrasonography) guided FNACs taken from liver space occupying lesions (SOLs), clinically suspected for malignancy were included in this study. TPCBs were prepared in all the cases along with conventional cytosmears. Immunocytochemical stains were applied on cell blocks of selected cases for more definitive diagnoses.

Results: Use of cell blocks yielded more accurate diagnosis in 25 cases. Four (16%) non diagnostic conventional cytosmears were diagnosed definitively using cell blocks. In seven (28%) poorly differentiated neoplasms, a more definitive diagnosis was given using cell blocks and immunocytochemistry. Ten (40%) cases of metastatic carcinomas were better subtyped with their probable primaries identified. Four (16%) cases comprising of well differentiated hepatocytes were classified either as well differentiated hepatocellular carcinoma or regenerative nodule.

Conclusion: We emphasize that cell blocks and cytosmears are best utilized when assessed together and cell blocks should be prepared at least in selected cases, to supplement the cytosmear diagnosis.

Keywords: Cell Block, FNAC, HCC, Immunocytochemistry, Liver

INTRODUCTION

FNAC is a safe, rapid and cost effective modality for diagnosis of liver lesions. Studies have shown that FNA performed by experienced personnel is more sensitive (81-93.5%) and specific technique for diagnosing malignancy than conventional core biopsy.[1,2] The smaller diameter of the needle facilitates more extensive and multiple sampling.[3]

Although, FNAC has many advantages but sometimes interpretation on cytosmears is difficult despite aspiration of adequate material. This is due to poor spreading of material, air drying artifact or presence of thick tissue fragments. Hence, residual material after preparation of cytosmears can be utilized in

preparation of cell blocks which enables retrieval of minute tissue fragments. [4,5]

The use of cell blocks has shown to increase the diagnostic accuracy and diagnostic yield.[6,7] Direct FNA smears and cell blocks complement each other[8] and both are required for efficient diagnosis; the former for assessment of morphology, and the latter for optimal immunocytochemistry results.[7]

The present study evaluates the role of thromboplastin-plasma cell blocks (TPCBs) prepared from liver SOL aspirates, in enhancing diagnostic yield.

MATERIALS AND METHODS

This was a descriptive study over a period of one year comprising of a total of 80 cases with liver SOL, clinico-radiologically suspicious for malignancy and referred to our department for FNAC under USG guidance. The study was carried out after approval from the review committee.

Patients radiologically presenting with liver SOL, were included in the study. Those cases in which the sample for cell block preparation could not be kept for fixation within one hour of collection and those patients having abnormal coagulation profile were excluded from the study. Preliminary details of every patient including name, age and gender were noted. The chief complains along with essential clinical details, radiological findings and serological data were noted on a structured pro forma for the study. An informed consent was taken from each patient prior to performing the FNA procedure. Ultrasound guided FNACs were performed using a 20 gauge lumbar puncture needle, fitted to a 20-ml disposable syringe. The skin entry site was sterilized and infiltrated with two percent lignocaine. One to two passes were made to get adequate aspirates. Direct air dried smears were prepared for routine Giemsa stain and few smears were immediately fixed in 95% Ethyl alcohol (15 minutes) for Hematoxylin and Eosin (H & E) stain. Diagnostic criteria described by Orell *et al*., 1992[9] were followed while analyzing cytosmears.

***Cell Block preparation*:** After preparation of the cytosmears, the remaining material from the aspirate was rinsed using normal saline and the material was taken in a conical tube. A dedicated needle pass was made for cell block, in case the patient consented. This material was used for cell block preparation by Thromboplastin-Plasma method. Needle rinse samples were centrifuged at 2500 rpm for 15 minutes. Following the centrifugation, supernatant was removed and discarded. The remaining sediment was mixed with four drops of pooled plasma that was brought to room temperature before use. Following this, two drops of thromboplastin (Neoplastine^{TM}) at room temperature were added and mixed. The tube containing the above mixture was agitated and then kept undisturbed for 15-20 seconds or until a clot was formed. If no clot formation could be appreciated, two more drops of thromboplastin were added until clot appeared. The formed clot was scooped out using a spatula, placed on a filter paper and kept in cassette. The tissue cassette was then fixed in ten percent neutral buffered formalin overnight and processed along with routine histopathological specimens. Cell blocks were made and tissue sections of three micron thickness were taken and stained with routine H & E for morphological evaluation.[10]

The prepared blocks were used for immunocytochemical staining and special stains were applied, whenever required. Cell blocks and cytosmears were evaluated by a two pathologists in an unblinded manner.

Immunocytochemistry: Polymer chain two-step indirect technique was used in accordance to the manufacturer's (Biocare Medical) recommendations. Peroxidase Block was done using three percent hydrogen peroxide in methanol for ten minutes. Heat induced epitope retrieval was done by decloaking chamber (Biocare Medical, Pacheco, California).

RESULTS

A male preponderance was noted in our study with a male to female ratio of 2.076. Out of total 80 cases, 54(67.5%) were male and 26 (32.5%) were female. Maximum cases were in the age group of 51-60 year (33.75%). Males were predominantly from the age group of 61-70 years (23.75%) with females lying more in the age group of 51-60 years (11.25%).

On cytosmears, out of total 80 cases, nine (11.25%) were diagnosed as moderately differentiated HCC. Number of diagnosed metastatic cases were 45 (56.25%) out of which 23 (28.75%) were adenocarcinoma (the commonest secondary). A diagnosis of "metastatic carcinoma" was made in ten (12.5%) cases but could not be further subtyped on smears alone. In seven

Volume 4, Issue 4; July-August 2021; Page No 26-37

(8.75%) cases, it was not possible to differentiate primary and secondary nature of malignancy owing to poor differentiation, a diagnosis of "Poorly differentiated neoplasm" was made. In four (5%) cases, differentiation between well differentiated HCC and regenerative nodule was difficult; hence a conclusive diagnosis on cytosmear was not possible. Table 1 shows broad categorization of cases diagnosed on cytosmears and on examining cytosmears in combination with cell blocks. Fifteen (18.75%) of our cases were non representative on cytosmears (Table 2).

Table 3 shows diagnoses made with the concomitant use of cell blocks and cytosmears and applying ICC on cell blocks as and when required. Eleven (13.75%) cases remained undiagnosed.

On the basis of clinico-radiological data, cytological and immunocytochemistry correlation, a primary site was predicted in 64/67 (95.5%) of malignant cases (Table 4). Maximum primaries were from gastrointestinal tract (GIT) accounting for 20 (29.9%) cases.

Table 5 shows cases having discordant diagnoses on cytosmears and cell blocks.

Table 1: Broad categorization of results on cytosmears and cell blocks (n=80).

	Cytosmear	Cytosmear + Cell block
Metastasis (to liver)	45	52
Hepatocellular carcinoma	09	15
Poorly differentiated neoplasm	07	00
Benign	00	02
Inadequate	15	11
Indeterminate	04	00
Total	80	80

Table 2: Distribution of inadequate aspirations on cytosmears (n=15).

Type	No.	Percentage
Scant cellular	04	26.7
Haemorrhagic aspirate	08	53.3
Poorly spread/stained	03	20

Table 3: Distribution of diagnoses made on combined examination of cytosmears and cell blocks.

Cytosmear + cell block diagnosis	Number of cases	Percentage
Metastatic adenocarcinoma	31	38.75
Metastatic small cell carcinoma	10	12.5
Moderately differentiated HCC*	9	11.25
Metastatic squamous cell carcinoma	3	3.75
Poorly differentiated HCC*	4	5
Regenerative nodule	2	2.5
Well differentiated HCC*	2	2.5
Metastatic renal cell carcinoma	1	1.25
Metastatic cholangiocarcinoma	3	3.75
Metastatic spindle cell sarcoma	1	1.25
Metastatic melanoma	2	2.5
Metastatic transitional cell carcinoma	1	1.25
Inadequate	11	13.75
Total	80	100

*HCC= Hepatocellular carcinoma

Volume 4, Issue 4; July-August 2021; Page No 26-37

Table 4: Distribution of primary site of malignant lesion (n= 67)

Primary site	Number	%
Gastrointestinal tract	20	29.9
Liver	15	22.4
Lung	10	14.9
Breast	5	7.5
Oral	3	4.5
Gall bladder	3	4.5
Ovary	2	3
Thyroid	2	3
Skin	1	1.5
Urinary bladder	1	1.5
Kidney	1	1.5
Orbit	1	1.5
Unknown	3	4.5
Total	67	100

Table 5: Cell Block diagnosis in discordant cases

S.no.	Diagnosis on cytosmear	Immunocytochemistry/Special stain (on cell block)	Diagnosis with cell block	Number of cases
1	Inadequate	MOC31+, CK7+, CK20+	Metastatic adenocarcinoma (GI)	1
2	Inadequate	Melan-A+, S100+	Metastatic melanoma (forearm skin)	1
3	Inadequate	MOC31+, PAX-8+, ER+	Metastatic adenocarcinoma (ovary)	1
4	Inadequate	Not applied	Metastatic renal cell carcinoma	1
5	Poorly differentiated neoplasm	Glypican 3+ , MOC31-	Poorly differentiated HCC	4
6	Poorly differentiated neoplasm	Glypican 3- , CDX-2+, CK7-, CK20+	Metastatic adenocarcinoma (GI)	2
7	Poorly differentiated neoplasm	Glypican 3- , CDX-2-, CK7-, CK20+	Metastatic adenocarcinoma (GI)	1
8	Metastatic carcinoma	TTF-1+, synaptophysin+, CD56+, P40-	Metastatic small cell carcinoma (lung)	5
9	Metastatic carcinoma	CK7+, CK20+, CDX-2-	Metastatic adenocarcinoma (GI)	1
10	Metastatic carcinoma	CK7+, CK20+, CDX-2+	Metastatic adenocarcinoma (GI)	1
11	Metastatic carcinoma	CK7-, CK20+, CDX-2+	Metastatic adenocarcinoma (GI)	1

Volume 4, Issue 4; July-August 2021; Page No 26-37

S.no.	Diagnosis on cytosmear	Immunocytochemistry/Special stain (on cell block)	Diagnosis with cell block	Number of cases
12	Metastatic carcinoma	p63+, uroplakin III+, CK20+, CK7-	Metastatic transitional cell carcinoma (Ureter)	1
13	Metastatic carcinoma	p63+, CK5/6+	Metastatic squamous cell carcinoma (Tongue)	1
14	Indeterminate	Gomori's reticulin stain	Well differentiated HCC	2
15	Indeterminate	Gomori's reticulin stain	Regenerative nodule	2

DISCUSSION

Differentiation of a liver primary from metastasis may pose a diagnostic dilemma on cytosmear examination such that the interobserver reproducibility maybe a challenge.

Preparation of good quality cell blocks in such situation can prevent the need of a core biopsy which is comparatively more invasive and expensive. [11,12]

Various methods for preparation of cell blocks have been described in literature. A valid comparison of the efficacy of different methods of cell block preparation is very difficult due to lack of uniform methodology and vast differences in technical details.

TP-CB technique is cost effective, simple, reproducible and provides improved cytomorphological features.[13] It is also suitable for performing immunocytochemical studies as antigenic epitopes are not exposed to alcoholic fixatives and hence, are better preserved.[14] Using TP-CB technique, we were able to prepare cell blocks with 80% success rate while failed attempts were mostly due to disintegration of the pellet during processing.

In our experience, cytosmears with cellular overlapping, scant cellularity, obscuring background and lack of proper tissue architecture posed a diagnostic problem (Table 2). Also, difficulties arose in classifying poorly differentiated neoplasms. Well differentiated HCC and regenerative nodule were also difficult to differentiate on cytosmears alone. Preparation of TP-CB helped us immensely to overcome these challenges. Privileged with cell blocks, we could render more definitive diagnoses and better subtype metastatic carcinoma.

In our study, 77.6% of all malignant cases were metastatic in nature, mostly accounting from GIT (29.9%). Tao *et al.*[15], in their series of 1383 cases of FNAC of liver, reported 75% metastatic neoplasms. Barbhuiya *et al.*[16], in their study of 400 consecutive aspirations reported 74.9% metastatic neoplasms, most common of which were metastatic adenocarcinoma from GIT accounting for 44.2%.

In four (5%) cases included in our study, diagnosis was made solely using cell blocks owing to inadequate diagnostic material on cytosmears. Reason for inadequate cellular yield on cytosmears might be the minute bits of diagnostic material getting entrapped in the hub of needle with blood clot. The pressure of a needle rinse probably drives these blood clot stuck tissue fragments in the cell block preparation, thereby improving the diagnostic material. On applying ICC panel based on cytomorphology and clinico-radiological data, two of these cases were diagnosed as metastatic adenocarcinoma and one as metastatic melanoma. In one of the two adenocarcinomas, we observed diffuse nuclear staining for PAX-8 and ER [Figure 1], confirming a primary from a mullerian organ. In the other case, cytoplasmic positivity for MOC31, CK20 and CK7 confirmed adenocarcinoma metastases from primary in jejunum which was detected in radiology. Melanin pigment can be confused with other normal pigments in liver like lipofuscin. Hence, confirmation was done after observing diffuse cytoplasmic and nuclear staining for S-100 and diffuse cytoplasmic staining for Melan-A [Figure 2]. We also applied Fontana-Masson stain for melanin which further confirmed the diagnosis. In one of these four cases, patient was clinically suspected of renal cell carcinoma (RCC) with metastasis in liver. FNAC was done from both sites but cytosmears from

liver SOL were non diagnostic while a diagnosis of RCC was made on cytosmears from renal mass. The sections from cell block of liver SOL aspirate revealed clusters of malignant cells which matched the cytomorphology of cells on cytosmears from renal mass. Hence, a diagnosis of metastatic RCC was made after examining H & E slide from cell block [Table 5].

Seven (8.75%) SOLs diagnosed as "Poorly differentiated neoplasm" due to poor cellular differentiation were finally concluded after applying ICC on cell blocks. Four (5%) of these cases were diagnosed as poorly differentiated HCC. In all these cases, there was diffuse cytoplasmic and membranous staining for Glypican-3 and cells stained negative for MOC-31 [Figure 3]. Remaining three (3.75%) of these cases were diagnosed as metastatic adenocarcinoma, two of them showing nuclear positivity for CDX-2 and all of them showing diffuse cytoplasmic positivity for CK20, negative CK7 [Figure 4]. Clinico-radiological follow-up revealed colo-rectal primaries in all 3 cases [Table 5].

One of the ten (12.5%) metastatic carcinoma cases was subtyped as metastatic squamous cell carcinoma which showed diffuse nuclear staining for p63 and CK 5/6[Figure 5]. In another case, CT abdomen showed a wall thickening in ureter, so we suspected liver metastasis of urothelial carcinoma. On applying ICC, there was focal nuclear positivity for p63 and focal cytoplasmic and membranous positivity for uroplakin-III. Also, CK20 showed diffuse cytoplasmic positivity, CK7 was negative. Hence, a diagnosis of metastatic transitional cell carcinoma was made on cell block [Figure 6]. Out of the remaining eight cases, five were subtyped as metastatic small cell carcinoma. The CT and USG findings in these cases showed a mass in lung and also considering the cytomorphology, we applied a panel of TTF-1, synaptophysin, CD56, P40. We observed diffuse, strong nuclear staining for TTF-1, diffuse cytoplasmic staining for synaptophysin and CD56 in all five cases. Remaining three cases were diagnosed as metastatic adenocarcinoma [Table 5].

In four (5%) cases, it was difficult to differentiate between regenerative nodule and well differentiated HCC on cytosmears. In these cases, we applied Gomori's stain for reticular fibers. In two of these cases, there were four to five cell thick trabeculae and attenuated or absent reticulin around individual hepatocytes, so a diagnosis of well differentiated HCC was made. In remaining two cases, not more than two cell thick trabeculae were seen and there was homogenous staining around individual hepatocytes. Hence, a diagnosis of regenerative nodule arising in a background of cirrhosis was rendered.

In present study, serum AFP levels were available in 11 out of 15 HCC cases and ten (90.9%) of these 11 cases had elevated AFP levels. HBsAg status was available in ten out of 15 HCC cases and was reactive in four (40%) cases.

With the concomitant use of cell blocks and cytosmears, a confirmatory diagnosis was offered in 86.25% cases of which five percent cases did not yield any diagnostic material on smears and a cell block preparation yielded a definitive diagnosis. The use of ancillary techniques like histochemistry and ICC on cell block preparations proved to be useful adjuncts in establishing a confirmatory diagnosis.

Thromboplastin-Plasma cell blocks prepared from liver SOL aspirates gives improved architecture, good cellularity and less obscuring background. Cell blocks also allow the use of ICC which helps in classifying poorly differentiated malignancy, further subtyping of metastatic disease and confirming the diagnoses made on cytosmears. These advantages acquired from cell blocks provide additional yield in diagnosis of malignancy and also provision for confirmation of probable primary sites, in case of metastatic disease. Preparation of cell block with Thromboplastin-Plasma method is cost effective but demands skill. On the other hand, conventional cytosmears are easy and quick to prepare and have a reasonably good sensitivity in diagnosing malignancy.

We emphasize that cell blocks and cytosmears are best utilized when assessed together and cell blocks should be prepared at least in difficult cases if not all in order to aid to the cytosmear diagnosis. TPCBs, being prepared from needle rinse, may yield more diagnostic material thereby reducing the number of non-diagnostic results.

ACKNOWLEDGEMENT: We acknowledge the invaluable contribution of technical staff from department of immunohistochemistry, cytology and histopathology.

REFERENCES

1. Sbolli G, Fornari F, Civardi G, Di Stasi M, Cavanna L, Buscarini E, *et al*. Role of ultrasound guided fine needle aspiration biopsy in the diagnosis of hepatocellular carcinoma. Gut 1990;31:1303-5.
2. Nggada H, Ahidjo A, Ajayi N, Mustapha S, Pindiga U, Tahir A, *et al*. Correlation between ultrasound findings and ultrasound-guided fine needle aspiration cytology in the diagnosis of hepatic lesions: a Nigeriian tertiary hospital experience. Int J Gastroenterd 2007;5:1.
3. Balani S, Malik R, Malik R, Kapoor N. Cytomorphological variables of hepatic malignancies in fine needle aspiration smears with special reference to grading of hepatocellular carcinoma. J Cytol 2013;30:116.
4. Fischer AH, Zhao C, Li QK, Gustafson KS, Eltoum IE, Tambouret R, *et al*. The cytologic criteria of malignancy. J Cell Biochem 2010;110:795-811.
5. Kulkarni M, Prabhudesai N, Desai S, Borges A. Scrape cell-block technique for fine needle aspiration cytology smears. Cytopathology 2000;11:179-84.
6. Castro-Villabón D, Avello Y, Ruiz N, Rodríguez-Urrego PA. Implementation of routine thromboplastin-plasma cell block technique in the evaluation of non-gynecologic specimens: A methodologic comparison with conventional cytology. Journal of Microscopy and Ultrastructure 2014;2:177-81.
7. Khan S, Omar T, Michelow P. Effectiveness of the cell block technique in diagnostic cytopathology. J Cytol 2012;29:177.
8. Akalin A, Lu D, Woda B, Moss L, Fischer A. Rapid cell blocks improve accuracy of breast FNAs beyond that provided by conventional cell blocks regardless of immediate adequacy evaluation. Diagn Cytopathol 2008;36:523-9.
9. Boer Bd. Liver and spleen. In: Orell SR, Sterrett GF, editors. Orell & Sterrett's Fine needle aspiration cytology. 5th ed. China: Churchill Livingstone; 2012. pp. 271-96.
10. Kulkarni MB, Desai SB, Ajit D, Chinoy R. Utility of the thromboplastin-plasma cell-block technique for fine-needle aspiration and serous effusions. Diagn Cytopathol 2009;37:86-90.
11. Sheefa H, Lata J, Basharat M, Rumana M, Veena M. Utility of FNAC in Conjunction with Cell Block for Diagnosing Space-Occupying Lesion (SOL) of Liver with Emphasis on Differentiating Hepatocellular Carcinoma from Metastatic SOL: Analysis of 61 Cases. Oman Med J 2016;31:135-41.
12. Khurana U, Handa U, Mohan H, Sachdev A. Evaluation of aspiration cytology of the liver space occupying lesions by simultaneous examination of smears and cell blocks. Diagn Cytopathol 2009;37:557-63.
13. Shukla P, Kaur S, Gulwani H. Diagnostic utility of Plasma Thromboplastin cell block preparation in cytological evaluation of serous effusions. Int J Biomed Res 2015;6:890-6.
14. Balassanian R, Wool GD, Ono JC, Olejnik-Nave J, Mah MM, Sweeney BJ, *et al*. A superior method for cell block preparation for fine-needle aspiration biopsies. Cancer Cytopathol 2016;124:508-18.
15. Tao L, Donat E, Ho C, McLoughlin M. Percutaneous fine-needle aspiration biopsy of the liver. Cytodiagnosis of hepatic cancer. Acta Cytol 1979;23:287-91.
16. Barbhuiya M, Bhunia S, Kakkar M, Shrivastava B, Tiwari PK, Gupta S. Fine needle aspiration cytology of lesions of liver and gallbladder: An analysis of 400 consecutive aspirations. J Cytol 2014;31:20.
17. Rasania A, Pandey C, Joshi N. Evaluation of FNAC in diagnosis of hepatic lesion. J Cytol 2007;24:51.

Volume 4, Issue 4; July-August 2021; Page No 26-37

18. Ali S, Jayabackthan L, Rahim S, Sharel M, Prasad K, Hegdekatte N. Role of fine needle aspiration cytology in the diagnosis of hepatic lesions. Muller J Med Sci Res 2015;6:125-8.

19. Sukumaran R, Nayak N, Katoor J, Nair S, KR A, Venugopal M. Cytomorphological Spectrum of Ultrasound Guided Fine Needle Aspiration Cytology of Liver Lesions, and the Role of Cell Block Preparation and Immunohistochemistry in the Diagnosis: An Analysis of 638 Consecutive Aspirations. JMSCR 2018;06:875-81.

FIGURES

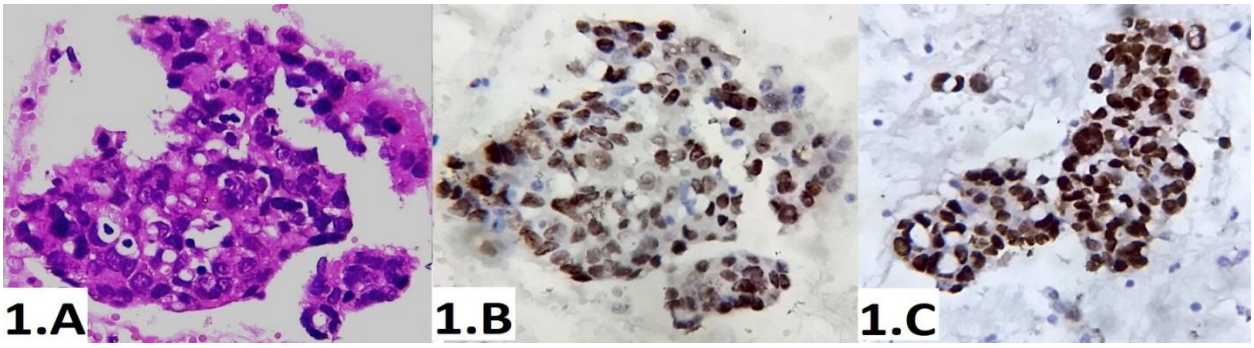

Figure 1: Metastatic adenocarcinoma from ovary. *A*, Tumor fragment showing atypical glandular cells (H & E, X400, CB). *B*, PAX-8 immunostaining showing diffuse nuclear staining (X400). *C*, ER immunostaining showing diffuse nuclear staining (X400).

Volume 4, Issue 4; July-August 2021; Page No 26-37

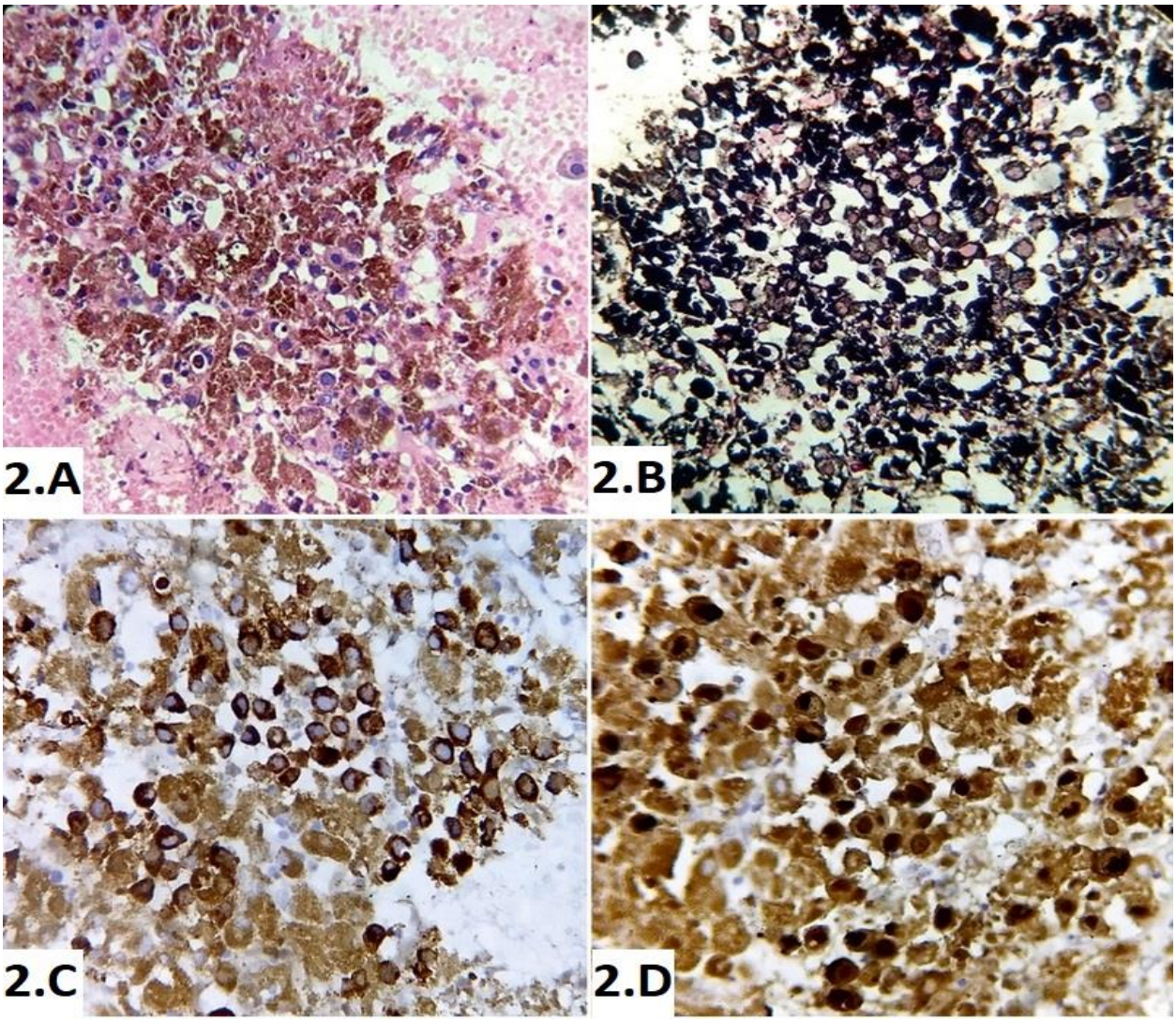

Figure 2: Metastatic melanoma from forearm skin. *A*, Pigmented cells in clusters and dispersed (H & E, X400, CB). *B*, Fontana Masson stain showing pigment (X400). *C*, Melan-A immunostaining showing cytoplasmic staining.in melanocytes (X400). *D*, S-100 showing cytoplasmic and nuclear staining (X400).

Volume 4, Issue 4; July-August 2021; Page No 26-37

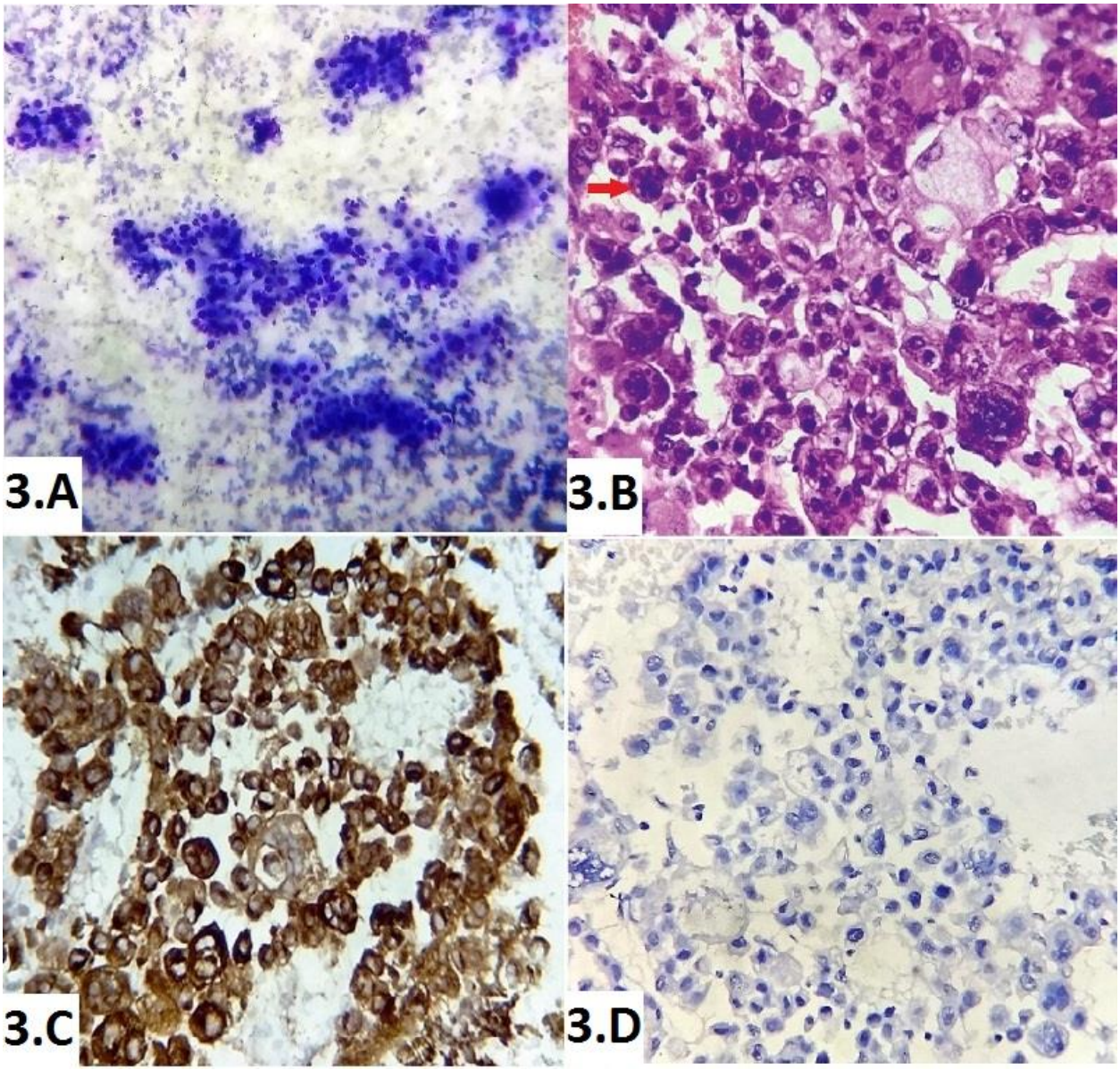

Figure 3: Poorly differentiated hepatocellular carcinoma. *A*, Cytosmear revealing poorly differentiated cells (X100, MGG). *B*, Atypical cells with high N/C ratio and numerous mitotic figures (arrow head) (H & E, X400, CB) *C*, Diffuse cytoplasmic and membranous Glypican-3 immunostaining (X400). *D*, Negative MOC-31 (X400).

Volume 4, Issue 4; July-August 2021; Page No 26-37

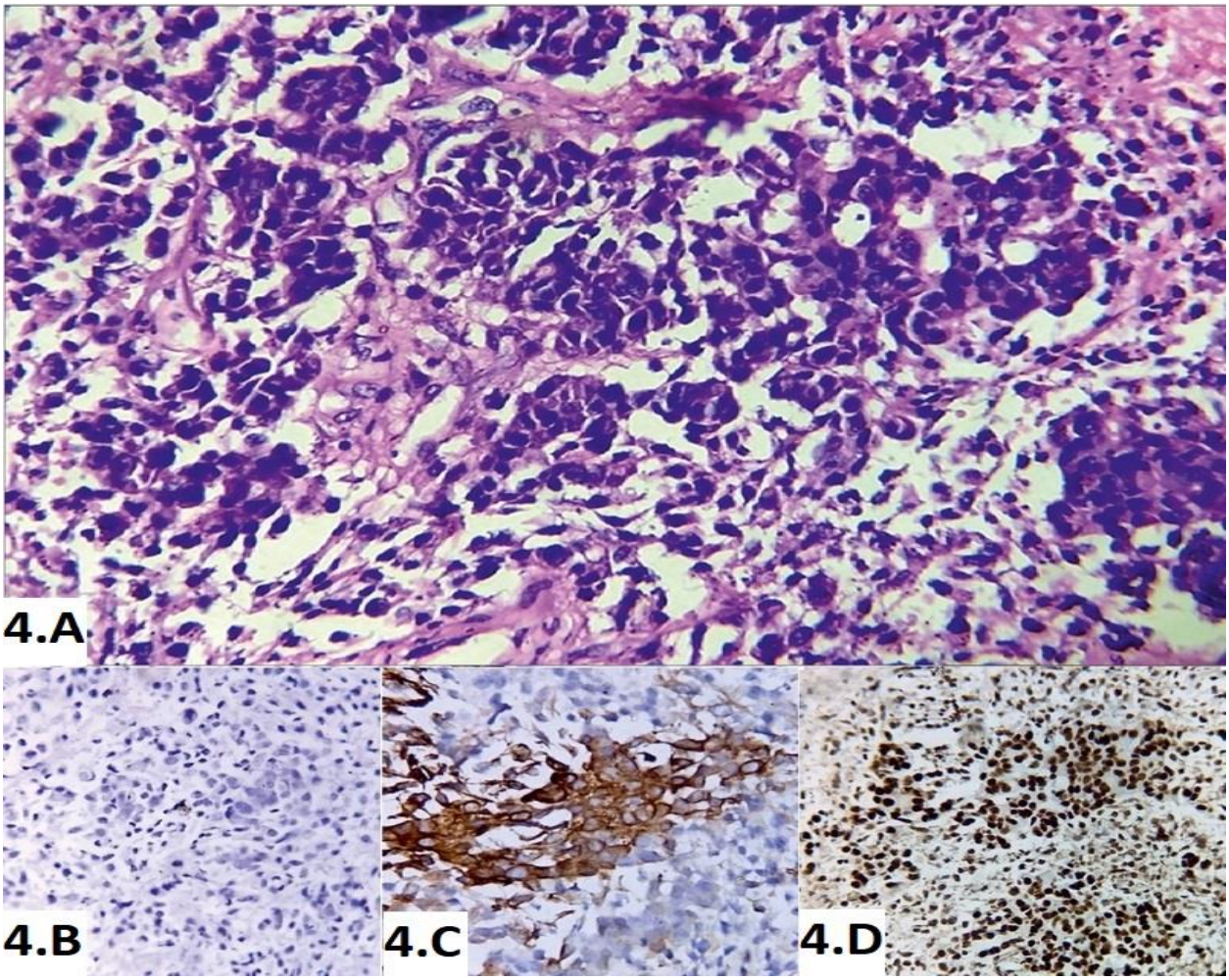

Figure 4: Metastatic adenocarcinoma from colon. *A*, Columnar cells arranged in glandular formation (H & E, X400, CB). *B*, Negative CK7 immunostaining (X400). *C*, CK20 immunostaining showing focal cytoplasmic staining (X400). *D*, CDX2 immunostaining showing diffuse, strong nuclear staining (X400).

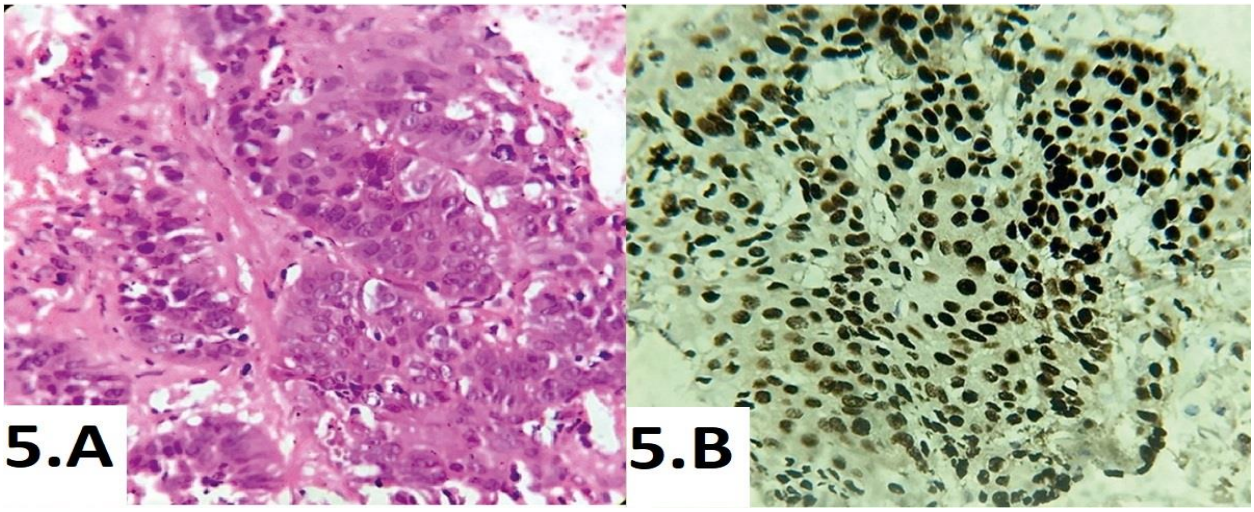

Figure 5: Metastatic squamous cell carcinoma from tongue: A, Sheets of malignant epithelial cells (H & E, X400, CB). *B*, Diffuse and strong p63 immunostaining (X400).

Volume 4, Issue 4; July-August 2021; Page No 26-37

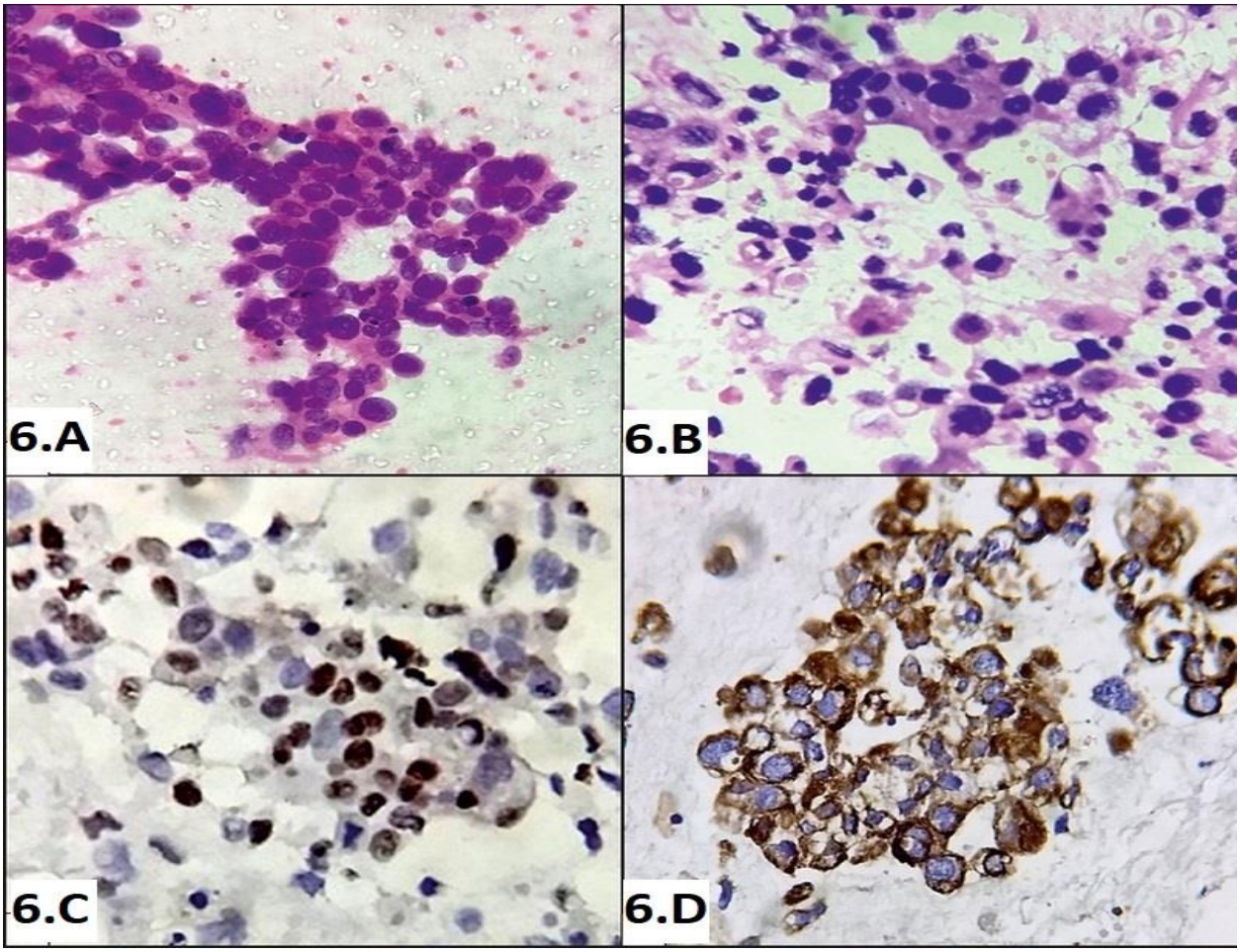

Figure 6: Metastatic urothelial carcinoma. *A* and *B*, showing isolated cells and small clusters moderate amount of cytoplasm, dense hyperchromatic chromatin, and irregular nuclei. (H & E, X400, *A*- CS, *B*- CB). *C*, Immunostaining for p63 showing nuclear staining (X400). *D*, Immunostaining with CK20 showing diffuse cytoplasmic staining (X400).

Volume 4, Issue 4; July-August 2021; Page No 26-37