(International Print/Online Journal)

SJIF IMPACT FACTOR: 5.565
PUBMED-National Library of Medicine ID-101739732

ISSN (Print): 2209-2870
ISSN (Online): 2209-2862

International Journal of Medical Science and Current Research (IJMSCR)
Available online at: www.ijmscr.com
Volume 4, Issue 4, Page No: 266-270
July-August 2021

IJMSCR

A Case of Tuberculous Arthritis -An Uncommon Presentation of a Common Disease

Dr. Kedareshwar Narvencar[1], *Dr. Gajanan Kamat[2], Dr. Nidhi Prabhu[3]
[1-]Associate Professor, [2-]Senior Resident, [3-]Junior Resident
Department of General Medicine, Goa Medical College, Goa, India,

***Corresponding Author:**
Dr. Gajanan Kamat
Senior Resident, Department of General Medicine, Goa Medical College, Goa, India

Type of Publication: Case Report
Conflicts of Interest: Nil

Abstract

Tuberculosis is a common disease in India, which primarily presents as a pulmonary involvement. Extrapulmonary tuberculosis comprises 1-3% of cases of tuberculosis. Pulmonary involvement has been found in only one-third of musculoskeletal tuberculosis cases leading to delay in diagnosis. The time for delayed diagnosis is approximately between 2 months and 10 years. Primary tuberculous arthritis without pulmonary symptoms is a rare presentation and physicians need to be aware of this condition for timely diagnosis and treatment. In our case, a young patient had presented with symmetrical polyarthritis involving bilateral ankles and wrists which resolved completely after starting her on anti-tuberculous therapy.

Keywords: Primary Tuberculous arthritis, polyarthritis

INTRODUCTION

Tuberculosis is a chronic infection primarily affecting the lung parenchyma. Tuberculous involvement of joints is relatively rare, comprising about 10-19% of total extrapulmonary cases.[1] Skeletal system involvement mainly manifests as monoarthritis, but 10% of the patients may present as polyarthritis.[2] We present a case of a young girl presenting with symmetric tuberculous polyarthritis which was mistaken initially as rheumatoid arthritis.

Case presentation

An 18-year-old college student presented to Medicine outpatient department (OPD) of our institution with complains of progressive worsening of pain and swelling of both wrists since 4 months leading to difficulty in writing. The arthritis had progressed to involve both ankle joints over last one month. There was no history of involvement of axial joints. Patient denied history of oral ulcers, malar rash, photosensitivity or excessive hair loss. Patient did not have any sicca symptoms or Raynaud's phenomenon. Patient had been on multiple NSAIDS prior to visit to our institution but without any relief.

On examination, patient was well built young female. Patient's blood pressure was normal and peripheral pulses were well felt. Patient had no lymphadenopathy, or clubbing.

There was synovitis of both wrists and ankles associated with tenderness. There was no involvement of small joints of hand.

Figure 1: Image of both wrists of patient showing synovitis

Patient's ESR was 56 mm/hr, CRP was positive. Renal, liver, thyroid function was all normal. Autoimmune work up was all negative (RA factor, anti CCP, antinuclear antibody (ANA), anti-ds DNA, anti-Smith antibody, SSA(antiRo),SSB(anti La), anti-histone antibody, HLA B27, p and c ANCA). HIV Elisa and VDRL was non-reactive. X ray of both wrists and ankles was normal.

Figure 2: X ray of both wrists

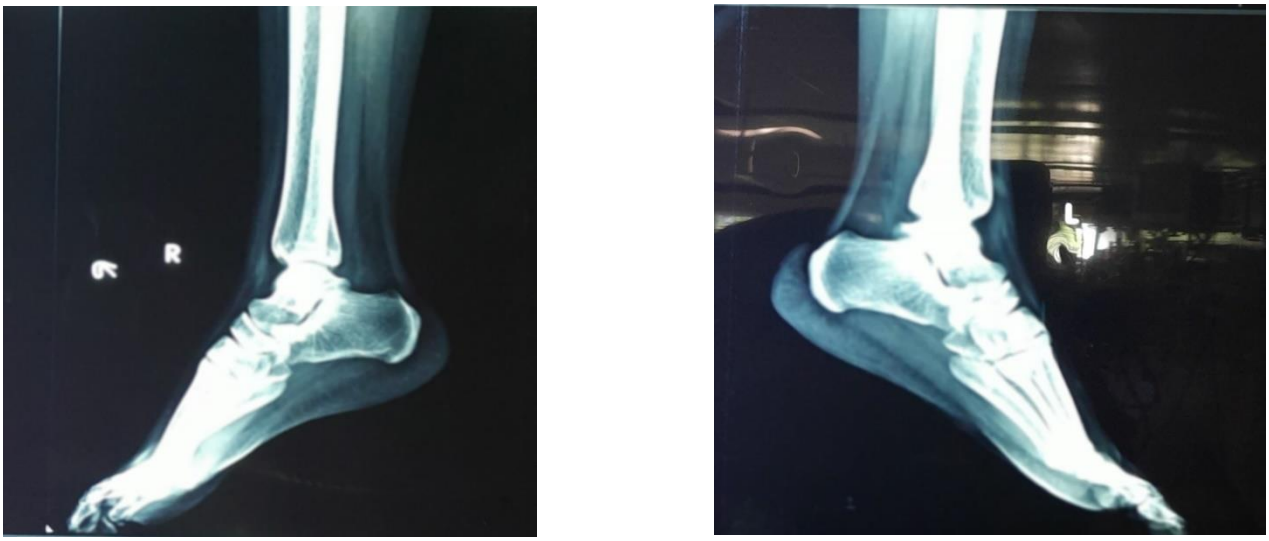

Figure 3: X ray of both ankles

Volume 4, Issue 4; July-August 2021; Page No 266-270

As there was no clear indication of autoimmune involvement, we subjected patient to tuberculin test which was strongly positive. Also, Quantiferon gold test on peripheral blood was positive.

In view of above findings, patient was subjected to MRI of wrists which showed erosion and thinning of lunate.

Figure 4: T2 weighted MRI of left wrist showing erosion and thinning of lunate bone.

Patient was diagnosed as a case of tuberculous arthritis based on MRI findings, positive tuberculin test and positive quantiferon gold test. Synovial biopsy was not done as the patient refused consent for the same in view of it being an invasive procedure. Patient was started on weight-based category 1 DOTS (HRZE) along with tab pyridoxine. Patient's symptoms started improving after starting her on Anti tuberculous therapy and within 2 months swelling and pain resolved. Patient is under regular follow up in our OPD.

Discussion

While tuberculosis is a common infectious disease of the tropics, musculoskeletal tuberculosis is relatively rare. While joint involvement may be secondary to immunological response (reactive arthritis), direct invasion of joint by tuberculous bacilli is not common. The present case therefore assumes importance. Additionally, diagnosis is usually delayed, owing to nonspecific symptoms.[2] In fact, in most cases the diagnosis is usually delayed for upto 2 months to 10 years as noted in a study by Triplett D et. al..[3] Most common site of involvement is vertebra. Symmetrical peripheral polyarthritis involving bilateral wrist and ankles as seen in our patient is a rare presentation.

The more common joint involvement in tuberculosis is due to reactive arthritis or Poncet's disease. It is a nondestructive polyarthritis in a patient with active tuberculosis where no mycobacterial invasion is found in affected bones.[4] Mehrotra V et. al.[5] had presented a case of pulmonary tuberculosis with Poncet's disease without any radiological erosions. In our patient, there was evidence of bony involvement. Hence our case represents true tuberculous arthritis.

Though rare, tuberculous arthritis has been earlier reported. Mussa MA et. al.[6] had reported a case of tuberculous monoarthritis affecting wrist in a young patient while Rando M et. al.[7] had reported a case of tuberculous monoarthritis of ankle joint. Our case involved bilateral wrists and ankle in a symmetric fashion and was diagnosed at a much early stage with minimal joint erosions.

Volume 4, Issue 4; July-August 2021; Page No 266-270

Symptoms of tuberculous arthritis are similar to any other arthritis[8,9] thus making the diagnosis difficult. In our patient, local manifestations were present however there were no systemic features.

A high index of suspicion is needed for the diagnosis. The confirmation of tuberculous infection is established by detection of tuberculous bacilli[10,11] by positive tuberculin test and quantiferon gold assay. Plain X rays may be normal in early disease however in advanced cases, it shows Phemister's triad (juxta-articular osteopenia/osteoporosis, peripheral osseous erosions, gradual narrowing of joint space.).[12]

MRI helps in early detection of soft tissue involvement, tendon injury and cartilage damage and joint effusion, rice body formation and synovial thickening.[13] Tuberculous arthritis can be differentiated from other types of arthritis on T2WI by the low-density lesions, low density synovium with central erosion, and surrounding abscess.[14]

The gold standard for diagnosing TB arthritis is synovial biopsy, with positive results in 80% of cases.[15] Typical findings of TB arthritis include granulomas, lymphocytes, and giant cells with caseation.

The mainstay of treatment includes antituberculous polytherapy for 12-18 months. Surgical interventions (synovectomy and debridement) are required when the patient is not responding after 4-5 months of antituberculous polytherapy.[16]

Our patient was diagnosed at an early stage without any significant damage to bone or cartilage and responded well to antituberculous therapy.

Conclusion

The present case assumes importance because of its rarity. The presentation of symmetric polyarthritis in a young female without any pulmonary involvement usually leads to a provisional diagnosis of autoimmune arthritis. However absence of any other autoimmune features and negative autoimmune lab profile made us look for alternative diagnosis. In a tropical country such as ours, tuberculous infection should always be considered as a differential diagnosis, especially when alternative diagnosis is not very clear.

References

1. Latief W. and Asril E, Tuberculosis of the wrist mimicking rheumatoid arthritis – A rare case, Int J Surg Case Rep. 2019; 63: 13–18.
2. Muangchan C. and Nilganuwong S, "The study of clinical manifestation of osteoarticular tuberculosis in Siriraj Hospital, Thailand," Journal of the Medical Association of Thailand, vol. 92, Supplement 2, pp. 101–109, 2009.
3. Triplett D., Stewart E., Mathew S., Horne B.R., and Prakash V., "Delayed diagnosis of tuberculous arthritis of the knee in an air force service member: case report and review of the literature," Military Medicine, vol. 181, no. 3, pp. e306–e309, 2016.
4. Chakraborty P., Ray S., Selvan C., Bhattacharjee R., and Mandal S., Poncet's disease: An unusual presentation of tuberculosis in a diabetic lady, World J Clin Cases, vol.3(4); 2015 Apr 16
5. Mehrotra V, Garg K, Devi P, Chauhan S A commonly missed diagnosis: Poncet's disease, J Indian Acad Oral Med Radiol 2019;31:176-80
6. Mussa MA, O'Connor EF, Waterston S, Taylor M, Iwuagwu F. Isolated tuberculosis of the wrist: A rare case of extrapulmonary tuberculosis. International Journal of Case Reports and Images 2013; 4(10): 541-545
7. Rando M, Matteis G, Gessi M, Bartoli M, Galli M, Gambassi G, Tuberculous Arthritis of the Ankle, Eur J Case Rep Intern Med. 2018; 5(6): 000870.
8. Erdem H, Baylan O, Simsek I, Dinc A, Pay S, Kocaoglu M. Delayed diagnosis of tuberculous arthritis. Jpn J Infect Dis. 2005;58:373–5.
9. Sagoo RS, Lakdawala A, Subbu R. Tuberculosis of the elbow joint. JRSM Short Rep. 2011;2:17
10. KY Loh, Role of Mantoux Test in the Diagnosis of Tuberculosis, Malays Fam Physician. 2011; 6(2-3): 85–86.
11. Ahmed Anwar, AL-Jahdali Hamdan, Baharoon Salim, Ali Yosra, Mohamed Hani, and AL-Harbi Abdullahh, Diagnostic Utility of

QuantiFERON-TB Gold (QFT-G) in Active Pulmonary Tuberculosis, J Glob Infect Dis. 2015 Jul-Sep; 7(3): 108–112

12. Arghya Chattopadhyay,Prof Aman Sharma, Prof Kirti Gupta,Prof sanjay Jain, The Phemister Triad, The Lancet volume 391, Issue 10135,E20,May 26,2018
13. Luke W, Gunathilake M, Munidasa D, Munidasa D, De Silva ST. Tuberculous monoarthritis of the wrist in a patient with systemic lupus erythematosus: a case report. BMC Res Notes. 2017;10(1):343.
14. Hsu CY, Lu HC, Shih TT. Tuberculous infection of the wrist: MRI features. AJR Am J Roentgenol. 2004;183(3):623 –8
15. S. Arthanari, S. Yusuf, and M. Nisar, "Tuberculosis of the knee complicating seronegative arthritis," The Journal of Rheumatology, vol. 35, no. 6, pp. 1227-1228, 2008.
16. WHO,"Guidelines for treatment of drug-susceptible tuberculosis and patient care (2017 update)," April 2017

Volume 4, Issue 4; July-August 2021; Page No 266-270