(International Print/Online Journal)

SJIF IMPACT FACTOR: 5.565
PUBMED-National Library of Medicine ID-101739732

ISSN (Print): 2209-2870
ISSN (Online): 2209-2862

International Journal of Medical Science and Current Research (IJMSCR)
Available online at: www.ijmscr.com
Volume 4, Issue 4, Page No: 104-109
July-August 2021

IJMSCR

Extramedullary Plasmacytoma - A Case Report

[1]Prof K. E. Govindarajulu M.D, [2]Prof R. Poongundran M.D, [3]Dr.R. Prasanna

[1]Professor, Department of General medicine, Govt Kilpauk medical college and hospital, Chennai
[2]Assistant Professor, Department of General Medicine, Govt Kilpauk medical college and hospital, Chennai
[3]Post graduate, Department of General Medicine, Govt Kilpauk medical college and hospital, Chennai

***Corresponding Author:**
Dr. R. Prasanna
MBBS, Junior Resident, Dept of General medicine, Govt Kilpauk medical college and hospital, Chennai

Type of Publication: Case Report
Conflicts of Interest: Nil

Abstract

BACKGROUND: A 36 years old female presented with bilateral progressive painless loss of vision in left eye followed by right eye for duration of one year. On evaluation, we found a very rare presentation of Extramedullary Plasmacytoma in right sphenoid sinus.

INVESTIGATIONS: MRI BRAIN revealed T1 isointense T2 hypointense lesion on contrast administration noted involving right chamber of sphenoid sinus and erodes root and lateral wall, greater and lesser wing of sphenoid and encases the cavernous segment of bilateral ICA and left infratemporal fossa and extend upto left ramus of mandible. Anteriorly involves optic chiasma and bilateral optic nerves and intraocular muscles. Impression was ?Lymphoma or ?Neurosarcoidosis. Transnasal endoscopic BIOPSY OF SPHENOID showed dense fibro collagenous lesion with infiltration by lymphocytes and histiocytes. Some foci have scattered plasmacytoid cells.? Plasmacytoma? Histiocytosis and advised for IHC CD138, Kappa, lambda. IHC for CD138, Kappa, lambda was positive.

CONCLUSION: Extramedullary Plasmacytoma (EMP) mostly occur in the respiratory tract, especially the submucosa of the nasal cavity, paranasal sinuses, nasopharynx, oropharynx, and larynx. Common median age group of EMP is 55 to 60 years and Males are more common than females (M:F ratio 3:1). In this case, rare presentation is age (< 40years) and sex (female)and site (right sphenoid sinus) without brain parenchyma involvement. It means that EMP more often spread through lymphatics.

Keywords: EMP- Extramedullary Plasmacytoma, Sphenoid sinus, Rarity of Age sex, Lymphatic spread.

INTRODUCTION

Extramedullary Plasmacytoma is a plasma cell tumor which involve the submucosal lymphoid tissue of the nasopharynx or paranasal sinuses. MP accounts for less than 4% of all plasma cell tumors. Here we discuss about one rare presentation of Extramedullary Plasmacytoma with age and sex.

CASE HISTORY AND PRESENTATION

A 36-year-old female brought presented with progressive painless loss of vision in both eyes for duration of one year. History of presenting illness, she developed diminished vision in Left eye which progressively worsened followed by right eye involvement leading to complete loss of vision in both eyes. No headache, No vomiting, No head injury, No weakness of limbs. Past history Ten years back, she had h/o left temporal headache for one year, then she developed jaw pain, difficult in opening the mouth. She was diagnosed as? Osteomyelitis of left mandible and left hemi mandibulectomy was done. Histopathology of Mandible specimen showed Massive osteolysis of body of mandible. Five years back, she had two episodes of new onset GTCS seizures and was started on antiepileptics. On

examination she was conscious oriented no pallor,no lymphadenopathy, not icteric and vitals were stale. CNS examination, Motor and sensory system were normal. No bowel and bladder disturbance. No cerebellar signs. No meningeal signs. Ocular examination Bilateral pupils size and shape normal, pupillary reflexes and extraocular movements were normal. Fundus examination revealed bilateral optic nerve atrophy with disc pallor. Then investigations were done. CT BRAIN showed soft tissue density lesion involving right sphenoid sinus extending into bilateral orbits through superior orbital fissure and erosions noted in bilateral greater and lesser wing of sphenoid and sellatursica and impression was possibility of Lymphoma. RI BRAIN revealed T1 isointense T 2 hypointense Lesion on contrast administration noted involving right Chamber of sphenoid sinus and erodes root and lateral wall, greater and lesser wing of sphenoid and encases the cavernous segment of bilateral ICA and erodes also left infratemporal fossa and extend upto left ramus of mandible. Anteriorly involves optic chiasma and bilateral optic nerves and intraocular muscles. Impression was? Lymphoma or? Neurosarcoidosis. Transnasal endoscopic BIOPSY OF SPHENOID showed dense fibro collagenous lesion with infiltration by lymphocytes and histiocytes. Some foci have scattered plasmacytoid cells.? Plasmacytoma? Histiocytosis and advised for IHC CD138, Kappa, lambda.IHC for CD138, Kappa, lambda was positive. Serum protein electrophoresis showed normal pattern. Bone marrow biopsy did not demonstrate Bone marrow involvement. Serum protein electrophoresis showed normal pattern. CT CHEST was normal study. Serum calcium 9mg/dl,serum ACE level was normal. ANA and ENA profile were negative. CRP and Rheumatoid factor negative, CSF analysis was normal. Finally, she was diagnosed as Extramedullary Plasmacytoma of sphenoid without bone plasma cell proliferation and without systemic features of myeloma like (bone pain /fracture, renal failure, hypercalcinemia, anaemia, clotting abnormalities, manifestations of hyper viscosity). Local radiation therapy is plan of treatment.

NAME : MRS. SUNITHA
PIN : AND20020017995
AGE/GENDER : 36 Year(s)/Female
REFERRED BY : Dr.CHIEF MINISTERS COMPREHENSIVE HEALTH INSURANCE SCHEME .
CLIENT NAME : CHIEF MINISTERS COMPREHENSIVE HEALTH INSURANCE SCHEME

SAMPLE NO : 022041888
COLLECTED ON : 19/09/2020 10:56 A
RECEIVED ON : 19/09/2020 10:56 A
REPORTED ON : 23/09/2020 01:56 PM
REPRINT DATE : 23/09/2020 01:56 PM

IMMUNOHISTOCHEMISTRY REPORT

LAB NO. : IH1026/2020
SPECIMEN : Received one paraffin block
STUDY : IMMUNOHISTOCHEMISTRY - kappa,lambda & cd138

MARKERS	RESULT	IMAGE
KAPPA	POSITIVE	
LAMBDA	POSITIVE	

Volume 4, Issue 4; July-August 2021; Page No 104-109

TAMILNADU MEDICAL SERVICE CORPORATION LIMITED
GOVT.ROYAPETTAH HOSPITAL, ROYAPETTAH -14

MRS. SUNITHA [36Y/F] DATE: 21.07.2020

Ref. By :CMCHIS

1.5T MRI – BRAIN WITH CONTRAST

Sequences:

T2W AXIAL T1 W SAGITTAL SWI AXIAL DWI, ADC MAPPING
T2 W FLAIR CORONAL 3 D TOF ANGIOGRAM Post contrast study

Brain:

T1 isointense T2 hypointense lesion which shows avid enhancement on contrast administration noted involving the right chamber of sphenoid sinus, eroding the roof, lateral walls of sphenoid sinus, greater and lesser wings of sphenoid bone and encases the cavernous segment of bilateral internal carotid arteries. The lesion also extends to the left infratemporal fossa and erodes the left ramus of mandible.
Superiorly the lesion erodes the sella tursica to involve the pituitary gland.
Posteriorly the lesion involves the clivus.
Anteriorly the lesion involves the optic chiasm, encases bilateral optic nerves and bilateral intraocular muscles.
Enhancing meningeal thickening noted.

The corona radiata and centrum semiovales are normal. No focus of demyelination is present.

The caudate and lentiform nuclei and the thalami are normal. The corpus callosum, the anterior and posterior commisures are normal.

The midbrain, pons and medulla are normal. The superior, middle and inferior cerebellar peduncles are normal.

The cerebellar vermis and the cerebellar hemispheric parenchyma reveal no abnormality.
Ventricles and cisterns appear normal. The internal auditory canals and their contents are normal.

3D TOF MR Angiography for circle of Willis:

No significant abnormality

Impression:

Avidly enhancing lesion involving right chamber of sphenoid sinus with above said extension.

- **The possible differential diagnosis are**
  1. **Lymphoma**
  2. **Neurosarcoidosis.**

--- suggested HPE correlation.

Dr. K. Gopinathan Professor
Dr. Bharathi selvam Assistant Professor
Dr. Janani Resident
Dr. Indumathi Resident

andersonDiagnostic Service

NAME	: MRS. SUNITHA	SAMPLE NO	: 022041888
PIN	: AND20020017995	COLLECTED ON	: 19/09/2020 10:56 AM
AGE/GENDER	: 36 Year(s)/Female	RECEIVED ON	: 19/09/2020 10:56 AM
REFERRED BY	: Dr.CHIEF MINISTERS COMPREHENSIVE HEALTH INSURANCE SCHEME .	REPORTED ON	: 23/09/2020 01:56 PM
CLIENT NAME	: CHIEF MINISTERS COMPREHENSIVE HEALTH INSURANCE SCHEME	REPRINT DATE	: 23/09/2020 01:56 PM

CD138 POSITIVE

IMPRESSION : --

Note: All immunohistochemistry markers have been evaluated in the context of appropriate positive and negative controls. A result is considered uninterruptable as a result of the type of fixative used (Non 10% neutral buffered formalin), time to fixation (> 1 hour), duration of fixation (< 6 hours or > 72 hours), strong decalcification or inappropriate staining of normal internal or external assay controls. An alternative sample for retesting is then usually recommended.

-- End of Report --

Volume 4, Issue 4; July-August 2021; Page No 104-109

DEPARTMENT OF PATHOLOGY, GOVT. ROYAPETTAH HOSPITAL,
CHENNAI - 14

HISTOPATHOLOGY REPORT

Name : Sunith Age : [illegible] Sex: M/F Hosp. No: 156866

HPE No. HE-580/20 Unit: ENT

Clinical Diagnosis : ? CNS lymphoma / ? Neurosarcoidosis

Macroscopic: Biopsy - Sphenoid sinus.

Microscopic: Section studied shows fragments of bony spicules, surrounded by dense fibrotic stroma exhibiting inflammatory infiltrate composed of lymphocytes and histiocytes. Adjoining focus shows a tiny fragment of tissue lined by dilated columnar epithelium with stroma showing inflammatory infiltrate composed of lymphocytes, histiocytes and proliferating thick and thin walled vessels.

Impression : Chronic inflammatory pathology. Suggested Repeat Biopsy from representative site if clinically warranted

Date: 3/8/20

PROFESSOR OF PATHOLOGY
GOVT. ROYAPETTAH HOSPITAL
CHENNAI-600014.

Investigations:

Blood sugar	85 mg/dL	T-Bilirubin	0.7 mg/dL	Hemoglobin	12gm/dL
Blood urea	24mg/dL	D.bilirubin	0.3U/L	TC	10700 cells/mm3
Sr. creatinine	0.7mg/dL	SGOT	26U/L	DC	P71L22
Sr. sodium	137mEq/L	SGPT	47U/L	Platelet count	5.19 lakhcells/mm3
Sr. potassium	3.6mEq/L	SAP	261 U/L	RBC	
Triglyerides	150	T.Protein	7.8	ESR	18
Total cholesterol	208	Albumin	3.6	Urine R/E	
HDL -C	34	CXR	Normal	ECG:	Normal sinus rhythm

MRI Brain8/7/20-Soft tissue lesions in b/l orbits extending to pterygopalatine fossa, inf/sup orbital fissure, cavernous sinus.Extraocular muscle infiltration. Lesion in left infratemporal fossa and masticator space, infiltrating pterygoid muscles. Erosion of sphenoid. Left frontal dural thickening. Left parotid gland and ramus of mandible not visualised.

Sphenoid lesion with extension to bilateral orbit encasing the bilateral optic nerve. Dural extension+ ? Lymphoma ?Neurosarcoidosis

CT Chest normal, no enlarged hilar lymphadenopathy

CECT base of skull/sinuses 31/8/20 –non enhancing soft tissue lesion in sphenoid sinus extending to b/l orbitsthrough superior orbital fissure.Erosion noted involving sphenoid, sella turcica, clivus. s/o lymphoma.

VDRL –nr HIV- nr
Csf glucose-57 Csfprotein-35, acellular

CSF genexpertNEG.

Nasal swab fungal C/S,KOH NEG.

S. ACE 43 (Normal)

Vasculitic work up NEG, S. IgG4 reports awaiting.S. Electrophoresis, TFT report pending.

USS Abdomen – NAD

Hematology 3154/20 → TC 20800, N49 L47 E4, Hb 11.1, PLT 5.27L, ESR 20, Atypical lymphocytes.

Sphenoid biopsy (slide review) –dense fibrocollagenous tissue with infiltration by histiocytes and lymphoid cells. Some foci has scattered plasmacytoid cells. ?plasmacytoma ?Histiocytosis.Advised IHC for CD138, Kappa, Lambda, Langerin.

Volume 4, Issue 4; July-August 2021; Page No 104-109

Sample Type : Serum Report Status : Final Report
Client Address : No.60,100 Feet Road, Vodapalani,Chennai

CLINICAL BIOCHEMISTRY

Test Name	Obtained Value	Units	Bio. Ref. Intervals (Age/Gender specific)	Method
PDF Attached				
Protein Electrophoresis (Serum)				
Albumin Fraction	**3.02**	g/dl	3.20 - 5.00	Agarose gel Electrophoresis
Alpha 1-globulin	**0.46**	g/dl	0.10 - 0.40	Agarose gel Electrophoresis
Alpha 2-globulin	**1.08**	g/dl	0.60 - 1.00	Agarose gel Electrophoresis
Beta globulin	1.28	g/dl	0.60 - 1.30	Agarose gel Electrophoresis
Gamma-globulin	**2.25**	g/dl	0.70 - 1.50	Agarose gel Electrophoresis
Protein,Total	**8.10**	g/dl	6.0 - 8.0	Biuret
A/G Ratio	**0.60**		1.0 - 2.1	Calculated
Myeloma Band (M-Band)	0.0	g/dl	0.0	
No Monoclonal band observed.				

Impression .Suggestive of Hypergammaglobulinemia with raised Alpha - globulins
Advise Please correlate clinically.

Comments:

- A homogeneous spike-like peak in a focal region of the Gamma-Globulin zone indicates a monoclonal Gammopathy. Monoclonal Gammopathies are associated with a clonal process that is malignant or potentially malignant, including Multiple Myeloma, Waldenstrom's Macroglobulinemia, solitary Plasmacytoma, smoldering Multiple Myeloma, monoclonal Gammopathy of undetermined significance, plasma cell Leukemia, heavy chain disease and Amyloidosis.
- M-protein (in the gamma region) level greater than 3 g/dL should be interpreted along with other radiologic and haematological findings to arrive at a diagnosis of Multiple Myeloma and must not be considered in isolation. Occasionally M protein may appear as a narrow spike in the beta or alpha2 regions also. Up to one-fifth of patients with Myeloma may have an M-protein spike of less than 1 g/dL.
- Hypogammaglobulinemia on serum protein electrophoresis occurs in about 10% of patients with Multiple Myeloma who do not have a serum M-protein spike. Most of these patients have a large amount of Bence Jones Protein (monoclonal free Kappa or Lambda chain) in their Urine, wherein Urine protein electrophoresis should be performed. Monoclonal Gammopathy is present in up to 8 percent of healthy geriatric patients.

Correlate Clinically. Result rechecked and verified for abnormal cases.

*** End Of Report ***

DR. PRATAP PATIL
MD PATHOLOGY

Page 1 of 1

Note: If the test results are alarming or unexpected,Client is advised to contact the laboratory immediately for possible remedial action.

Serum Protein Electrophoresis Report

Patient Name : Mrs. SUNITHA ASEERVADHAM 29-03-21 4:29:41PM
Sex/Age : 36 YRS/Female
Vial ID : K2587556
Total Protein : 8.1

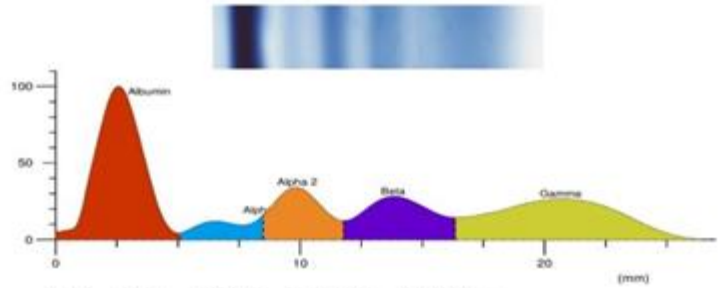

Index	Band	Rel. Area	Conc. (g/dL)	Range (g/dL)
1	Albumin	37.33%	3.02 L	3.20 ... 5.00
2	Alpha 1	5.72%	0.46 H	0.10 ... 0.40
3	Alpha 2	13.37%	1.08 H	0.60 ... 1.00
4	Beta	15.83%	1.28	0.60 ... 1.30
5	Gamma	27.76%	2.25 H	0.70 ... 1.50
Total			8.10	

Ratio A/G 0.60

Comments :

Volume 4, Issue 4; July-August 2021; Page No 104-109

DISCUSSION

DEFINITION:

Plasma cell neoplasm can be classified into Multiple myeloma and solitary plasmacytoma, Extramedullary plasmacytoma.EMP is plasma cell tumor which involve the submucosal lymphoid tissue of the nasopharynx or paranasal sinuses without bone marrow plasma cell proliferation and systemic features of myeloma. It rarely recur and evolve into multiple myeloma while comparing to solitary plasmacytoma.

INCIDENCE:

EMP accounts for less than 4% of all plasma cell tumors. The estimated global incidence of the disease is 1 case per 500,000 people. Median age at diagnosis of EMP is 55 to 60 years with a male/female ratio of 3:1. Only a few cases of EMP (15 to 20%) progress to multiple myeloma.

CLINICAL FEATURES:

EMP mainly occur in upper respiratory tract, especially the submucosa of the nasal cavity, paranasal sinuses, nasopharynx, oropharynx, and larynx.90% of the extramedullary plasmacytoma cases are found in the head and neck. Presence of cervical lymph nodes involvement at diagnosis ranges from 5 to 20% of cases. Symptoms and signs of EMP manifest depending upon tumor site. Like, In sinonasal EMP Unilateral nasal obstruction is the most common presenting symptom.

STAGING

Batsakis defined five possible stages:

I. Localized disease; solitary, controlled by surgery, radiotherapy, or both; without recurrence or dissemination.

II. Disease with local recurrence controlled by additional therapy.

III. Aggressive disease, persistent or recurrent; death by uncontrollable local extension.

IV. Local disease with regional lymph node “metastasis” without evidence of distant spread.

V. Local disease followed by dissemination and development of another neoplasm of plasma cells.

DIAGNOSTIC CRITERIA:

1. Biopsy-proven solitary lesion of bone or soft tissue with evidence of clonal plasma cells.

2. Normal bone marrow with no evidence of clonal plasma cells.

3. Normal skeletal survey.

4. Absence of systemic features of myeloma as hypercalcemia, renal insufficiency, anemia, or bone lesions (CRAB).

TREATMENT:

Gold standard therapy for EMP is radiotherapy. MP is highly radiosensitive with 80 to 100% of patients successfully achieving local control and 50 to 65% 10year disease-free survival rate.

CONCLUSION:

EMP can also occur in age group of 30-40 years against usual occurrence of above 50 years age. It may also occur in females though it is more common in males. In this case, EMP has spread from sphenoid sinus into bilateral orbits and surrounding structures except brain parenchyma. So, It seems that EMP more likely spreads through lymphatics.

REFERENCES

1. Kuppersmith R B Extramedullary plasmocytoma of the head and neck [Internet] [Cited 1996]
2. Extramedullary nasal plasmacytoma: Literature review and a rare case report Marco Antonio dos Anjos Corvo,1 Lídio Granato,2 Felipe Ikeda,3 and José Donato de Próspero4.
3. Batsakis J G. Plasma cell tumors of the head and neck. Ann Otol Rhinol Laryngol. 1992; 92:311–3.
4. Wiltshaw E. The natural history of extramedullary plasmocitoma and its relation to solitary mieloma of bone and myelomatosis. Medicine. 1976; 55:217–38.
5. Upall H S, Harrison P. Extramedular Plasmocitoma of the larynx presenting with upper airway obstructionin in a patient with longstanding IgD myeloma. Laryngol Otol. 2001;115(9):745–6.

Volume 4, Issue 4; July-August 2021; Page No 104-109