(International Print/Online Journal)

SJIF IMPACT FACTOR: 5.565
PUBMED-National Library of Medicine ID-101739732

ISSN (Print): 2209-2870
ISSN (Online): 2209-2862

International Journal of Medical Science and Current Research (IJMSCR)
Available online at: www.ijmscr.com
Volume 4, Issue 3, Page No: 113-115
May-June 2021

# Anaesthetic Management of a Patient withCoarctation of Aorta for Balloon Dilatation

**Nisha Jha[1], Nikhil Yadav[2], Manikanta Goda[3]**
[1]Senior Resident, [2]Assistant Professor, [3]Junior resident
Department of Anaesthesiology, MGIMS, Sewagram

***Corresponding Author:**
**Nisha Jha**
Department of Anaesthesiology, MGIMS, Sewagram

Type of Publication: Case Report
Conflicts of Interest: Nil

**ABSTRACT**

Coarctation is abnormal narrowing of Aorta which arises at junction of ductus arteriosus and aortic notch. It may present in neonatal period, early childhood or adulthood. The anesthetic management of these patients is challenging because of severity and presence of associated defects. We report a case of post ductal coarctation that underwent balloon dilatation for re-coarctation with LV Dysfunction mild PAH. Patient was scheduled for elective procedure after proper preoperative evaluation. Hemodynamics was stable perioperatively and post op recovery was satisfactory.

**Keywords**: Anesthetic management, coarctation of aorta, congenital heart disease, pediatrics

## INTRODUCTION

Coarctation of aorta refers to discrete narrowing of the aortic lumen, typically located adjacent to the insertion of ductus arteriosus, causing varying degrees of left ventricular pressure overload and decreased lower body perfusion. Coarctation of aorta occurs in 1.7 to 4 per 10 000 live births and represents 7.5% of congenital heart disease.(1) Coarctation often occurs with other congenital heart anomalies most commonly Bicuspid aortic valve(60%), followed by distal arch hypoplasia (14.2%), VSD (12.8%) and PDA(7%).(2)

Neonatal and infant coarctations are repaired surgically because balloon dilation without stent placement does not have satisfactory results. But if the baby presents with severe LV dysfunction, balloon dilation serves to decrease the load on ventricle. Theoretically, in such a high risk patient balloon dilation would be less risky than performing a surgical repair. The ideal age for surgical repair is 3 to 5 years. Infants who develop severe symptoms prior to this age may be managed temporarily with balloon dilatation. Because significant obstruction occurs when the diameter of the aorta is reduced by 50% or more, delaying surgery until age 3-5 years allows the aorta to be larger than half the anticipated adult size at operation, theoretically reducing the risk of significant residual obstruction in the event that the surgical repair site does not grow over time.(3). A major disadvantage however is the high rate of re coarctations after balloon dilatation compared to surgical repair.(4) Other treatment options include administration of IV Prostaglandin E1, stent placement and surgical repair.(5)

Anesthetic management of these patients is challenging because blood flow is reduced distal to the coarctation. Thus a slight fall in BP can compromise the perfusion to various vital organs. Also severe coarctation may complicate to cause LV Dysfunction, Pulmonary artery Hypertension or heart failure. Post-ductal stenosis also poses major risk of cerebral hemorrhage and bacterial endocarditis. (6) During balloon dilatation there are chances of Aortic rupture or Perforation. So careful hemodynamic monitoring is needed.(5)

## Case report

A 10-month old infant (weight 7kg) was admitted with history of failure to thrive since birth. The patient had earlier been admitted at 2 months of age with severe coarctation with LV dysfunction and sepsis, and was managed with balloon dilatation after prior stabilization. Post procedure the patient was kept on furosemide and digoxin oral syrups. During pre-anesthetic checkup, mother gave history of increased respiratory activity and sweating over forehead while feeding. On examination, HR was 134bpm, RR 36/min, systolic blood pressure in right upper limb was 100 mmHg. Femoral pulses were not palpable. On CVS examination, patient had cardiomegaly with cardiac apex in the sixth intercostal space outside midclavicular line and ejection systolic murmur in the left second intercostal space. Chest examination showed bilateral basal crepitations. 2D Echocardiography and Pulse wave Doppler was done, estimated pulmonary artery systolic pressure was 40 mmHg and ejection fraction was 45%. The coarct segment measured 2.0 mm, the arch and descending aorta measured 7mm and 6mm respectively.

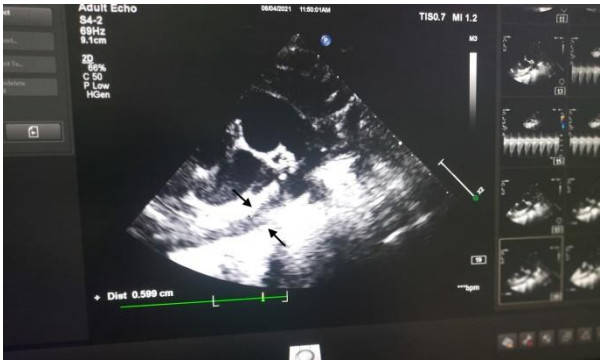


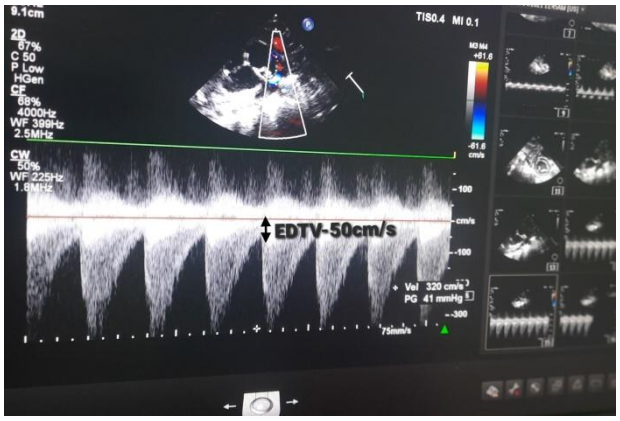


After taking informed written consent from the parents, patient was taken inside Cath Lab. Cardiac emergency drugs and resuscitation equipments were kept ready. Patient was premedicated with IV Midazolam(0.15mg). Inj monocef (180 mg) was given as antibiotic prophylaxis. Anticholinergics and Ketamine were avoided to avoid increase in HR and BP. On securing invasive arterial monitoring in right arm and right foot systolic blood pressures were 100mmHg and 60 mmHg respectively. Induction was done with Inj Fentanyl(14mg) and Inj Propofol(14mg). Airway secured with pLMA (1.5) and maintained with sevoflurane on spontaneous ventilation. Balloon dilatation was performed using percutaneous retrograde femoral arterial approach with balloon catheter 7mm*4cm. The gradient across the coarctation segment dropped from 40 mm Hg to 20 mm Hg .Post-angioplasty ascending aorta 105/55mmHg, descending aorta 88/60 mmHg. Patient was closely monitored during procedure for any arrhythmias or hypersensitivity and procedure time kept minimum. PCM suppository was used for analgesia. Careful extubation was done after complete awakening. There were no local arterial complications after the procedure. The patient was discharged on maintenance dose of digoxin without any diuretics.



Volume 4, Issue 3; May-June 2021; Page No 113-115

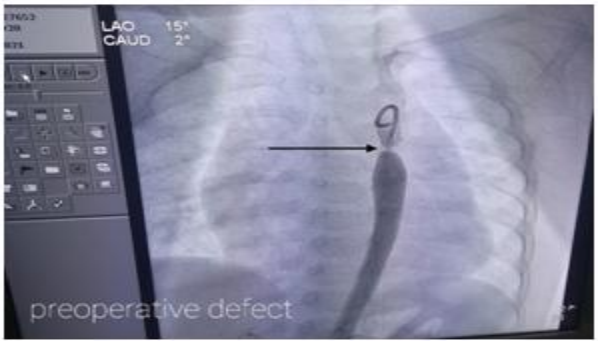


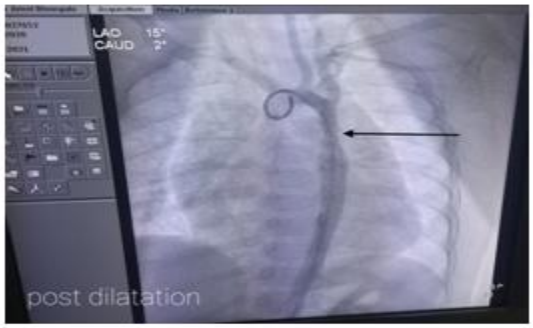


## Discussion

The blood flow across a stenosed artery depends on the pressure proximal to the stenosis. If the proximal pressure decreases, the flow across the stenosis decreases and thus in CoA one should monitor distal aortic pressure (pressure distal to CoA). Anesthetic goals aim at maintenance of higher arterial blood pressure (ABP) proximal to coarctation, so as to keep ABP distal to coarctation above 60 mmHg.(2)

Our patient also had signs and symptoms of congestive cardiac failure with PAH. So, our Anesthetic management goals included avoiding factors that increase baseline pulmonary vascular resistance, maintaining preload while avoiding fluid overload, maximizing right ventricular oxygen supply (ie, RV perfusion and subendocardial blood flow), while minimizing RV oxygen demand (ie, RV afterload, tachycardia) (7)

In the setting of a previous repair of coarctation , the patient was at increased risk of dilated ascending or descending aorta, formation of pseudoaneurysms, upper limb hypertension, cerebral aneurysm and hemorrhage(8). All aseptic precautions and antiobiotic prophylaxis was given to minimize chances of bacterial endocarditis.

Balloon dilatation relieved severe coarctation in this patient with minimal residual gradient and satisfactory outcome. Another major concern of angioplasty is the incidence of post-procedure aneurysm formation and recoarctation. Elective surgical treatment can be planned after 2 years of age. Here, balloon dilatation was done successfully with immediate result.

## Conclusion

Patients with coarctation need meticulous preoperative evaluation of cardiac and respiratory status. In this patient, balloon dilatation was done under GA with spontaneous ventilation. Smooth induction and emergence helps in maintaining stable hemodynamics of the patient.

## References:

1. Hoffman JIE, Kaplan S. The incidence of congenital heart disease. J Am Coll Cardiol [Internet]. 2002;39(12):1890–900. Available from: http://dx.doi.org/10.1016/S0735-1097(02)01886-7
2. Fox EB, Latham GJ, Ross FJ, Joffe D. Perioperative and Anesthetic Management of Coarctation of the Aorta. Semin Cardiothorac Vasc Anesth. 2019;23(2):212–24.
3. MCGREGOR M, MEDALIE M. Coarctation of the aorta. Br Heart J. 1952;14(4):531–3.
4. Redington AN, Booth P, Shore DF, Rigby ML. Primary balloon dilatation of coarctation of the aorta in neonates. Br Heart J. 1990;64(4):277–81.
5. Diethrich EB. Endovascular management of coarctation of the aorta. Inflamm Response Cardiovasc Surg. 2013;355–66.
6. Young RS, Liberthson RR, Zalneraitis EL. Cerebral hemorrhage in neonates with coarctation of the aorta. Stroke. 1982;13(4):491–4.
7. Pritts CD, Pearl RG. Anesthesia for patients with pulmonary hypertension. Curr Opin Anaesthesiol. 2010;23(3):411–6.
8. Groenemeijer BE, Bakker A, Slis HW, Waalewijn RA, Heijmen RH. An unexpected finding late after repair of coarctation of the aorta. Netherlands Hear J. 2008;16(7):260–3.



Volume 4, Issue 3; May-June 2021; Page No 113-115