



## A Comparative Study of Usefulness of Topical Placental Extract versus Topical Colloidal Silver in the Management of Diabetic Foot Ulcer

Dr Sharath K<sup>1</sup> Dr Mohankumar K<sup>2</sup>

\*Corresponding Author:

Dr Sharath K

840 Kubs 8th Cross Jnanabharathi Layout R V Vidyanikethan, Bangalore, Karanataka

Type of Publication: Original Research Paper

Conflicts of Interest: Nil

### ABSTRACT

#### Background:

Diabetic foot is defined as a group of syndromes in which neuropathy, ischemia and infection with multidisciplinary approach with conventional treatment lacking necessary growth factors so to augment healing process. The aqueous form of placental extract contains numerous growth factors and antimicrobial action of nano particles of colloidal silver augmenting tissue regeneration.

**Objectives:** To compare the effectiveness of both in terms of decrease in the size of ulcer and duration of ulcer healing in the management of diabetic foot ulcers.

**Study design:** The study is a randomized prospective study conducted in R.L. Jalappa Hospital and research center from December 2018 to December 2020.

**Methodology:** A total sample of 60 divided into two group by even and odd method. Patient with DFU satisfying inclusion criteria were included in the study. Placental extract of 0.25% concentration topical application for group A and colloidal silver of 0.002% concentration of topical application for group B patient were applied with dressing being changed daily. The weekly observation of ulcer in term of reduction in size, appearance of granulation tissue and clearance of necrotic tissue and was measured and recorded.

**Results:** Placental extract application in DFU shows better healing rates in term of reduction in size, appearance of granulation tissue and reduction of necrotic tissue than colloidal silver.

**Conclusion:** The use of placental extract showed better response in terms of ulcer size reduction, appearance of granulation tissue and clearance of necrotic tissue. HbA1c has a linear association in healing of ulcers.

**Keywords:** Diabetic foot ulcer, Placental extract dressing, colloidal silver dressing.

### INTRODUCTION

Diabetic foot may be defined as a group of syndromes in which neuropathy, ischemia and infection lead to tissue breakdown resulting in morbidity and possible amputation.<sup>1</sup> The multidisciplinary approach includes strict control of blood glucose, prevention through education and regular dressings. Conventional treatment lack in necessary growth factors to augment healing process.<sup>2,3</sup>

The Human placenta extract contains various growth factors, Interleukin promoting neovascularisation, monocyte chemotaxis, collateral vessel growth and bone marrow precursor derived mobilisation, hence enhance wound healing.<sup>4 5 6</sup> Immunostimulant action of placenta at cellular level so acting as antibiotics coverage.<sup>7 8</sup>

The colloidal silver markedly expand the surface area of silver particles so as to increase the contact

with micro-organisms and act as bactericidal by blocking cellular respiration by inhibiting cytochrome enzyme, interfering with electron transport and disruption of bacterial cell membranes.<sup>9</sup> Thus exhibiting antiseptic, antimicrobial, anti-inflammatory properties.<sup>10 11</sup>

**Objectives:** To compare the effectiveness of both in terms of decrease in the size of ulcer and duration of ulcer healing in the management of diabetic foot ulcers.

## METHODOLOGY:

The study is a randomized prospective study conducted in R.L.Jalappa Hospital & Research center from December 2018 to December 2020 with a study sample size of 60 divided into two groups by even odd method.

## INCLUSION CRITERIA

All the patients with type 2 Diabetes Mellitus with DFU of Wagner's grade 1,2 and 3.

## EXCLUSION CRITERIA

1. Patients with DFU having peripheral vascular disorder and varicose veins.
2. Patients with immune-compromised status.

## METHOD OF COLLECTION

The patients satisfying the inclusion criteria were included with ulcers stabilised initially with wound debridement. Patient in group A were managed with Placental extract gel form of 0.25% w/w and group B with colloidal silver gel form of 0.002% w/w concentration topical application of 1ml/sqcm. The ulcer was closely observed for reduction in

size, appearance of granulation tissue & decrease in slough. Microbiological parameters were assessed by culture and sensitivity from discharge or biopsy from the ulcer and treated with appropriate antibiotics either intravenously or orally. The concomitant management of DM with appropriate nutritional and anti-diabetic treatment according to glycaemic status was administered.

**Ulcer size measurement:** The wounds with regular shape was measured by multiplying the longest diameter in length and width and irregular ulcers were measured by marking the margins of the ulcer and adding up of small boxes(each small box measuring 1sqcm) drawn over a transparent sheet. The percentage of reduction in ulcer size was calculated weekly using the below formula.

$$\text{Reduction in size} = \frac{\text{Initial size} - \text{final size}}{\text{Initial size}} \times 100$$

## STATISTICAL ANALYSIS

The analysis of the obtained data was by using SPSS 22 version software. Categorical values was represented in the form of Frequencies and proportions. Chi-square test was used as test of significance for qualitative data. Continuous data was represented as mean and standard deviation. Mean difference was calculated using independent t test as test of significance between two quantitative variables. p value <0.05 was considered as statistically significant. The confidence interval was 95% with power of study was 90%. Test of statistical significance - Student t test or paired t test

$S_1^2$  : Standard deviation in the first group

$S_2^2$  : Standard deviation in the second group

$\mu_d^2$  : Mean difference between the samples

$\alpha$  : Significance level

$1 - \beta$  : Power

The visual scores for the percentage of wound covered:

## Necrotic tissue

1. 76-100% of wound covered by necrotic tissue

2. 51-75 of wound covered by necrotic tissue
3. 26-50% of wound covered by necrotic tissue
4. 11-25% of wound covered by necrotic tissue
5. 0-10% of wound covered by necrotic tissue
6. No necrotic tissue covering the ulcer

### Granulation tissue

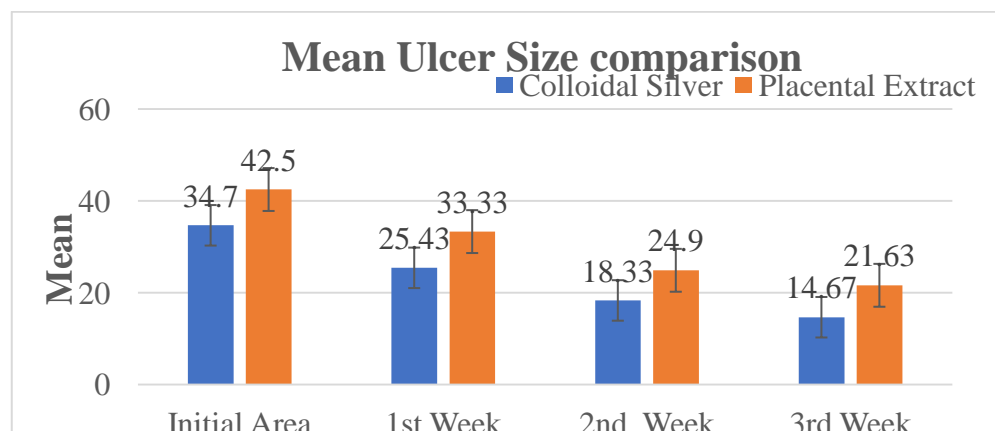
1. No granulation tissue covering the ulcer
2. Pink/dull <25% wound filled
3. Bright beefy 25-74% wound filled
4. Bright beefy red 75-100% wound filled

## RESULTS:

**Table 1: Mean Ulcer Size comparison between two groups**

	Group				P value
	Colloidal Silver		Placental Extract		
	Mean	SD	Mean	SD	
Initial Area	34.7	20.63	42.5	24.07	0.183
1 <sup>st</sup> Week	25.43	15.98	33.33	19.99	0.096
2 <sup>nd</sup> Week	18.33	12.28	24.9	14.85	0.067
3 <sup>rd</sup> Week	14.67	8.83	21.63	11.15	0.010*

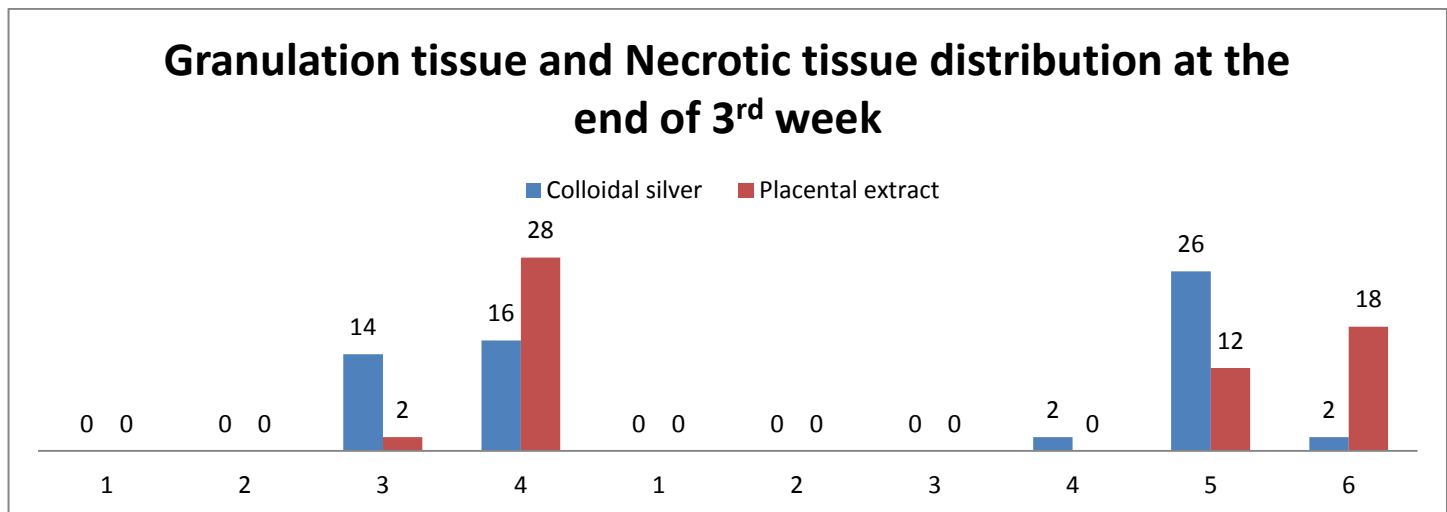
The mean ulcer size at presentation of colloidal silver and placental extract was 34.7mm and 42.5mm respectively.. The size reduction( sqcm) in the colloidal silver group was 25.43(73%), 18.33(72%) and 14.67(81%) in 1<sup>st</sup>, 2<sup>nd</sup> and 3<sup>rd</sup> week respectively. In the placental extract group the reduction in size of ulcer was 33.3(77%) in 1<sup>st</sup> week, 24.9(74%) in 2<sup>nd</sup> week and 21.63(88%) in 3<sup>rd</sup> week. There was no significant difference in mean ulcer from baseline to 2<sup>nd</sup> week between two groups. There was significant difference in mean Ulcer size at 3<sup>rd</sup> week between two groups with increased reduction seen in placental extract group. The mean percentage reduction in ulcer size in Colloidal Silver group was  $22.57 \pm 13.81$  mm and in Placental Extract group was  $29.68 \pm 16.46$  mm.



**Graph 1: Bar diagram showing Mean Ulcer Size comparison between two groups**

**Table 2: Granulation tissue and Necrotic tissue distribution at the end of 3<sup>rd</sup> week**

End of 3 <sup>rd</sup> week	Visual Scores											
	Granulation tissue				p value	Necrotic tissue						p value
	1	2	3	4		1	2	3	4	5	6	
Colloidal Silver	0	0	14(46%)	16(53.3%)	0.001	0	0	0	2(6.6%)	26(86.6%)	2(6.6%)	<0.001
Placental Extract	0	0	2(6.6%)	28(93.3%)		0	0	0	0	12(40%)	18(60%)	

**Graph 2: Granulation tissue and Necrotic tissue distribution at the end of 3<sup>rd</sup> week.**

**Granulation tissue:** The majority of subjects in both the groups were in bright beefy red granulation tissue with 16(53.3%) and 28(93.3%) i.e. in colloidal silver and placental extract group respectively. There was significant difference in appearance of Granulation tissue between two groups at 3<sup>rd</sup> week with p value of 0.001.

**Necrotic tissue:** In colloidal silver group necrotic tissue coverage of 0-10% was predominantly seen in 26(86.67%) subjects. In placental extract group most of the subjects had no necrotic tissue i.e. 18(60%). Necrotic tissue(%) was significant between the groups at 3<sup>rd</sup> week.

**Table 3: Mean Age and Sex Comparison between two groups**

	Group				P value
	Colloidal Silver		Placental Extract		
	Mean	SD	Mean	SD	
Age	56.47	11.8	56.87	9.93	0.888
Sex	Female	10	33.33%	8	26.67%
	Male	20	66.67%	22	73.33%

The majority of subjects were in the age of 50-60 years. In Colloidal Silver group, majority of subjects were in the age group 61 to 70 years (43.3%) and in Placental Extract group, majority of subjects were in the age group 51 to 60 years (60%). There were male predominance comprising of 42 (70%) subjects.

The observation on Mean HbA1c levels in Colloidal silver group was  $9.36 \pm 2.42$  % and in Placental Extract group was  $8.85 \pm 2.41$  % with no significant difference in HbA1c (%) between two groups.

### DISCUSSION:

Diabetic foot is a group of syndromes with neuropathy, ischemia and infection leading to tissue breakdown resulting in morbidity and possible amputation. The multidisciplinary approach in the management of DFU includes strict control of blood glucose, prevention through education and regular dressings. The need of regular appropriate dressing for the ulcer and proper education of the disease and footcare are essential in the ulcer treatment. The aqueous form of placental extract contains various growth factors, bioactive peptides, amino acids promoting neovascularisation, tissue regeneration and antimicrobial action. The silver ions acts by breaking of cell wall of micro-organisms and reducing the proinflammatory cytokines so to promote wound healing.

The mean ulcer size reduction was significantly higher in placental extract group in comparison to colloidal silver with p value of 0.075. Both the agents were at most similar up to 2 weeks with placental extract being a better agent in later period

with 21.63(88%) reduction in 3<sup>rd</sup> week. The placental extract group had significantly very good progression of granulation tissue in 2<sup>nd</sup> and 3<sup>rd</sup> week compared to colloidal silver group (p 0.001) in all three weeks.

The aqueous form of placental extract contains numerous growth factors rendering antimicrobial effect and neoangiogenesis thus preparing bed for granulation tissue. The interleukin 1-4, colony stimulating factor which are natural constituents of placental extract promotes chemotaxis of monocytes and inhibit MMP, thus attributing to better clearance of necrotic tissue. The early appearance of granulation tissue and clearance of necrotic tissue needs less local debridement and decrease the span of ulcer healing and so the hospital stay.

The results are comparable with similar other studies i.e a study in 2017 on topical application of placental extract on diabetic foot ulcer by Zeng X et al<sup>12</sup> and a comparative study by Navadiya et al<sup>13</sup> Tiwary et al<sup>14</sup> wherein it was observed that patient treated with placental extract had a better healing rate as compared to other agents.

The study results showed DFU are common in elderly i.e 5<sup>th</sup>-6<sup>th</sup> decade with male predominance explaining the slow and silent progression of the disease in comparable with other similar studies.<sup>15 16</sup>

The study shows a linear association of HbA1c levels with healing rates and emphasizing the appropriate glycemic control by dietary and medical aids.<sup>17</sup>

### CONCLUSION

In the present study we observed irrespective of age, sex, site and mode of onset of diabetic foot ulcer the patient who were treated with placental extract agent had better outcome in terms of reduction in size of

#### References:

1. Kasiya MM, Mang'anda GD, Heyes S, Kachapila R, Kaduya L, Chilamba J, Goodson P, Chalulu K, Allain TJ. The challenge of diabetic foot care: Review of the literature and experience at Queen Elizabeth Central Hospital in Blantyre, Malawi. *Malawi Medical Journal*. 2017;29(2):218-23.
2. Alvarsson A, Sandgren B, Wendel C, Alvarsson M, Brismar K. A retrospective analysis of amputation rates in diabetic patients: can lower extremity amputations be further prevented?. *Cardiovascular diabetology*. 2012 Dec 1;11(1):18.
3. Tran TD, Le PT, Van Pham P. Diabetic foot ulcer treatment by activated platelet rich plasma: a clinical study. *Biomedical Research and therapy*. 2014 Mar 22;1(2):37-42.
4. Gupta V, Sinha A, Jithendra KD, Chauhan SS, Singh S. Placental extract- the magical wound healer, next milestone in the healing of periodontal surgery. *IOSR journal of dental and medical sciences* Nov 2016; Vol 15, issue 11 ver.IV:73-79.
5. Qi M, Zhou Q, Zeng W, Wu L, Zhao S, Chen W, Luo C, Shen M, Zhang J, Tang CE. Growth factors in the pathogenesis of diabetic foot ulcers. *Front Biosci (Landmark Ed)*. 2018 Jan 1;23:310-7.
6. Cianfarani F, Zambruno G, Brogelli L, Sera F, Lacal PM, Pesce M, Capogrossi MC, Failla CM, Napolitano M, Odorisio T. Placenta growth factor in diabetic wound healing: altered expression and therapeutic potential. *The American journal of pathology*. 2006 Oct 1;169(4):1167-82.
7. Vivek VJ, Nagateja MV. A comparative analysis of the merits of topical placental extract over conventional methods of dressings for diabetic foot ulcers. *Journal of Evolution of Medical and Dental Sciences*. 2017 Feb 9;6(12):963-7.
8. Dr. Akarsh, Y. G. and Dr. Nischal, K., "A comparative study of topical human placental extract with topical sucalfate in the management ", *International Journal of Current Research*, 8, (03), 28501-28503.
9. Tsang KK, Kwong EW, Woo KY, To TS, Chung JW, Wong TK. The anti-inflammatory and antibacterial action of nanocrystalline silver and manuka honey on the molecular alternation of diabetic foot ulcer: a comprehensive literature review. *Evidence-Based Complementary and Alternative Medicine*. 2015 Jan 1;2015.
10. Original Article J of Evidence Based Med & Hlthcare, pISSN- 2349-2562, eISSN- 2349-2570/ Vol. 2/Issue 45/Nov. 05, 2015 Page 8164
11. Nair HKR. Nano-colloidal silver and chitosan bioactive wound dressings in managing diabetic foot ulcers: case series. *J Wound Care*. 2018;27(Sup9a):S32-S36.
12. Zeng X, Tang Y, Hu K, Jiao W, Ying L, Zhu L, Liu J, Xu J. Three-week topical treatment with placenta-derived mesenchymal stem cells hydrogel in a patient with diabetic foot ulcer: A case report. *Medicine*. 2017 Dec;96(51).
13. Navadiya SK, Vaghani YL, Patel MP. Study of topical placental extract versus povidone iodine and saline dressing in various diabetic wounds. *Natl J med res*. 2012;2(4):411-3.
14. Tiwary SK, Shukla D, Tripathi AK, Agrawal S, Singh MK, Shukla VK. Effect of placental-extract gel and cream on non-healing wounds. *Journal of wound care*. 2006 Jul;15(7):325-8.

15. Ravidas. Prospective observational study evaluating association of sociodemographic parameters, Wagner's grading, peripheral arterial disease and diabetic peripheral neuropathy with the outcomes of diabetic foot ulcers. *International Surgery Journal*, 2020; 7(7), 2129-2134.
16. Dinh T, Veves A. The influence of gender as a risk factor in diabetic foot ulceration. *Wounds: a compendium of clinical research and practice*. 2008 May;20(5):127.
17. Farooque U, Lohano AK, Rind SH, Rind Sr MS, Karimi S, Jaan A, Yasmin F, Cheema O. Correlation of Hemoglobin A1c With Wagner Classification in Patients With Diabetic Foot. *Cureus*. 2020 Jul;12(7).