



Cytomorphological study of Lymphadenopathy by FNAC at a Tertiary Care Center in Jaipur, India

Dr. Sheetal Sharma, Dr. Hema Udawat, Dr. Ravi Khandal, Dr. Reetu choudhary
Department of Pathology, RUHS-CMS, Jaipur, Rajasthan, India

*Corresponding Author:
Dr. Sheetal Sharma

Department of Pathology, RUHS-CMS, Jaipur, Rajasthan, India

Type of Publication: Original Research Paper

Conflicts of Interest: Nil

Abstract

Background: Lymphadenopathy is a common clinical presentation with etiologies ranging from benign reactive conditions to malignancies. Fine Needle Aspiration Cytology (FNAC) is a rapid, cost-effective, and minimally invasive diagnostic tool.

Aim: To evaluate the cytomorphological spectrum of lymphadenopathy using FNAC and for diagnostic purpose.

Materials and Methods: This prospective observational study was conducted over 10 months at a tertiary care center in Jaipur. A total of 110 patients presenting with palpable lymph node lesions were included. FNAC was performed, and smears were stained with H&E and MGG stains. Data were analyzed based on age, sex, and cytological diagnosis.

Results: Among 110 cases, males (59.09%) were more commonly affected. The most affected age group was 21–40 years (44.55%). Non-neoplastic lesions (68.18%) predominated over neoplastic lesions (31.82%). Tubercular lymphadenitis (53.33%) was the most common non-neoplastic lesion, while metastatic carcinoma (57.14%) was the most common neoplastic lesion. Among metastatic cases, adenocarcinoma (50%) was most frequent.

Conclusion: FNAC is an effective first-line diagnostic tool in evaluating lymphadenopathy, enabling early diagnosis and appropriate management.

Keywords: NIL

Introduction

Lymphadenopathy is a frequent clinical condition encountered in outpatient settings. It may result from infections, inflammatory conditions, or malignancies. Accurate and early diagnosis is essential for appropriate management.

Fine Needle Aspiration Cytology (FNAC), introduced in the early 20th century, has emerged as a reliable diagnostic modality for evaluating lymph node lesions. It is minimally invasive, cost-effective, and provides rapid results. FNAC is particularly useful in differentiating benign from malignant lesions and can guide further diagnostic and therapeutic decisions.

This study was conducted to evaluate the cytomorphological patterns of lymphadenopathy

using FNAC in patients attending a tertiary care hospital in Jaipur.

Materials and Methods

Study Design Hospital based prospective observational study

Study Duration

10 months (2024–2025)

Study Population

110 patients with palpable lymphadenopathy attending RUHS-CMS and RDBP Jaipuria Hospital, Jaipur.

Inclusion Criteria

Palpable lymph nodes Age 18–60 years

Informed consent obtained

Exclusion Criteria

Deep-seated lymph nodes Inadequate/poorly preserved samples Non-consenting patients

Procedure

FNAC was performed using a 22-gauge needle. Smears were prepared and stained using: Hematoxylin & Eosin (H&E)

May-Grunwald Giemsa (MGG)

Microscopic examination was done, and lesions were categorized into non-neoplastic and neoplastic groups.

Data Analysis

Data were recorded and analyzed using MS Excel.

Results

Demographic Distribution Males: 65 (59.09%)

Females: 45 (40.91%) Male:Female ratio = 1.44:1

Age Distribution 21–40 years: 44.55% (most common) Followed by 41–60 years (21.82%)

Figure 1- Photomicrograph showing granulomas with langhans type giant cells, tubercular lymphadenopathy (H&E 10X)

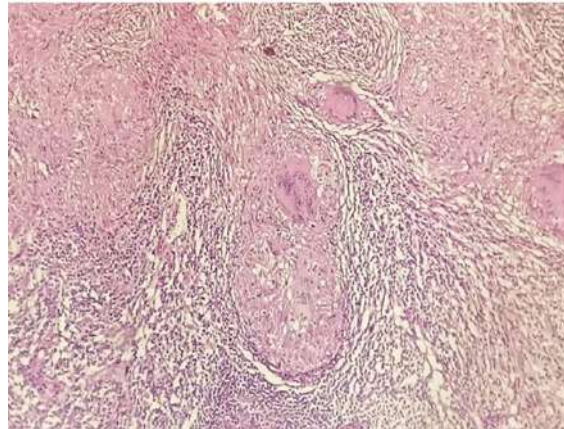

Figure 2 (H&E x 400) Reactive Lymphadenitis: Photomicrograph of cytosmear showing polymorphous population of lymphoid cells in various stages of maturation, tingible body macrophages.

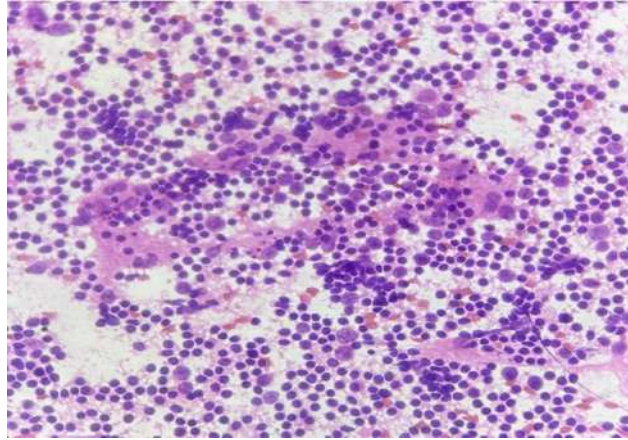


Figure 3– Photomicrograph showing follicles of variable size, reactive hyperplasia of lymph node (H&E 10X)

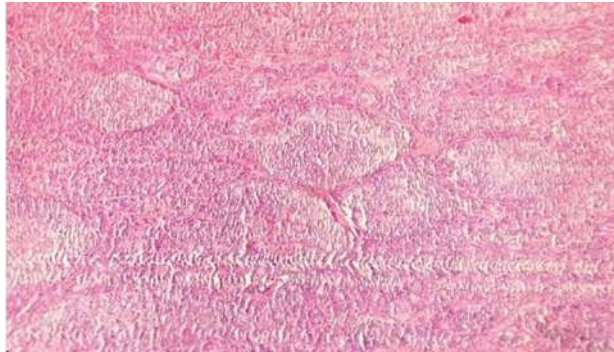


Figure 4 (H&E x 400) Tubercular Lymphadenitis : Photomicrograph of cytosmear showing epithelioid cell granuloma in a necro-inflammatory background

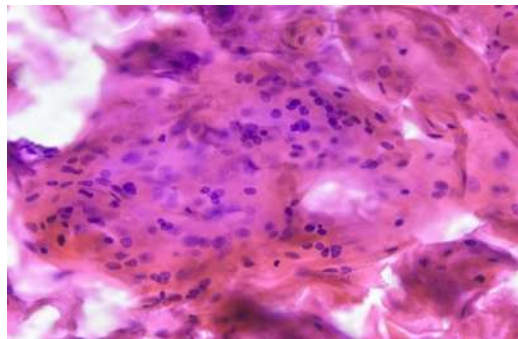
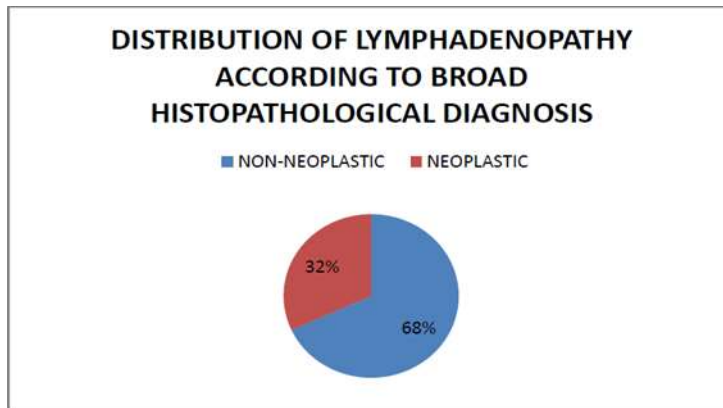


Figure 5 (H&E x 400) Metastatic squamous cell carcinoma:



SEX	NO.	%
MALE	65	59.09%
FEMALE	45	40.91%

Age Wise Distribution Of Various Neoplastic Lymphadenopathies

In present study maximum number of HL are in 21-40 year and minimum number of HL are 0-20 year. Maximum number of NHL is in 0-20 year.

Maximum number of metastatic carcinoma are in 41-60 year and in <20 year metastatic carcinoma.

AGE	HL	NHL	METS. CA.
0-20	1	3	0
21-40	6	1	2
41-60	0	2	10
>60	2	1	7

BENIGN LYMPHADENOPATHY	MAL E	FEMAL E	MALE %	FEMAL E %
TB	19	21	29.23	46.67
RH	10	10	15.38	34.19
CNSL	4	0	6.15	0
SH	3	0	4.62	0
NEC. GRANULOMATOUS	0	2	0	4.44
KIKUCHI	2	0	3.08	0
CASTLEMAN	2	0	3.08	0
ROSAI DORFMAN	0	1	0	2.22
ACUTE SUPPURATIVE	1	0	1.54	0

Gender Wise Distribution Of Non-Neoplastic Lymphadenopathy

In present study female predominance are observed in tubercular, necrotizing granulomatous lymphadenitis and Rosai- Dorfman disease. Male predominance is observed in chronic non- specific lymphadenopathy, Sinus histiocytosis, Kikuchi disease.

Discussion

This study highlights that lymphadenopathy is more common in young adults, with male predominance. The predominance of non-neoplastic lesions aligns with other Indian studies.

Tubercular lymphadenitis was the most common diagnosis, reflecting the high burden of tuberculosis in India. Reactive lymphadenitis was the second most common cause.

Among neoplastic lesions, metastatic carcinoma was more frequent than lymphoma, with adenocarcinoma being the most common subtype. FNAC proved highly useful in detecting metastatic deposits and suggesting primary malignancies.

However, FNAC has limitations in diagnosing lymphomas, where histopathology and immunohistochemistry are often required.

Conclusion

FNAC is a rapid, reliable, and cost-effective diagnostic tool for lymphadenopathy. It effectively differentiates benign from malignant lesions.

Tuberculosis remains the most common cause of lymphadenopathy in this region. FNAC reduces the

need for invasive procedures and facilitates early management.

Limitations

Small sample size (110 cases) Single-center study

Lack of histopathological correlation in all cases
Limited use of ancillary techniques

Recommendation

FNAC should be used as a first-line investigation
Histopathology should confirm suspicious cases
Use of immunocytochemistry is recommended

References

1. Mustaqueem S 1,*, Hassan S 2 , Agarwal S 1
Evaluation of peripheral lymphadenopathy by fine needle aspiration cytology IP International Journal of Medical Paediatrics and oncology 2021;7(2):67–72
2. Mohammed Naeem T – Fine Needle Aspiration cytology (FNAC) and Neck Swellings in the surgical treatments J. Ayub Med. Coll. Abbott bad 2008, 20 (3); 30- 32.
3. Jeong Ha 1,2, , Lee J 3 ,Yeon Kim D 3,4 , Kim J 1 , Soon Shin M 1 , Utility and Limitations of Fine-Needle Aspiration Cytology in the Diagnosis of Lymphadenopathy MDPI Diagnostics 2023, 13, 728,1-15
4. Dharmalingam S 1 , Kumar Sutrarakar S 2 , Jatav J 3 , Verma S 4 Asian Journal of Medical Sciences | Sep 2022 | Vol 13 | Issue 9 227-231
5. Ganguli S, Tyagi MS, Bajpai M, Singh S, Garg PK, Pathre A. Cytomorphological study of lymph node

- lesions at a tertiary care center. Santosh Univ J Health Sci 2022;8:132-6
6. Toppo S 1 , Punjaji T 2* Spectrum of cytology findings in patients presenting with lymphadenopathy at tertiary health care centre in north Maharashtra region- A 2 year study IP Archives of Cytology and Histopathology Research, April-June 2019;4(2):105-109
 7. Dr Tabassum N 1 , Dr. Malik A 2 , Dr Khurshid S 3* Cytopathology of Lymphadenopathy in Patients of Chenab Valley 1 JMSCR Volume 08 Issue 01 2020 538- 544
 8. Chong Y 1 , Park G 1 , Jeong Cha H 2 , Kim H 3 , Kang C 4 , Ghafar J 1 ,journal of Pathology and Translational Medicine 2023; 57: 196-207.