



## Maxillary Sinus Augmentation: A Review Of Current Techniques

<sup>1</sup>Archita Chittoria, <sup>2</sup>Yogendra Malviya, <sup>3</sup>Aparajita Adurti

<sup>1,3</sup>Postgraduate student, <sup>2</sup>Senior Lecturer,

Department of Oral and Maxillofacial Surgery, Jaipur Dental College, Jaipur, Rajasthan, India

**\*Corresponding Author:**

**Archita Chittoria**

M-902, 9th Floor, BPTP Park Elite Premium, Sector 84, Greater Faridabad, Haryana-121002

Type of Publication: Review Article

Conflicts of Interest: Nil

### Abstract

**Introduction:** Sinus ridge augmentation is a surgical procedure aimed at increasing volume of bone in posterior maxilla to permit successful dental implant placement. The current review article presents an overview of various techniques used for sinus ridge augmentation, including lateral window technique, crestal approach, trans alveolar technique, and piezoelectric osteotomy.

**Corpus:** The article examines the advantages and limitations of each technique, such as invasiveness, surgical difficulty, and the requirement for additional procedures. Additionally, the article discusses the factors that influence the success of the procedure, including patient age, residual bone height, and kind of bone graft substance used. The review also emphasizes the importance of proper case selection, surgical planning, and postoperative care to ensure optimal outcomes.

**Conclusion:** Overall, the article provides valuable insights into the current techniques used for sinus ridge augmentation, highlighting the need for further research to improve patient outcomes and the success of placing dental implants over the long run.

**Keywords:** Bone morphogenetic protein; sinus floor augmentation; dental implants

### Introduction

The augmentation graft of maxillary sinus was a crucial component of implant-directed maxillary reconstruction for over three decades [1]. The goal of present article is to give an outline of fundamental principles of maxillary sinus reconstruction, comprising physiology and anatomy of sinus, preoperative assessment, surgical signs, surgical procedures, and management strategies for issues.

### Anatomy & Physiology

The maxillary sinuses are a pair of air-filled cavities located in the bilateral maxillae that are situated laterally to nasal cavity, inferior to orbital floors, superior to maxillary teeth, and anterior to infratemporal fossa (as shown in Figure 1). The average volume of these sinuses is 12.5 mL, making them the biggest of paranasal sinuses [2]. The

maxillary sinuses are coated by Schneiderian membrane, that is composed of cell cambium layer (“Osteogenic Periosteal Layer”) on bone sides and ciliated respiratory epithelium (“Pseudostratified Columnar Epithelium”) on lumen side. The infraorbital nerve travels through the mid of maxillary roof in a posterior-anterior direction. The floor of canal is usually made up of thick bone; though, in a few instances, it may be absent, leaving just a thin mucosal layer between the sinus cavity and nerve [3]. “The sinus ostium is situated on medial wall of nose above the uncinat procedure, and it communicates with the ethmoid infundibulum in middle meatus on the walls of nose. Bony, thin septae that span from lateral to medial sinus wall might be found in up to 37 percent people having 45.9 percent in middle, 22.5 percent in 3rd anterior, and 31.5

percent in posterior sinus. One or two septae are found in 89 percent of individuals with septae” [4].

The position as well as presence of septae in the maxillary sinuses may have an impact on the treatment plan, and if they are not identified before the surgery, it can cause perioperative complications. This will be reviewed in detail later. The cilia of Schneiderian membrane plays a vital function in guiding the discharge of mucus & debris toward the ostium, thereby maintaining constant drainage in normally functioning sinuses. Certain medical conditions may increase the risk of chronic sinusitis in some patients. Allergic rhinitis can cause inflammation of mucosa close to ostium, resulting in inflammation and obstruction of mucous discharge, causing painful sinus pressure and stagnant fluid

infection. Dysfunctional sinus cilia can cause a buildup of mucus & debris, which can cause infection since the sinuses are unable to remove the debris and regular discharge [5].

### Indications & Contraindications Of Sinus Augmentation

The main reason for performing sinus graft surgical procedure is to prepare for posterior maxilla implant reconstruction that has suffered from bone loss after tooth extraction and sinus pneumatization. In such cases, the bone has become too atrophic to support implants (as shown in Table 1). Sinus graft surgery is appropriate for a range of cases, including single-tooth as well as multi-tooth reconstruction, and complete reconstruction of posterior maxilla in edentulous patients.

**Table 1 : Indications For Sinus Lift Surgery. (Stern A, Green J. Sinus Lift Procedures: An Overview Of Current Techniques. Dent Clin North Am 2012: 219-33, X.)**

CONDITION	TREATMENT
Edentulous maxilla with severely atrophic maxilla and pneumatized sinus	Open sinus lift via lateral maxilla sinus antrostomy ; delayed implant placement
Edentulous maxilla with some remaining alveolar bone (0-4mm)	Open sinus lift via lateral maxilla sinus antrostomy ; delayed implant placement
Edentulous maxilla with some remaining alveolar bone (5-10mm)	Open sinus lift via lateral maxilla sinus antrostomy ; immediate implant placement
Single tooth edentulous space with 5-7mm alveolar bone remaining	Open sinus lift via lateral maxilla sinus antrostomy ; immediate implant placement
Single tooth edentulous space with >8mm bone remaining	Open sinus lift via lateral maxilla sinus antrostomy or closed (crestal approach) osteotome technique; immediate implant placement

### Preoperative Assessment

A detailed dental, as well as medical history and physical examination, must be conducted prior to initiating maxillary sinus augmentation surgery. It is important to note any relevant positive history like latest upper respiratory disease, chronic sinus as well as sinusitis, or otitis media, facial pain, past sinus or nasal surgery, prior maxillary reconstruction efforts,

and smoking history. Studies have revealed that the complication risk for smokers who undergo sinus lift grafts is comparable to that of the common population; though, there is an indication that smokers who have implants implanted in sinus transplanted bone have a greater rate of failure in comparison to non-smokers [6,7]. Preoperative CT (“Computed Tomography”) scan is advised to evaluate the volume of bone already present, exclude

pre-existing sinus illness & detect any bony septae [8].

### Informed Consent

Before beginning the maxillary sinus grafting surgery, it is crucial to have an informed consent discussion with the patient. This discussion should cover the benefits, risks, alternatives to process, and the risks of alternatives. Common risks related to the procedure comprise bleeding, pain, swelling, graft failure, infection, and sensory changes to distribute 2nd branch of cranial nerve-V. It is important to note that smokers have a greater risk of implant failure, despite the potential success of graft method. The eventual restoration of the edentulous maxilla is the main advantage of the procedure. The treatment can be substituted with a shorter implant, 3-unit bridge, zygomatic implants, partial dentures, or angled implants. The risks of the alternatives should also be discussed. The patient must understand that the surgery is elective and that the decision to proceed is solely theirs after considering all the possible options. The expected timeframe for dental restoration after the procedure may exceed a year, and additional costs may be incurred. To help the patient understand the informed consent process, multimedia resources such as patient education videos, models, and radiographs can be used.

### Surgical Techniques

According to recent studies, maxillary sinus augmentation may be achieved using two techniques: the sinus intrusion osteotomy technique and lateral window technique. These approaches for vertical augmentation in oral cavity are regarded as the most reliable ones. These procedures can be carried out using many bone graft substances, comprising autogenous bone, xenograft, alloplastic, and allograft substances. Autogenous bone is thought to be “ideal graft” for the sinus lift procedure because it offers enough feasible bone to initially support the implant and promote osseointegration [9]. Recent research has revealed that autogenous bone grafts are the better way because they maintain a sufficient alveolar ridge height for 5-10 years after initial insertion [10]. To enhance the bone amount inserted into maxillary sinus, “demineralized freeze-dried bone” may be combined with autogenous bone. Studies have revealed that adding “demineralized freeze-dried bone” to autogenous bone marginally reduces the

level of bone attained; nevertheless, this change is insignificant clinically because the implants are still enclosed by bone [9].

“Autogenous bone grafts” are reflected to be unique as they contain endosteal osteoblasts, which give them the capacity to form bone directly. Along with osteoblasts, a corticocancellous graft also releases growth hormones and bone morphogenic proteins (BMPs), which promote the production of new bone [11]. The proximal tibia, calvarium, anterior iliac crest, and maxillofacial areas are a few anatomical locations that can be used to harvest bone transplants. These methods, however, are outside the purview of this essay, so we won't go into more detail about how they work.

Several sites, including the maxillary tuberosity, ramus, symphysis, mandibular third molar site, and posterior maxilla, can be harvested for intraoral bone. Even though maxillary tuberosity provides less amount of bone (1-2mL), it is located in a similar surgical field as of lateral technique to maxillary sinus and should be considered [12]. In posterior maxilla, toward hamular notch, a crestal incision is made to obtain the graft, along with any necessary vertical releasing incisions. The incision is prolonged posteriorly to reach the tuberosity when the maxillary sinus is to be accessed via the lateral window technique. The posterior maxilla is shown by raising a full-thickness mucoperiosteal flap, which enables precise bone harvesting with a rongeur. During the procedure, it is crucial to prevent pterygoid plates, maxillary sinus, molar teeth, and larger palatine canal to prevent complications (see Fig. 2).

The symphysis is the location that produces the most intraoral bone [13]. “To gain access to this area, a canine-to-canine vestibular incision is created that must be made at least 3 mm distant from mucogingival junction. The periosteum is raised, and the osteotomy is made 10 mm below the incisor teeth's apex”.

A trephine having a collecting instrument positioned along the suction line is an appropriate instrument for bone harvesting.<sup>9</sup> The cortical plate may be eliminated if required, and the bone marrow can be extracted (Fig. 3). During the procedure, the mental nerve must be avoided, and patient should be created aware of enhanced hazard of V3 paresthesia brought on by this method. Related to this, bone can be

extracted from the third molar sites in the mandible and posterior maxilla using a scraping tool by collecting container coupled to the suction.

Tatum first demonstrated the **lateral window technique** by utilizing a modified Caldwell-Luc method [14]. In this surgical approach, osteotomies are used to create a bone window that is then either removed or turned medially without rupturing the membrane of sinus. First, a “posterior superior alveolar nerve block, a superior anterior alveolar nerve block, and palatal infiltration” are used to administer local anesthesia with epinephrine. A local anaesthetic may be utilized in conjunction to general anaesthesia or intravenous sedation, if necessary. Steroids and antibiotics are often given as preventative measures prior to the surgery, although the decision to use perioperative steroids and antibiotics should be at the discretion of the surgeon. Before beginning the procedure, it is uncertain whether preoperative administration of medication is beneficial or not. Therefore, the surgeon should carefully weigh potential risks and benefits before administering such drugs. Before performing incision, it has been advised to rinse the patient & expectorate by 0.12 percent chlorhexidine solution.

From maxillary tuberosity to position immediately anterior to anterior edge of sinus, the crestal incision is created. In order to expose the sinus without impairing the sinus window, vertical releasing incisions should also be performed on anterior & posterior sides to the depth of vestibule. The maxilla lateral wall should then be revealed by elevating a full-thickness mucoperiosteal flap (Fig. 4). Next, four linear osteotomies should be performed using a #6 or #8 round bur, starting with the inferior horizontal osteotomy must be performed as near to sinus floor as feasible, a maximum of 2-3mm above the floor, and extending posteriorly from the region of 1st or 2nd tooth to anterior edge of maxillary sinus (Fig. 5).

During the procedure of performing osteotomies, it is crucial to use a gentle touch and brushing stroke to prevent any damage to the Schneiderian membrane. When carrying out the procedure in the presence of bicuspid teeth, extra care should be made to avoid causing any harm to them, and the osteotomy must be limited to 4 mm from distal aspect of tooth. The next step involves performing the superior horizontal osteotomy at height where augmentation is planned.

Finally, the posterior and anterior vertical osteotomies are formed to connect the inferior and superior osteotomies. The osteotomies must run parallel to the lateral wall of nose and anterior edge of maxillary buttress (or maxillary tuberosity), correspondingly (Fig. 6).

When the window is formed and the membrane is visible, any attached bone is taken out or rotated medially. If the bony window is rotated inwardly, it develops the floor of maxillary sinus. To elevate the Schneiderian membrane, the process should begin by lifting the margins with caution, and then progressively increase the elevation. Over-elevation of one area should be avoided as it can lead to perforation. The use of broad-based curettes or freers is recommended for membrane elevation. If possible, the membrane should be raised greater than “superior osteotomy”. It is essential to lift the Schneiderian membrane above the “superior osteotomy” to avoid undue strain on bone graft substance (Fig. 7).

Sinus membrane perforation is possible during the procedure, which can lead to complications (Fig. 8). Small perforations may not require treatment, but large ones should be patched with a collagen membrane or the procedure should be aborted. If the treatment is unsuccessful, it should not be repeated for at least four to six months. After raising the membrane, bone graft material is positioned anteriorly and inferiorly beneath it, making sure not to overpack it (Fig. 9). To account for volume loss, an extra 20% of bone graft material must be injected. After that, the mucoperiosteal flap is moved and sutured. Six months following the sinus lift treatment, implants can be inserted if there is enough alveolar bone to support them, and bone graft substance can be packed around them (Fig. 10). Patients should be prescribed postoperative antibiotics and decongestants for two weeks and advised to take sinus precautions such as not blowing their nose and coughing or sneezing by their open mouth.

The “**piezoelectric technology**” is an ultrasonic tool utilized for making osteotomies. This scheme has a higher power than traditional ultrasonic instruments, enabling the creation of osteotomies in thicker, compact cortical bone without cutting soft tissue. The benefit of this system is to decrease the hazard of perforating the sinus membrane. The piezoelectric tool may also help in the rise of the sinus membrane,

especially in robust areas of thin membranes and bone. This system has various inserts, from osteotomes to diamond-cutting inserts to those which aid to lift the sinus membrane. To elevate the membrane, the endosteum is separated from the bone, and the piezoelectric cavitation is subjected to hydropneumatic pressure of physiological saline solution [15].

A research study conducted by Vercellotti *et al.* [16] involved creating 21 bony window osteotomies in 15 patients using the Mectron Piezosurgery System with inserts that had a vibration from 60 to 210 mm and power exceeding 5W. Every osteotomy was carried out while being irrigated by a surgical system pump. After the flap was reflected, the bony window was formed by a piezoelectric scalpel, and then the membrane elevator tip was utilized, beginning at apex and moving to distal and mesial aspects. Attention was focused on sinus floor, where the membrane was raised to limit the harm of perforation. In this study, all sinus augmentations utilized autogenous bone grafts & platelet-rich plasma. The research found just one membrane perforation in 21 patients, yielding a success rate of 95 percent.

The **sinus intrusion osteotomy** is recommended for cases where there is a minimum 5-6mm of alveolar bone available. This method was demonstrated to increase bone height by 4 - 8 mm, but it is best suited for situations having enough bone for implant stabilization and minimal bone height is required [17]. In 1994, Summers [18] originally reported the method, which entails creating a crestal incision, bone prepping, and raising the sinus by a few mm. During the procedure, not only is bone compacted apically & the sinus elevated, but bone is also compacted laterally with progressively larger osteotomes (Fig. 12)

During the procedure described by Summers, crestal incision is created and implant drills are utilized to construct an osteotomy, leaving 1mm bone within sinus membrane and site. Then, sequential osteotomes of progressively increase in diameter are utilized to depth of the desired implant length, compacting bone apically & laterally, and elevating the sinus membrane. Once the required diameter and length are achieved, bone graft substance is put in prepared site's apical portion (Fig. 13). The implant

is located at the desired length, ensuring its stability. The main closure is then completed by adding a covers crew. The healing abutment can be connected to the implant and it can be exposed after 4 to 6 months of healing. Similarly, Komarnyckys and London [19] also observed a 95.3 percent success rate when performing this process in 16 patients and placing 43 implants. This study demonstrated mean bone increase of 3.25 mm throughout follow-up period of 9 - 47 months.

BMP (Bone Morphogenic Protein) is an option to bone graft material for enhancing the maxillary sinus, which is gaining popularity in the field. BMPs are altering growth factors which have bone-inductive characteristics, and 2 recombinant human proteins, rhBMP-7 and rhBMP-2, are currently existing [20]. BMPs offer several advantages over bone graft materials, including no morbidity at the harvest site, easy to use, increased soft-tissue healing, and the ability to be used in people who are not candidates for autogenous grafts . BMPs come in powder form and can be mixed with sterile water & applied to carrier during surgery. Collagen is the most commonly used carrier material for maxillary sinus augmentation, but it did not have mechanical strength and should be utilized in an area with borders in every dimensions. The preferred method for utilizing BMP-2 for maxillary sinus augmentation is lateral window approach, while there is limited evidence for its success with the sinus intrusion osteotomy technique. The procedure involves administering local anesthesia, making an incision, raising a full-thickness mucoperiosteal flap, creating bony osteotomies, and elevating the sinus membrane as earlier described. If a perforation in the membrane occurs, it is not mandatory to repair it when using BMP-2, but the surgeon may choose to do so. The BMP is provided in a lyophilized powder form and reconstituted using sterile water, following the manufacturer's instructions. The reconstituted BMP is loaded into sterile syringe and applied evenly onto the collagen sponge (Fig. 14). It takes at least 15 min to let the liquid settle so that the BMP adheres to the sponge before it is cut into 15mm strips and located among bony floor & membrane of sinus (Fig. 15). Chromic gut sutures are used to achieve primary closure.

A 1-week course of antibiotics is prescribed, and patient is advised to take sinus precautions. The

patient must be notified about the likelihood of significant swelling. A postoperative panoramic radiograph may be taken after 4 months to assess bone formation, and implants may be located six months prior to the process. Boyne and colleagues [21] conducted an early study that demonstrated the successful usage of rhBMP-2 in 12 patients who received the material in their maxillary sinus. The average bone height was 8.51 mm. The most common postoperative adverse impacts were facial swelling, pain, redness, and rhinitis.

Implants were inserted in the increased sinuses 12 weeks later and permitted to integrate for three months, in accordance with research comparing rhBMP-2 to anterior iliac crest grafts in 30 rabbits [22]. The rhBMP-2 group saw the largest mean vertical bone growth, and both groups' bone had comparable quality, according to the research. It is essential to highlight, however, that recombinant BMP is contraindicated in individuals with hypersensitivity to protein, carrier, or any other formulation substances. In addition, it shouldn't be applied to people who have active cancers or are receiving cancer treatment, to those who have tumours that have already grown or been removed, to skeletally immature people, to women who are pregnant, or to people who have active infections. Patients who do not demand to have a separate way to get bone graft material may find that BMP is a good alternative.

### Postoperative Instructions And Management

After surgery, it is important to provide patients with both printed and oral instructions regarding postoperative care. The patient should be advised to avoid consuming rough or hard foods which can damage sutures and cause wound dehiscence. Additionally, sinus precautions should be taken, which include avoiding any activity that can result in sudden pressure variations in sinus, like sneezing and nose blowing. If the patient needs to sneeze, they should do so by open mouth to direct pressure away from sinus. It is important to inform the patient about common postoperative symptoms, such as soreness, which is normal as well as expected for numerous days post-surgery. According to the postoperative instructions, it is common for few patients to go through bleeding from surgical incision for up to 24 hrs after the sinus lift surgery. However, this

bleeding may seem worse than it is because it can mix with saliva. The instructions advise that the patient should swallow the blood rather than expectorate it. If the bleeding becomes bothersome, it can be controlled by direct "wet gauze pressure". If the bleeding persists after two uses of gauze for every hour, or if the volume is concerning, the patient must notify the doctor. In addition, occasional skin bruising and swelling are normal after a sinus lift surgery.

### Complications & Its Management

"Schneiderian membrane perforation" is the most frequent complication of maxillary sinus lift surgery (Table 2). Recently, prospective observational uncontrolled research, 70 patients had a total of 212 implant loadings after undergoing 81 sinus lifts. 44% sinuses have been intraoperatively perforated, but they were healed, and the operation was finished without difficulties. 2% of sinuses experienced perforations so severe that the treatment had to be terminated. 33 % of perforations were found in sinuses where septae were visible on preoperative radiographs, and 52 percent of the sinuses with septae were perforated. 2 of the 36 holes were so serious that the surgery had to be terminated. Common treatments for sinus perforation involve doing nothing if the perforation is <2mm diameter and placing a slowly resorbing collagen membrane if the perforation is >2mm diameter. In one patient who presented with acute sinusitis following implant placement, postoperative complications involved extrusion of graft into the sinus cavity. Following medical as well as surgical remedies, the infection cleared up, and implants are restored. Persistent peri-implantitis and a peri-implant cyst were among the issues that arose later. Importantly, even though membrane perforations have been linked to postoperative complications like local infection, pain, and swelling, there is no correlation among intraoperative perforations & long-term implant survival. This research revealed an overall survival rate for 7 years of 95.5% for implants implanted in grafted sinuses. Noteworthy is the fact that five of the nine unsuccessful implants were implanted in heavy smokers. Instances of chronic infections resulting in severe sinusitis and the potential for graft extrusion, exposure, and/or failure are uncommon. Treatment is usually depending on the symptoms that are currently present and may include antibiotics, drainage of

surgical debridement, or a Caldwell-Luc technique [23-25].

**Table 2 : Common Complications Of Sinus Lift Surgery. (Stern A, Green J. Sinus Lift Procedures: An Overview Of Current Techniques. Dent Clin North Am 2012: 219-33, X.)**

COMPLICATION	TREATMENT
Graft exposure	Gentle daily normal saline irrigation, allow for creeping epithelialization
No graft present after maturation phase	Assess for possible etiology and retreat
Paresthesia CN V2 distribution immediately postop	Medrol dose pack if no contraindication
Facial swelling 2-3days post surgery	No treatment, normal postop
Severe facial ecchymosis appearing 1-3days postop	No treatment, normal postop
Facial pain and swelling, 1 week postop	Clinical examination, CT scan, consider antibiotics
Swelling , acute onset	Possible air-empysema; antibiotics, reinforce nasal precautions

## Discussion

The maxillary sinus lift is a widely accepted standard treatment for edentulous maxilla, having been in use for the last 30 years. A very frequent occurrence is pneumatization of maxillary sinus as a result of posterior maxillary tooth loss. Significant maxillary atrophy prohibits implant insertion in this location. Sinus augmentation was utilized for decades to prepare these areas for dental implant insertion. Transalveolar and lateral antrostomy procedures are the two most common methods for enhancing posterior maxillary VBH. The clinical and radiographic evaluations identify the most appropriate treatment strategy for every clinical condition. Both methods were demonstrated to have greater success rates. There are few absolute contraindications to the sinus lift procedure, with most being relative contraindications. However, practitioners must be well-versed in how to address them. Adequate preparation, knowledge, and experience make maxillary sinus

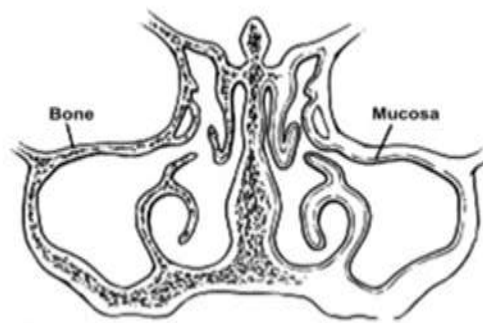
augmentation/elevation a beneficial process for patients, with expected outcome.

## References

1. Boyne PJ, James RA. Grafting of the maxillary sinus floor with autogenous marrow and bone. *J Oral Surg* 1980: 613–6.
2. Gosau M, Rink D, Driemel O, et al. Maxillary sinus anatomy: a cadaveric study with clinical implications. *Anat Rec (Hoboken)* 2009: 352–4.
3. Yanagisawa E, Yanagisawa K. Endoscopic view of the infraorbital nerve. *Ear Nose Throat J* 1999: 226–8.
4. Park YB, Jeon HS, Shim JS, et al. Analysis of the anatomy of the maxillary sinus septum using 3-dimensional computed tomography. *J Oral Maxillofac Surg* 2011: 1070–8.
5. Gudis DA, Cohen NA. Cilia dysfunction. *Otolaryngol Clin North Am* 2010: 461–72, vii.
6. Kan JY, Rungcharassaeng K, Lozada JL, et al. Effects of smoking on implant success in grafted maxillary sinuses. *J Prosthet Dent* 1999: 307–11.

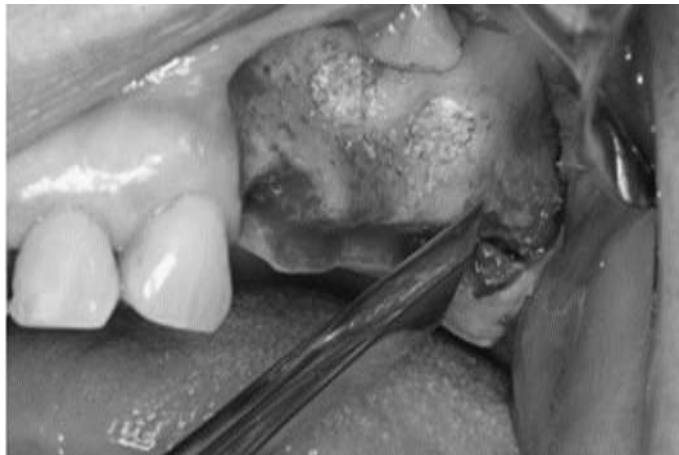
7. Levin L, Herzberg R, Dolev E, et al. Smoking and complications of onlay bone grafts and sinus lift operations. *Int J Oral Maxillofac Implants* 2004: 369–73.
8. Cote MT, Segelnick SL, Rastogi A, et al. New York State ear, nose, and throat specialists' views on pre-sinus lift referral. *J Periodontol* 2011: 227–33.
9. Block MS. *Color atlas of dental implant surgery*. 4<sup>th</sup> edition. Saunders, Elsevier Publishers. 2014, pp 5-488.
10. Block MS, Kent JN, Kallukaran FU, et al. Bone maintenance 5 to 10 years after sinus grafting. *J Oral Maxillofac Surg* 1998: 706-14.
11. Goldberg VM, Stevenson S. The biology of bone grafts. *Semin Arthroplasty* 1993: 58–63.
12. Misch CE. Maxillary sinus augmentation for endosteal implants: organized alternative treatment plans. *Int J Oral Implantol* 1987: 49–58.
13. Misch Craig. Maxillary Autogenous Bone Grafting. *Dent Clin North Am* 2011: 697-713.
14. Tatum H Jr. Maxillary and sinus implant reconstructions. *Dent Clin North Am* 1986: 207-29.
15. Raja SV. Management of the posterior maxilla sinus lift: review of techniques. *J Oral Maxillofac Surg* 2009: 1730–4.
16. Vercellotti T, De Paoli S, Nevins M. The piezoelectric bony window osteotomy and sinus membrane elevation: introduction of a new technique for simplification of sinus augmentation procedures. *Int J Periodontics Restorative Dent* 2001: 561-7.
17. Soltan M, Smiler D, Ghostine M, Prasad HS, Rohrer MD. Antral membrane elevation using a post graft: A crestal approach. *Gen Dent* 2012: e86–94.
18. Summers RB. A new concept in maxillary implant surgery: the osteotome technique. *Compend Contin Educ Dent* 1994: 152,154-6.
19. Komarnyckys OG, London RM. Osteotome single-stage dental implant placement with and without sinus elevation: a clinical report. *Int J Oral Maxillofac Implants* 1998: 799-804.
20. Reddi AH. Role of morphogenetic proteins in skeletal tissue engineering and regeneration. *Nat Biotechnol* 1998: 247-52.
21. Boyne PJ, Marx RE, Nevins M, et al. A feasibility study evaluating rhBMP-2/ absorbable collagen sponge for maxillary sinus floor augmentation. *Int J Periodontics Restorative Dent* 1997: 11-25.
22. Wada K, Niimi A, Watanabe K, et al. Maxillary sinus floor augmentation in rabbits: a comparative histologic histomorphogenetic study between rhBMP-2 and autogenous bone. *Int J Periodontics Restorative Dent* 2001: 252-63.
23. Schwartz-Arad D, Herzberg R, Dolev E. The prevalence of surgical complications of the sinus graft procedure and their impact on implant survival. *J Periodontol* 2004: 511–6.
24. Becker ST, Terheyden H, Steinriede A, et al. Prospective observation of 41 perforations of the Schneiderian membrane during sinus floor elevation. *Clin Oral Implants Res* 2008: 1285–9.
25. Vandeweghe S, De Ferrerre R, Tschakaloff A, et al. A wide-body implant as an alternative for sinus lift or bone grafting. *J Oral Maxillofac Surg* 2011: e67–74.

**Fig. 1. Coronal view of the ostiomeatal complex. The uncinete process lies in a sagittal plane. The maxillary sinus ostium drains into the infundibulum. (Stern A, Green J. Sinus lift procedures: an overview of current techniques. *Dent Clin North Am* : 219-33, x.)**

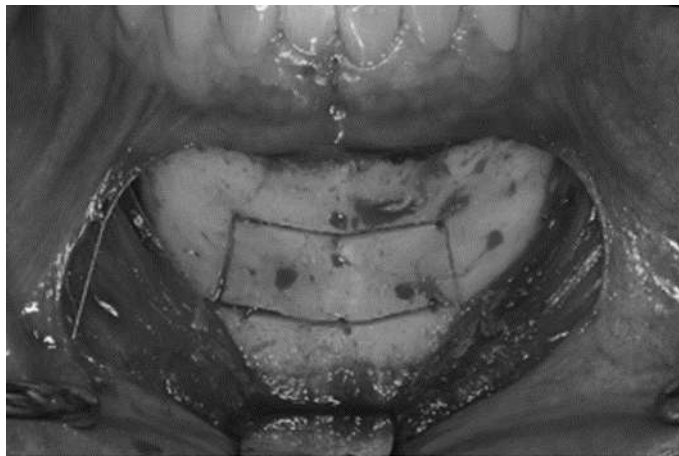




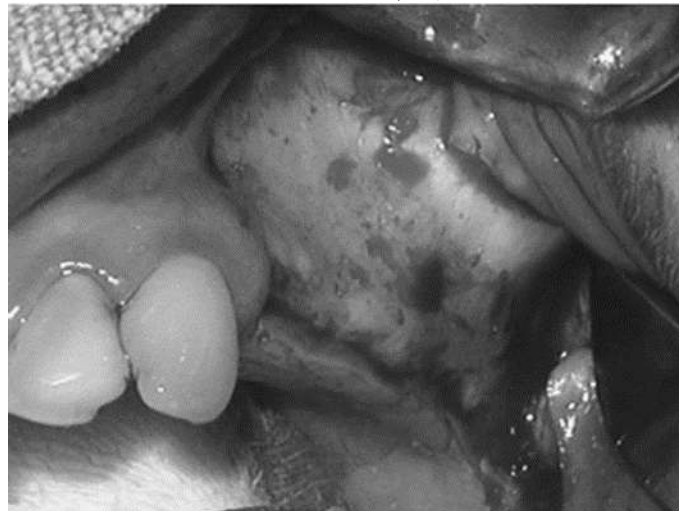**Fig. 2. Bone Harvesting.** (Stern A, Green J. Sinus lift procedures: an overview of current techniques. Dent Clin North Am 2012: 219-33, x.)



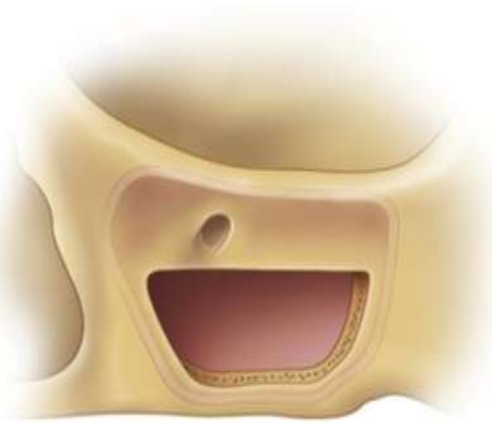**Fig. 3. The unicortical osteotomies form a rectangular outline in the symphysis.** (Stern A, Green J. Sinus lift procedures: an overview of current techniques. Dent Clin North Am 2012: 219-33, x.)



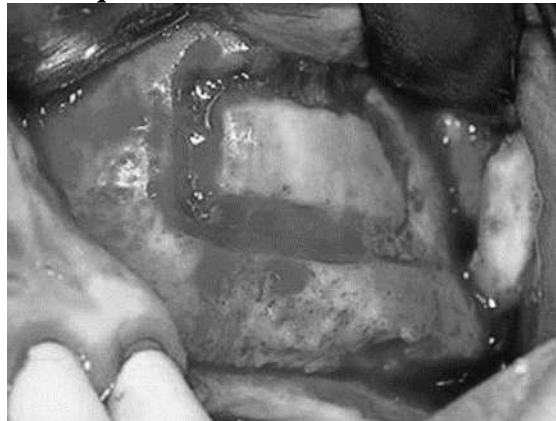
**Fig. 4. Incision and mucoperiosteal flap reflection.** (Stern A, Green J. Sinus lift procedures: an overview of current techniques. Dent Clin North Am 2012: 219-33, x.)



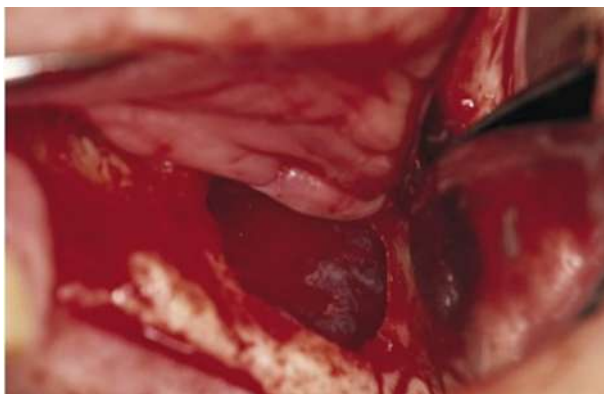
**Fig. 5. Diagram depicting the ideal location of sinus window preparation of the lateral maxillary wall. The inferior osteotomy should be approximately 1 mm above to or level with the floor of the sinus. The posterior osteotomy should be at the corner of the maxillary buttress. The anterior osteotomy should be adjacent to and parallel with the lateral wall of the nose, and the superior osteotomy should be at the height of the intended graft. (Stern A, Green J. Sinus lift procedures: an overview of current techniques. Dent Clin North Am 2012: 219-33, x.)**



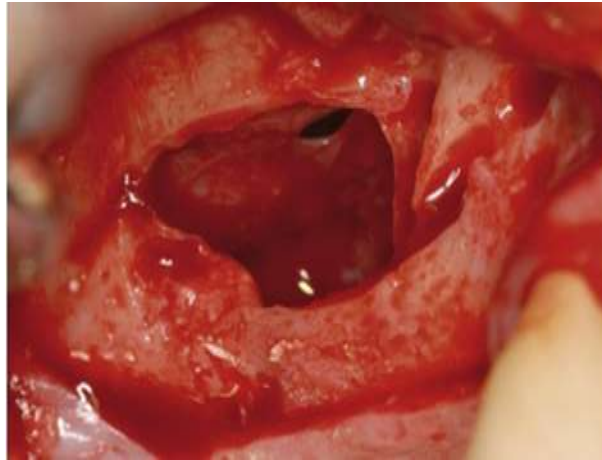
**Fig. 6. Complete quadrilateral osteotomy. (Stern A, Green J. Sinus lift procedures: an overview of current techniques. Dent Clin North Am 2012: 219-33, x.)**



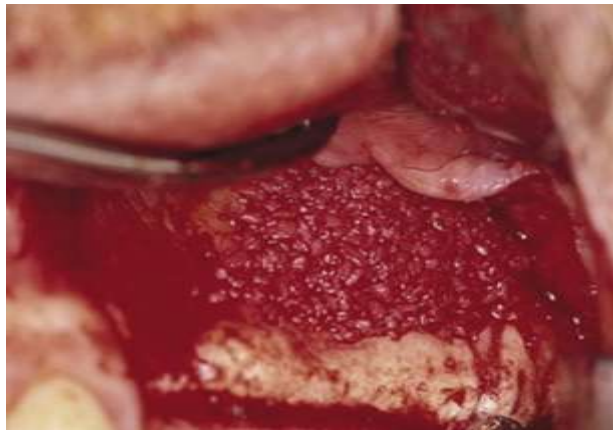
**Fig. 7. Membrane is carefully elevated and reflected medially into the sinus. (Stern A, Green J. Sinus lift procedures: an overview of current techniques. Dent Clin North Am 2012: 219-33, x.)**



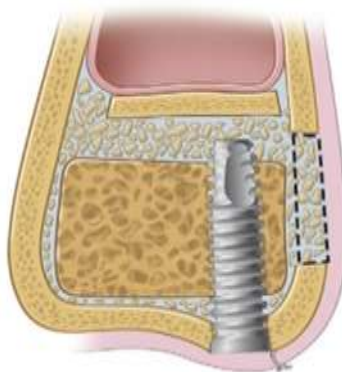
**Fig. 8.** Crestal incision is combined with anterior and posterior vertical release incisions to allow for exposure of lateral wall of the maxilla. Lateral wall of the sinus is rotated medially with membrane reflection. A small perforation is seen. (Stern A, Green J. Sinus lift procedures: an overview of current techniques. *Dent Clin North Am* 2012; 219-33, x.)



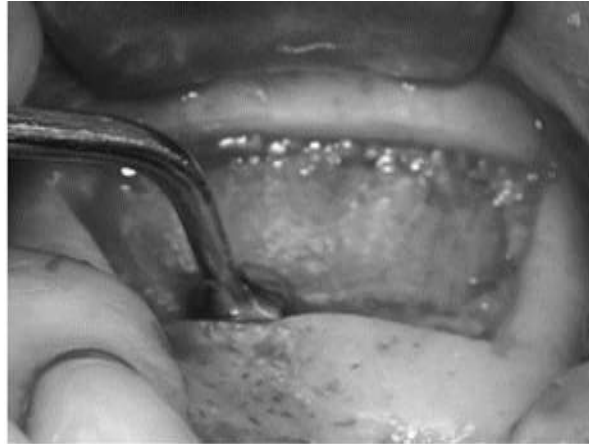**Fig. 9.** Bone graft composite is packed into the sinus site. After approximately 6 months, implants are placed followed by final restoration after another 6 months. (Stern A, Green J. Sinus lift procedures: an overview of current techniques. *Dent Clin North Am* 2012; 219-33, x.)



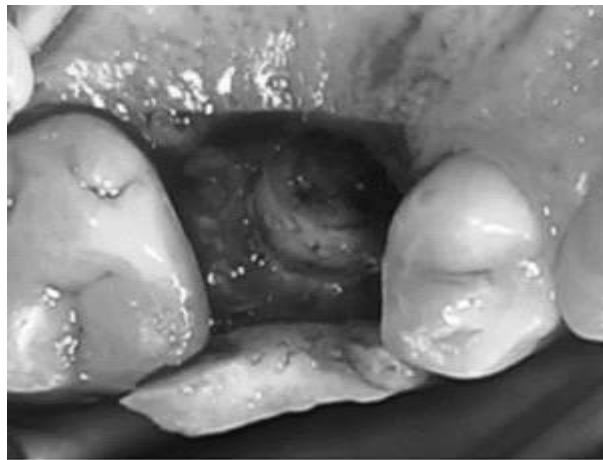**Fig. 10.** Diagram showing the lateral wall of the maxilla rotated medially into the sinus, which is optional. Bone graft material is placed into the sinus, either in particulate material or block form, to support the implant. Ideally, the block grafts should engage the superior surface of the implant. (Stern A, Green J. Sinus lift procedures: an overview of current techniques. *Dent Clin North Am* 2012; 219-33, x.)



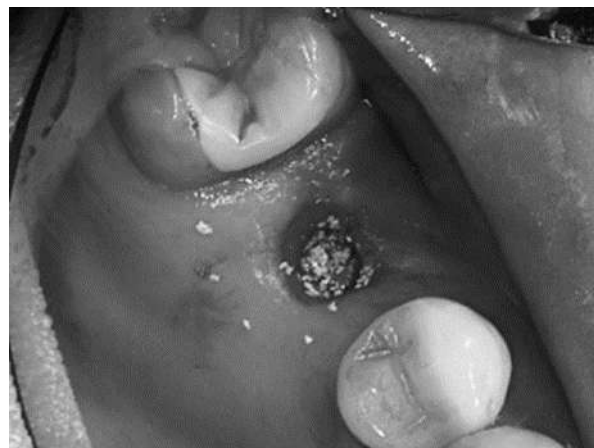**Fig. 11. Incision and mucoperiosteal flap reflection. (Stern A, Green J. Sinus lift procedures: an overview of current techniques. Dent Clin North Am 2012: 219-33, x.)**



**Fig. 12. Trephined bone core partially intruded into sinus cavity. (Stern A, Green J. Sinus lift procedures: an overview of current techniques. Dent Clin North Am 2012: 219-33, x.)**



**Fig. 13. Graft placed through implant receptor site into sinus cavity. (Stern A, Green J. Sinus lift procedures: an overview of current techniques. Dent Clin North Am 2012: 219-33, x.)**



**Fig. 14.** BMP is placed onto collagen sponge and the sponge is cut into five or six strips(Stern A, Green J. Sinus lift procedures: an overview of current techniques. Dent Clin North Am 2012: 219-33, x.)



**Fig. 15.** BMP impregnated collagen membrane is placed into the sinus with no membranes used to cover the sinus graft site. (Stern A, Green J. Sinus lift procedures: an overview of current techniques. Dent Clin North Am 2012: 219-33, x.)

