(International Print/Online Journal)

SJIF IMPACT FACTOR: 5.565
PUBMED-National Library of Medicine ID-101739732

ISSN (Print): 2209-2870
ISSN (Online): 2209-2862

International Journal of Medical Science and Current Research (IJMSCR)
Available online at: www.ijmscr.com
Volume 4, Issue 5, Page No: 537-540
September-October 2021

IJMSCR

Mucocutaneous histoplasmosis in an immunocompetent patient: a case report from non-endemic region in India

[1]Dr. Neha Gupta, [2]Dr. Pulkit Chaturvedi, [3]Dr. Vijay Paliwal, [4]Dr. Puneet Bhargava, [5]Dr. Deepak K Mathur

[1,2]Junior Resident, [3]Professor, [4,5]Senior Professor,
Department of Dermatology, SMS Medical College, Jaipur

***Corresponding Author:**
Dr. Neha Gupta
MBBS, Junior resident Department of Dermatology, SMS Medical College, Jaipur

Type of Publication: Case Report
Conflicts of Interest: Nil

Abstract

Rationale: Histoplasmosis is a disease caused by the fungus Histoplasma capsulatum.[2] Symptoms of this infection vary greatly, but the disease affects primarily the lungs.[3] Occasionally, other organs are affected; called disseminated histoplasmosis, Histoplasmosis is common among AIDS patients because of their suppressed immunity.[4] Pulmonary histoplasmosis and disseminated histoplasmosis involving the skin can be a major cause of morbidity and mortality in patients with advanced acquired immunodeficiency syndrome and in patients with lymphoma. [1]. [5]

Background: A 45-year-old male, farmer by occupation, presented with multiple, painful nodules and ulcers over the tongue, angle of mouth and lips and dysphagia for 6 months. He also had numerous painful papulo-nodular eruptions on head, trunk, and extremities for 5 months. The lesion on the palate started as a small swelling which gradually increased in size and then ulcerate.

Intervention and outcome: After appropriate analysis the patient was treated with Itraconazole because of its easy availability and lesser cost.

Keywords: Antifungal, immunocompetent, lymphoma

INTRODUCTION

Histoplasmosis/Darling's disease is a deep mycotic infection caused by two species of dimorphic saprophytic fungi Histoplasma capsulatum; Histoplasma capsulatum var. capsulatum found in the Americas and the tropics; also known as small form histoplasmosis, and Histoplasma capsulatum var. Duboisii prevalent in Africa, also known as large form histoplasmosis/African histoplasmosis.[1] In India, endemic in eastern part of India particularly West Bengal [2] and in southern India. [3] Further reports of histoplasmosis in nonendemic regions are very rare. [4]

The spores are found in soil, contaminated with chicken feathers and droppings of bird like starling and bat. [1] Pulmonary histoplasmosis and disseminated histoplasmosis involving the skin can be a major cause of morbidity and mortality in patients with advanced acquired immunodeficiency syndrome and in patients with lymphoma. [1] Although histoplasmosis occurs most commonly in immunocompromised patients, [1] only a few case reports of this disease in immunocompetent hosts. [5] Due to rarity of this disease in immunocompetent individuals and in non-endemic region, we report a case of disseminated mucocutaneous histoplasmosis

in an immunocompetent individual from a nonendemic region of North India.

Case Report

Chief complaints-

1. Multiple, painful nodules and ulcers over the tongue, angle of mouth and lips

2. Dysphagia for 6 months.

3. Painful papulo-nodular eruptions on head, trunk, and extremities for 5 months.

4. Low-grade fever, weight loss, productive cough and shortness of breath for last one month.

Personal history-

Occupation- Farmer

Built-poor

Bowel-Regular

Appetite-Normal

Sleep-Regular

Bladder-Regular

Nutritional status -Undernourished

H/0 Present illness-

O/E-

Cervical lymphadenopathy.

Cutaneous examination - multiple, well defined, discrete, skin-coloured to hyperpigmented, umbilicated, indurated, papules and nodules with hemorrhagic crust in centre or purulent discharge from some lesion, size ranging from 2 mm to 1.5 × 1 cm, distribution- over the face, neck, chest, abdomen, back, and both extremities. [Figures1]

Oral mucosa- multiple, well defined, discrete to confluent, erythematous, tender papulonodular lesions, sized 3 mm to 1.5×1.5 cm, over the dorsum of tongue and angle of mouth.

Buccal mucosa- Multiple, well defined, erosions with haemorrhage over the hard palate and inner surface of lips. [Figure 2].

Other systemic examinations were unremarkable.

Routine laboratory investigations

Hb-5.3gm/dl

RBCs -2.51× 10^6 / mm3.

Leukocytosis -25,900 and thrombocytosis - 6.66 lakh/mm3

ESR - 50 mm in 1st hour.

Other laboratory investigations including HIV serology were unremarkable. Skiagram of chest was unremarkable except bilateral hilar lymphadenopathy.

Histopathology revealed epidermal necrosis and acute inflammatory infiltrate in dermis with fungus histoplasmosis. [Figure 3,4] Dermis was filled with multiple tiny intracellular round yeasts surrounded by a halo on PAS and GMS staining.

Tissue culture grew cottony white colonies suggestive of Histoplasma capsulatum. A test for dimorphism was conclusive for histoplasmosis.

Treatment Given- Itraconazole 100 mg twice daily for 8 weeks with topical application of clotrimazole over mucosal lesions.

Discussion

Disseminated mucocutaneous histoplasmosis is rare in immunocompetent host and from a nonendemic region. This patient was a resident of a non-endemic region of North India but frequently travelled to different parts of country. [1] We believe that our patient contracted the disease via inhalation of conidia from contaminated soil. [1]

Inhalation of microconidia is the main mode of transmission, after inhalation these microconidia, small enough to reach the terminal bronchioles and alveoli, they translocated to local draining lymph nodes.[6] and spread throughout the reticulo-endothelial system by blood [1] Primary pulmonary histoplasmosis in the vast majority (~ 90%), is asymptomatic or subclinical. [1] Symptomatic hosts with primary pulmonary histoplasmosis often present with nonspecific self-limiting symptoms of fever, chest pain and cough.

Immunocompetent hosts are able to control and limit infections with development of cell-mediated immunity. However, hosts with defective CMI, including patients with malignancies, organ transplants, AIDS and patients on chemotherapeutic and immunosuppressants, are at risk of developing progressive disseminated histoplasmosis involving the reticuloendothelial system, including the liver, spleen,

Volume 4, Issue 5; September-October 2021; Page No 537-540

kidney, lymph nodes, bone marrow and mucocutaneous tissues. [1]

Disseminated mucocutaneous histoplasmosis in an immunocompetent is rarely described around the world. [7] We report a case of acute disseminated histoplasmosis in an immunocompetent host. Frequently, in such cases, oral lesions, such as ulcers, erythematous or vegetative indurated nodules or wart-like growths, mainly over the palate, gingiva, and oropharynx are initial manifestations. [1][7] The common cutaneous lesions include papules, nodules and ulcers, and rarely granulomas, abscesses, fistulae, scars and pigmentary changes.[1] The noduloulcerative oral lesions may mimic squamous cell carcinoma, lymphoma, and other systemic mycoses like cryptococcosis.

Fungal culture remains the gold standard for diagnosis though it can often be negative. [6] Body fluids like, sputum, peripheral blood, bone marrow, tissue specimens and lymph node aspiration sample can be used for culture,[1] The culture yield white to light tan colonies on SDA culture.

Routine histopathology shows the budding yeast forms within histiocytes as a clear space or artifactual "halo" due to the retraction of the basophilic fungal cell cytoplasm from the poorly stained cell wall, confirmed by Gomory- methenamine silver stain and PAS positivity,[6] and also by serology for histoplasma antigen in body fluids by immunodiffusion and complement fixation test, but not easily available and expensive hence not widely used. [6]

Conclusion

Disseminated mucocutaneous histoplasmosis is not rare as it is assumed in non-endemic and immunocompetent host. Treatment of histoplasmosis in present era of advance antifungals like Itraconazole, terbinafine and voriconazole is easy. We used Itraconazole because of its easy availability and lesser cost.

Abbreviations:

AIDS- acquired immunodeficiency disease
PAS- periodic acid shiff
CMI- cell mediated immunity
GMS- Gomory-methenamine silver
SDA- Sabouraud's dextrose agar

Legends

Figure 1 - showed multiple skin coloured papule and nodules with central umblication involving face, truck and extremities.

Figure 2- shows multiple erythematous papulo-nodular eruptions over tongue with erosion over labial mucosa

Figure 3 - PAS stain for fungus

References

1. Roderick J. Hay1 and H. Ruth Ashbee 2 "systemic mycosis" Rooks textbook of dermatology 9th edition. 2016 ; 32; 32.82
2. Sanyal M, Thammaya Skin sensitivity to histoplasmin in Calcutta and its neighbourhood. Indian J Dermatol Venereol Lepreology. 1980; 46:94–8.
3. Nair SP, Vijayadharan M, Vincent M. Primaty cutaneous histoplasmosis. Indian J Dermatol Venereol Leprol. 2000; 66:151–3. [PubMed]
4. Taylor GD, Fanning EA, Ferguson JP. Disseminated histoplasmosis in a Nonendemic area. Can Med Assoc J. 1985; 33:763–5. [PMC free article] [PubMed]
5. Alcure ML, Di Hipólito Júnior O, Almeida OP, Bonilha H, Lopes MA. Oral histoplasmosis in an HIV-negative patient. Oral Surg Oral Med Oral Pathol Oral Radiol Endod. 2006; 101:33–6. [PubMed]
6. Kriplani DM, Kante KA, Maniar JK, Khubchandani SR. 6 Histoplasmosis in an immunocompetent host: a rare case report. Int J Res Med Sci 2017; 5:1148-50.
7. Disseminated Cutaneous Histoplasmosis in an Immunocompetent Adult Manoj Harnalikar, Vidya Kharkar, And Uday Khopkar Indian J Dermatol. 2012 May-Jun; 57(3): 206–209. doi: 10.4103/0019-5154.96194 PMCID: PMC3371525.

Volume 4, Issue 5; September-October 2021; Page No 537-540

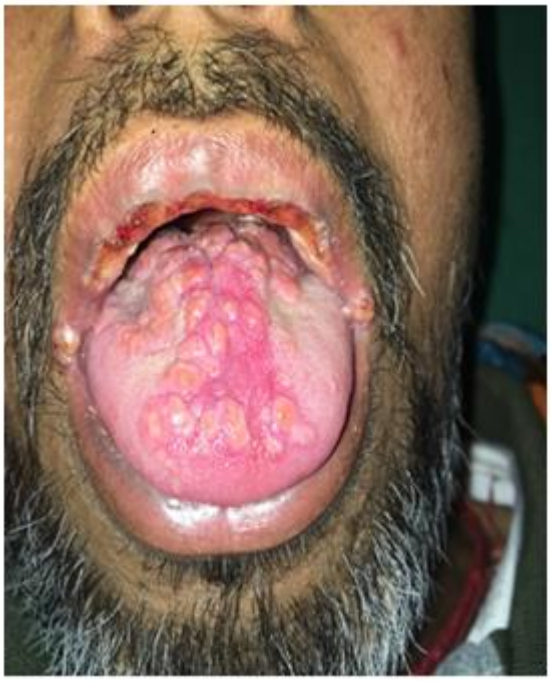

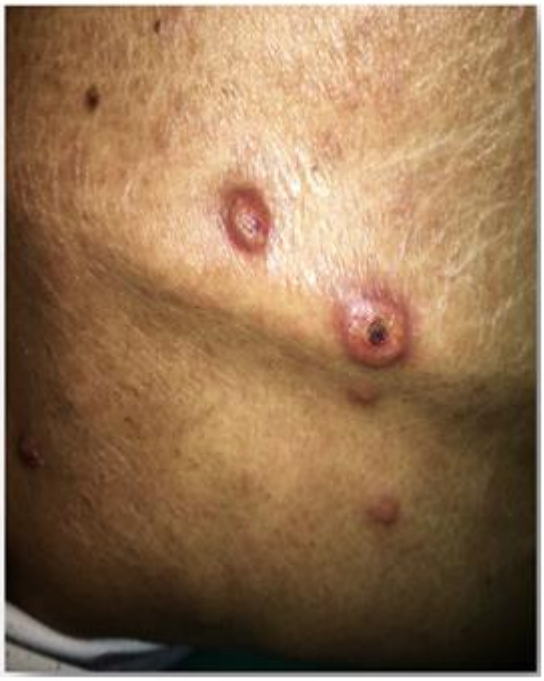

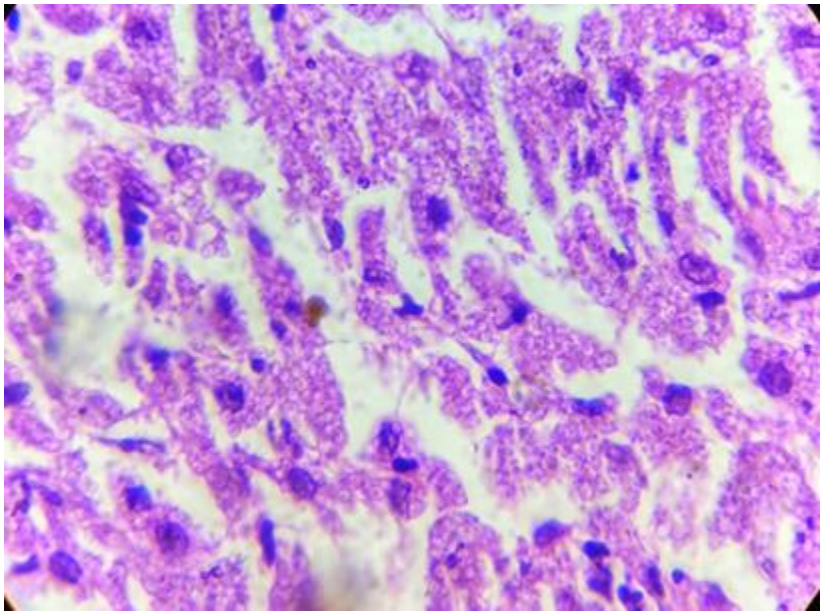

Volume 4, Issue 5; September-October 2021; Page No 537-540