(International Print/Online Journal)

SJIF IMPACT FACTOR: 5.565
PUBMED-National Library of Medicine ID-101739732

ISSN (Print): 2209-2870
ISSN (Online): 2209-2862

International Journal of Medical Science and Current Research (IJMSCR)
Available online at: www.ijmscr.com
Volume4, Issue 2, Page No: 889-892
March-April 2021

Snake Bite as Inciting Event of Guillain Barre Syndrome, a Case Report and Literature Review

Dr. Sithara Subair, MBBS[1], Dr. H Anuradha, MD[2], Dr. P Paranthaman, MD[3]
[1] Junior Resident, [2] Senior Assistant professor, [3] Professor and Head
Dept of General Medicine, Govt Kilpauk medical college and hospital

***Corresponding Author:**
Dr. Sithara Subair
MBBS, Junior Resident, Dept of General medicine, Govt Kilpauk medical college and hospital, Chennai

Type of Publication: Case Report
Conflicts of Interest: Nil

ABSTRACT

Background: Guillain Barre syndrome is an eponym for a group of autoimmune neuropathies, usually incited by respiratory or gastrointestinal infections. Here we describe a patient who presented with GBS after a snake bite.

Case information: 40 year old male presented 12 days after bite of an unidentified snake, with history of one day weakness of lower limbs, ascending to upper limbs within same day, with no sensory or autonomic involvement, and no respiratory distress. On examination he had hypotonia and areflexia of all four limbs. Nerve conduction and CSF studies confirmed diagnosis of GBS. He was started on IVIG and iv steroids, and improved very well within 15 days of onset.

Conclusion: Although a rare complication, we should cautiously monitor patients after a snake bite, before quadriparesis, bulbar weakness or respiratory distress sets in and educate them appropriately as well.

Keywords: NIL

INTRODUCTION

Although annual snake bites prevalance is around 5.4 million according to World Health Organization[7], only a handful of them are followed by Guillain Barre syndrome. Here we describe a patient who presented 12 days after a snake bite with ascending quadriparesis and areflexia.

CASE NARRATIVE

A 40 year old gentleman, cattle fodder dealer by profession, presented to our casualty with a one day history of acute onset fatigue and weakness of both lower limbs, which progressed to involve both upper limbs within a duration of few hours. He was unable to sit up or even roll over on bed. No sensory disturbance was reported by the patient, as well as no bowel bladder involvement. No complaints of diplopia, drooling or weakness of face. No history of loss of consciousness or seizures. No history of fall or trauma to neck. He had no history of fever, loose stools, sore throat, or any other infections in the previous few weeks.

He alleged history of bite by a green garden snake around 12 days prior to onset of weakness; he remained asymptomatic through the interval and had sought treatment at a local practitioner, no anti snake venom was given. The snake wasn't caught and we were unable to identify the species.

He had no history of recent vaccinations or any other drug intake. He is not a smoker or alcoholic and had no other comorbid conditions.

On examination at admission his vitals were stable, pulse rate of 86/min, blood pressure of 120/70 mmHg, with room air saturation 99%,no tachypnea, a single breath count of 28, and capillary blood glucose

140mg/dl. He was conscious and oriented to time, place, person. There was global hypotonia and areflexia, with MRC strength grading of 1/5 of all limbs proximally and 2/5 distally. He had poor neck holding, but had no respiratory distress. Peripheral nerves examination showed no thickening or nodules. No sensory involvement on examination, no nystagmus, dysarthria and no cranial nerve affected. We investigated into causes of acute flaccid quadriparesis with no sensory or autonomic involvement.

Routine investigations showed normal electrolytes ruling out hypokalemia. Nerve conduction study was done which showed reduced compound muscle action potential in both ulnar and median nerves bilaterally, reduced conduction velocity in all motor nerves with no conduction blocks, sensory nerve action potential reduced in left ulnar nerve, and impersistent F waves. CSF analysis showed a protein of 62mg/dl, with an acellular smear. A diagnosis of Guillian Barre syndrome was made, probably incited by the snake bite.

Patient's general condition remained stable, he did not require any ventilatory support throughout his stay.

Intravenous immunoglobulin was started on day 3 of admission, at a dose of 2g/kg divided over 5 days, along with injection methyl prednisolone at 1mg/kg. Limb and chest physiotherapy was also also initiated at the same time. Patient vitals were carefully monitored for any signs of respiratory distress.

Patient's limb power started improving and by day 10 of admission he had gained a power of 3/5 in upper limb muscles and 4/5 in lower limbs, neck holding also improved. He was able to walk around slowly, and was discharged on day 17 with all limbs power 4+/5, and asked to follow up with neurologist and physiotherapist.

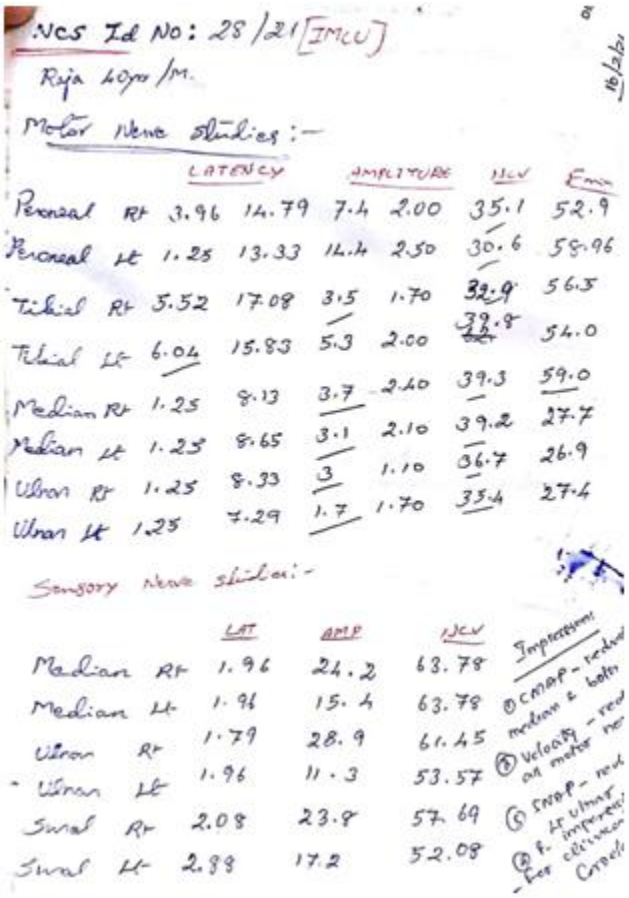

NCS Id No: 28/21 [IMCU]

Raja 40yr/M.

Motor Nerve studies:-

		LATENCY		AMPLITUDE		NCV	F-wave
Peroneal	Rt	3.96	14.79	7.4	2.00	35.1	52.9
Peroneal	Lt	1.25	13.33	14.4	2.50	30.6	58.96
Tibial	Rt	5.52	17.08	3.5	1.70	32.9	56.5
Tibial	Lt	6.04	15.83	5.3	2.00	39.8	54.0
Median	Rt	1.25	8.13	3.7	2.40	39.3	59.0
Median	Lt	1.25	8.65	3.1	2.10	39.2	27.7
Ulnar	Rt	1.25	8.33	3	1.10	36.7	26.9
Ulnar	Lt	1.25	7.29	1.7	1.70	35.4	27.4

Sensory Nerve studies:-

		LAT	AMP	NCV
Median	Rt	1.96	24.2	63.78
Median	Lt	1.96	15.4	63.78
Ulnar	Rt	1.79	28.9	61.45
Ulnar	Lt	1.96	11.3	53.57
Sural	Rt	2.08	23.8	57.69
Sural	Lt	2.88	17.2	52.08

Impression:
① CMAP - reduced median & both
② Velocity - red on motor ne
③ SNAP - red
④ Lt ulnar impressi
⑤ F. for elicitation
Crosd

Nerve conduction study on day 2 of admission

Volume 4, Issue 2; March-April 2021; Page No 889-892

Total WBC count	10,000/microlitre
Differential	76% neutrophils, 15% lymphocytes
RBC count	4.41 million per microlitre
Platelets	3.75 lacs per microlitre
Blood sugar	155mg/dl
Serum urea	1.0 mg/dl
Serum creatinine	44 mg/dl
Serum sodium	133 MEQ/L
Serum potassium	4.6 MEQ/L
Serum bilirubin	0.6 mg/dl
SGOT/SGPT	25/31 U/L
ALP	64 U/L
Serum total protein	6.8g/dl
Serum albumin	3.5g/dl

Routine investigations at admission

DISCUSSION

Guillian Barre syndrome is a constellation of acute immune mediated polyneuropathies, with several variant forms. Most often presents as acute monophasic illness with flaccid ascending areflexic paralysis, usually preceded by respiratory or gastrointestinal infection. Few reports have GBS associated with surgery, cancer and vaccines.[1] Only five case reports, to the best of our knowledge, have been reported that suggest an association of a snake bite with GBS. [2-6].

The first case report was in 1996, by Chuang et al[2] from Taiwan, which described a patient with progressive quadriparesis, autonomic dysfunction and cerebrospinal fluid cytoalbuminologic dissociation, which came on four weeks following bite of Formosan krait (*Bungarus multicinctus)*. Patient improved with steroids, plasma exchange and rehabilitation.

Second case was by Srivasatava et al[3] who reported a patient with bilateral upper limb paraesthesias and quadriparesis almost 35 days after snake bite, but the species could not be identified. Patient improved with plasma exchange. Nerve conduction showed motor and sensory neuropathy suggesting demyelination with secondary axonal injury,

Both the above cases received anti snake venom immediately after the bite.

Third case was by Neil et al[4] where patient presented with paraesthesia and quadriparesis 12 days after bite of *Vipera aspis.* They demonstrated cross reactivity between venom proteins and neuronal GM2 gangliosides, postulating an immunological molecular mimicry mechanism rather than direct venom toxicity.

Fourth case was from Brazil by Neto et al[5]. Patient presented 2 weeks after bite of rattlesnake (*Crotalus sp)* with quadriparesis and areflexia. Patient improved on IVIG and rehabilitation. He was also given anti venom after bite.

Fifth case was by Hameed et al[6]. Patient was bitten by a yellow bellied sea snake (*Hydrophis platarus)*, and presented 6 weeks later with generalised weakness and breathing difficulty. Nerve conduction study showed acute motor axonal neuropathy variant of GBS. He was started on plasma exchange and completely recovered by 4 months.

Volume 4, Issue 2; March-April 2021; Page No 889-892

It was not possible to identify the snake species in our case, but a temporal association suggests it as a likely cause of GBS. Also it suggests an immunological basis for the weakness and not a direct toxicity of venom. He responded very well to IVIG and steroids, and was able to walk within day 15 of onset.

CONCLUSION

GBS following a snake bite is a rare complication, probably due to underreporting of cases, and almost all the reported patients have recovered well with standard treatments. Patients should be educated and monitored for signs of weakness for few weeks after snake bite, so that they may be caught before life threatening events set in.

ACKNOWLEDGEMENT

The authors acknowledge the department of Internal medicine and Neurology for their valuable inputs and immense support.

REFERENCES

1. Guillain-Barré syndrome. Donofrio PD. Continuum (Minneap Minn) 2017;23:1295–1309. [PubMed] [Google Scholar] [Ref list]
2. Guillain-Barre syndrome: an unusual complication after snake bite. Chuang TY, Lin SW, Chan RC. https://www.ncbi.nlm.nih.gov/pubmed/8670005. Arch Phys Med Rehabil. 1996;77:729–731. [PubMed] [Google Scholar] [Ref list]
3. Guillain-Barre syndrome following snake bite: An unusual complication. Srivastava A, Taly AB, Gupta A, Moin A, Murali T. Ann Indian Acad Neurol. 2010;13:67.[PMC free article] [PubMed] [Google Scholar][Ref list]
4. Guillain-Barre syndrome: First description of a snake envenomation aetiology. Neil J, Choumet V, Le Coupanec A, d'Alayer J, Demeret S, Musset L. J Neuroimmunol. 2012;18:72–77. [PubMed] [Google Scholar][Ref list]
5. Guillain-Barré syndrome after a snakebite: case report and literature review. Neto EGC, Macedo MJA, Silva FV, Foseca AJ, Fonseca ARR. https://pdfs.semanticscholar.org/3611/5256c38a2be8a84c211d2f3e19017ed9fe17.pdf Revista brasileira de neurologia e psiquiatria. 2014;18:253–257. [Google Scholar] [Ref list]
6. Hameed S, Memon M, Khan S. Guillain-Barre Syndrome Following a Snakebite: A Case Report and Review of Literature. Cureus. 2019 Jul 30;11(7):e5278. doi: 10.7759/cureus.5278. PMID: 31576270; PMCID: PMC6764639.
7. Prevalence of snakebite envenoming. [Jul;2019];World Health Organization. (2019. https://www.who.int/snakebites/epidemiology/en/ 2019 [Ref list]