(International Print/Online Journal)

SJIF IMPACT FACTOR: 5.565
PUBMED-National Library of Medicine ID-101739732

ISSN (Print): 2209-2870
ISSN (Online): 2209-2862

International Journal of Medical Science and Current Research (IJMSCR)
Available online at: www.ijmscr.com
Volume4, Issue 2, Page No: 885-888
March-April 2021

A Rare Case Of Primary Multiple Tuberculous Splenic Abscess in an Young Immunocompetent Patient

[1]Dr Ramchandar Ramanan*, [2]Dr Ravishankar Goldar
[1]DNB General Surgery, [2]M.B.B.S, M.D Pathology Medical Officer
Indira Gandhi Government General Hospital and Post Graduate Institute, Puducherry, India

***Corresponding Author:**
Dr Ramchandar Ramanan
Indira Gandhi Government General Hospital and Post Graduate Institute, Puducherry, India

Type of Publication: Case Report
Conflicts of Interest: Nil

ABSTRACT

Splenic abscess is a rarer entity in immunocompetent individuals. Splenic abscess due to tuberculosis in an immunocompetent individual is extremely rare. In our case study a 20 yr immunocompetent male moderately built presented with complaints of abdominal pain over left hypochondrium for about 1 month duration, low grade fever and nausea.Computed tomography(CT) of abdomen revealed multiple non enhancing, hypodense, space occupying lesion suggestive of abscesses without any evidence of ascites. No primary focus of infection was detected. Patient underwent open emergency exploratory laprotomy with splenectomy. Histopathological examination of the specimen showed epithelioid granulomas with Langerhans giant cells and stained acid fast bacilli positive with Ziehl-Neelson (ZN) staining. The patient was diagnosed as primary multiple tuberculous splenic abscess and started on antitubercular therapy for six months. The patient had no complications in one year of followup period..

Keywords: Multiple splenic abscess, tuberculosis, splenectomy, immunocompetent

INTRODUCTION

Tuberculosis is one of the top ten leading causes of death worldwide. Tuberculosis affects all countries and age groups. In 2019 according to global TB statistics an estimated 10.0 million new cases have been reported. India accounts for about a quarter of global TB burden. Extra pulmonary tuberculosis can occur alone or together with pulmonary TB. Of the 8.6 million new cases of TB notified to world health organization in 2013, 15% were cases of extra pulmonary tuberculosis. The incidence of splenic TB is still rarer ranging from 0.14% -0.7%.

CASE REPORT

A 20 yr old moderately build presented to our out patient department with complaints of abdominal pain over the left hypochondrium for about 1 month of duration, low grade fever and nausea. The patient denied history of cough, hemoptysis, and shortness of breath, chills and rigor, night sweats or any loss of weight and no histroy of trauma in recent past. No contact history of TB was present. On examination abdomen was soft but tenderness was present in the left hypochondrium, spleen was palpable 3 cm along its long axis, tender and firm in consistency, smooth surface and movement with respiration was present. No rub or bruit heard and no other organs were palpable. His biochemical parameters were within normal limits. He tested negative for hepatitis b, c virus and human immunodeficiency virus by enzyme-linked immunosorbent assay. Chest xray was normal. Sputum AFB was negative.

Ultrasonography abdomen showed several hypoechoic foci in the spleen. Computed tomography of abdomen revealed multiple nonenhancing, hypodense, space occupying lesion suggestive of

abscesses without any evidence of ascites. Patient underwent open emergency exploratory laprotomy with splenectomy.Intra operative findings revealed multiloculted splenic abscess as shown in **figure 1**. The cut section of gross specimen shows abscesses of spleen as seen in **figure 2**. Histopathological examination of the specimen showed epithelioid granulomas with Langerhans giant cells as seen in **figure 3** and stained acid fast bacilli positive with Ziehl-Neelson (ZN) staining as seen in **figure 4** .The patient was diagnosed as primary multiple tuberculous splenic abscess and started on antitubercular therapy for six months. Post operative period was uneventful. Post operative pneumococcal vaccination given .The patient had no complications in one year of follow up period

DISCUSSION

The incidence of splenic abscess is very low ranging from 0.14% - 0.7% (incidence found during autopsy) [1]. The incidence of splenic abscess is increasingly growing in number due to immunodeficiency disorder. Even though extrapulmonary tuberculosis accounts for more than 50% of overall tuberculosis in an immunocompromised patient, 15 -20 % of extrapulmonary tuberculosis tend to occur in immunocompetent individuals [2]. Abdominal TB comprising of entire gastrointestinal tract accounts for only 3% of extra pulmonary TB in an immunocompetent patients. Splenic TB is usually seen as a part of disseminated TB in immunocompromised individuals with incidence of 4% - 7.8% and most common pathway of spread being haematognous route (49 % - 68%) and primary splenic TB is extremely rare in immunocompetent individuals [3]. Most common organism causing splenic abcess includes gram negative organism of which klebsiella being most commonly isolated.

Pyogenic splenic abscess are usually unilocular. Medical management alone is ineffective with mortality rate of 80%. Percutaneous drainage has a disadvantage of 30 % recurrence rate. Combined medical management with percutaneous drainage is found to be adequate in cases unilocular, solitary abcess with well defined homogenous wall. Contraindications for drainage include multiple abscess, sepatations and anatomically inaccessible due to dense adhesions. 90% of multiloculated splenic abscess are most commonly seen due to fungal etiology in immunocompromised individuals [4]. Mycobacterium involvement of spleen is extremely rare in immunocompetent patients.

The probable best explanation for splenic TB is that the red pulp of spleen lacks phagocytic activity and serves as shell for the entrapped slow growing mycobacteria to escape from the reticuloendothelial system of spleen [5]. The characteristic CT appearance of Splenic TB includes solitayr or multiple hypodense nodular areas. The differential diagnosis includes infarction, hamartoma, abscess, sickle cell disease, sarcoidosis, hemangioma and lymphomas. Splenic TB has bee classified into two forms based on the radiological features, micronodular if smaller than 10mm and macronodular if larger than 10mm [6]. Micronodular splenic TB is most common and seen in cases of disseminated TB whereas Macronodular splenic TB is rare and can present as multiple large nodules or multiple abscesses [7]. The diagnosis of extra pulmonary TB is hindered especially in cases of Splenic TB since isolating and demonstrating the mycoabcterium from specific site of involvement is necessary for the definitive diagnosis which is difficult and challenging as it requires an invasive diagnostic procedure most of the time. Surgery is indicated in cases of rupture spleen, large multiloculated abscesses and failure to medications; however standard antitubercular therapy should be continued post operatively.

CONCLUSION

The above case is presented due to its rarity of occurence of primary multiple splenic abscesses in a young immunocompetent individual. The diagnosis needs a histopathological confirmation as diagnosis by microbiological or laboratory confirmation is very difficult. Hence splenic TB should be kept in mind as differential diagnosis in patients with abdominal pain, fever of unknown origin and splenomegaly, as early diagnosis of splenic TB decreases overall the mortality and morbidity in the patient.

REFERENCES

1. Agarwala S, Bhatnagar V, Mitra DK, et al. Primary tubercular abscess of the spleen. J Pediatr Surg 1992; 27:1580–1.

Volume 4, Issue 2; March-April 2021; Page No 885-888

2. Sharma SK, Mohan A. Extrapulmonary tuberculosis. Indian J Med Res 2004; 120:316-53.
3. Chandra S, Srivastava DN, Gandhi D. Splenic tuberculosis: An unusual sonographic presentation. Int J Clin Pract 1999; 53:318-9.
4. Chang KC, Chuah SK, Changchien CS, et al. Clinical characteristics and prognostic factors of splenic abscess: a review of 67 cases in a single medical center of Taiwan. World J Gastroenterol 2006; 12:460–4.
5. Singh TP, Gupta AK, Nigam A. Tubercular splenic abscess. J Indian Acad Clin Med 2011;12:59-60
6. Lim J, Yu JS, Hong SW, Chung JJ, Kim JH, Kim KW. A case of mass forming splenic tuberculosis: MRI findings with emphasis of diffusion weighted imaging characteristics. J Korean Med Sci 2011; 26:457-60.
7. Dede F, Doğan E, Demir M, et al. Unusual presentation of tuberculosis as a splenic mass. Tohoku J Exp Med 2006; 210:79-82.

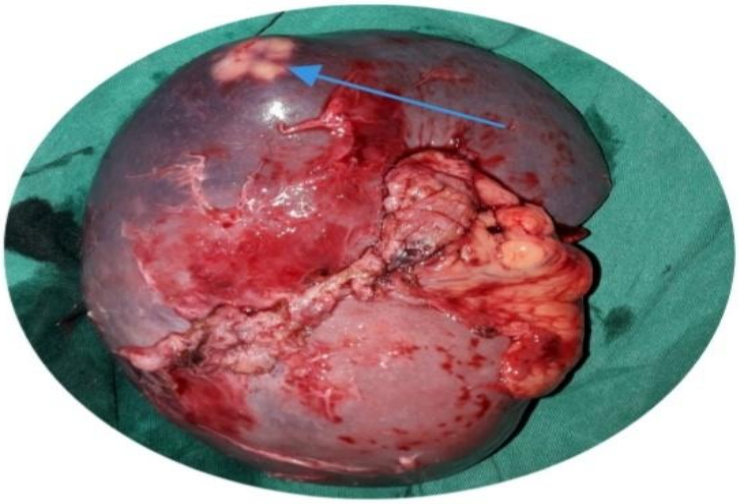

Fig 1 showing abscess of spleen with nodular surface.

Fig 2 Cut section of gross specimen of spleen showing abscesses.

Volume 4, Issue 2; March-April 2021; Page No 885-888

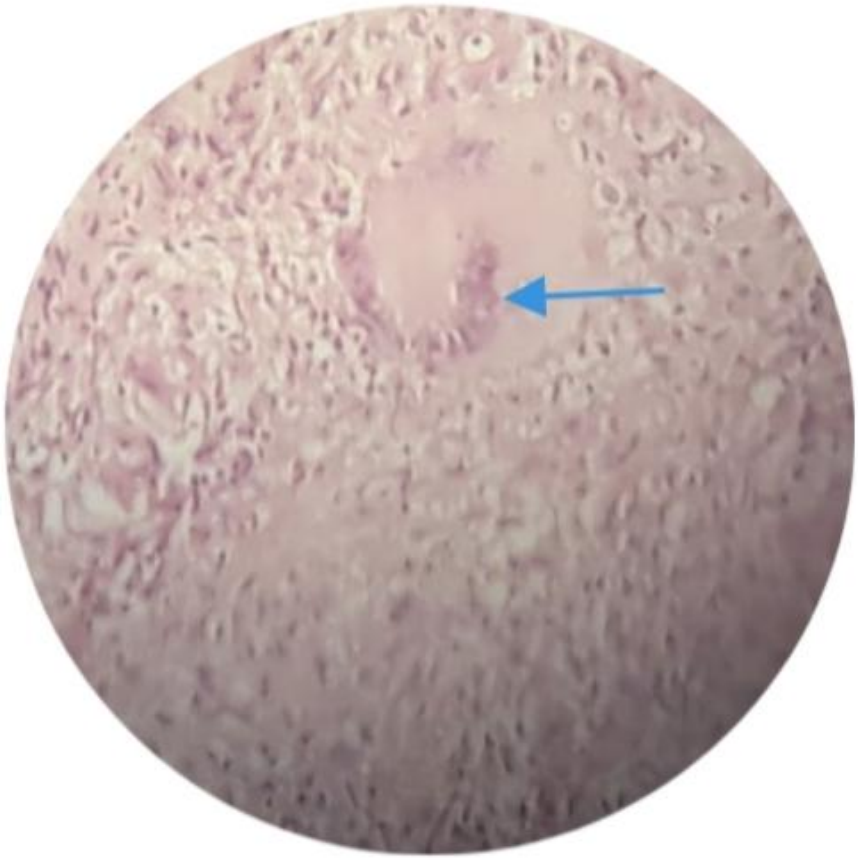

Fig 3 arrowmark pointing Langerhans giant cell with horse -shoe shaped nucleus.

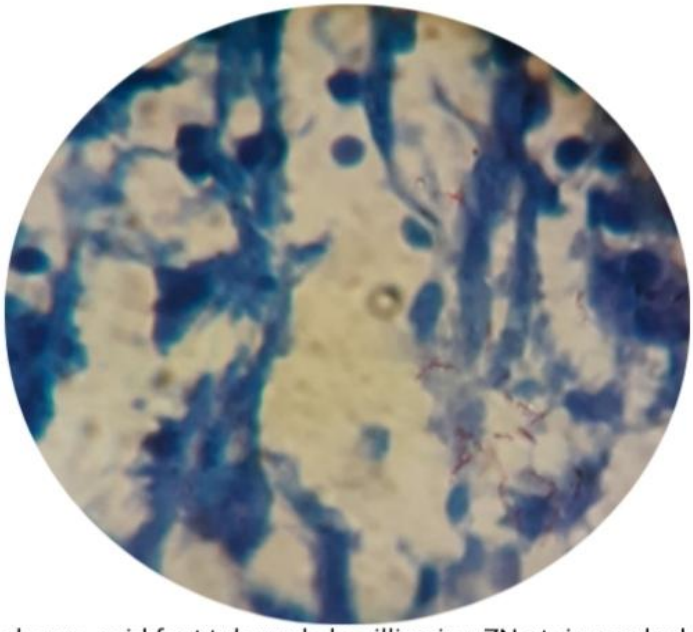

Fig 4 shows acid fast tubercule bacilli using ZN stain marked by arrows

Volume 4, Issue 2; March-April 2021; Page No 885-888