(International Print/Online Journal)

SJIF IMPACT FACTOR: 5.565
PUBMED-National Library of Medicine ID-101739732

ISSN (Print): 2209-2870
ISSN (Online): 2209-2862

International Journal of Medical Science and Current Research (IJMSCR)
Available online at: www.ijmscr.com
Volume4, Issue 2, Page No: 787-795
March-April 2021

Ultrasound guided pulsed radiofrequency lesioning of suprascapular nerve for the treatment of frozen shoulder pain

Sandeep khuba*[1], Sanjay Kumar[2], Sujeet Gautam[2], Chetna Shamshery[3], Anil Agarwal[4]
[1]Associate Professor, [2]Additional Professor, [3]Assistant Professor, [4]Professor
Department of Anaesthesiology, Sanjay Gandhi Postgraduate Institute of Medical Sciences, Lucknow, Uttar Pradesh, India-226014

***Corresponding Author:**
Dr Sandeep Khuba
Associate Professor, Department of Anaesthesiology Sanjay Gandhi Postgraduate Institute of Medical Sciences Lucknow, Uttar Pradesh, India-226014

Type of Publication: Original Research Paper
Conflicts of Interest: Nil

ABSTRACT

Introduction

Frozen shoulder is a troublesome disease of the shoulder joint characterized by pain, stiffness, and loss of function. A variety of treatment modalities are offered for pain relief including the use of physical therapy, non-steroidal anti-inflammatory drugs (NSAIDS), intra-articular steroids, manipulation under anaesthesia and surgical capsular repair with limited success. The shoulder joint is chiefly innervated by the suprascapular nerve (SSN). The anaesthetic block of SSN has been observed leading to short term improvement in shoulder pain. In this retrospective study, we intended to evaluate the role of pulsed radiofrequency of SSN for the treatment of chronic pain of the frozen shoulder.

Methods

20 patients underwent pulsed radiofrequency of SSN from January 2017 to December 2018 for frozen shoulder pain after a successful diagnostic block. The hospital records of these patients were reviewed for demographic data, duration of symptoms, side involved and pain VAS scores pre and post procedure at 1 week, 1 and 3 months. The VAS scores were compared with repeated measures of one-way ANOVA test.

Results

The VAS (Mean±SD) scores at pre and post procedure at 1 week, 1 and 3 months were 8.85±0.88, 3.40± 1.10, 4.35± 0.88, 5.05±0.94, respectively. There was a significant reduction in VAS scores at all time points as compared to pre procedure ($p<0.001$)

Conclusion

Ultrasound guided pulsed radiofrequency lesioning of suprascapular nerve results in significant relief in frozen shoulder pain for duration of up to 3 months.

Keywords: Chronic shoulder pain; Adhesive capsulitis; Suprascapular nerve block; Ultrasound guided; Diagnostic block.

INTRODUCTION

Frozen shoulder or adhesive capsulitis is a troublesome disease of the shoulder joint. It leads to marked disability because of pain with restriction of active and passive movement of the joint. Its prevalence is around 2 to 5 % in the general population, more commonly affecting the patients with diabetes mellitus, stroke, and local shoulder pathology.[1] A variety of treatment modalities are offered for pain relief including the use of physical therapy, non-steroidal anti-inflammatory drugs

(NSAIDS), intra-articular steroids, manipulation under anaesthesia and surgical capsular repair with limited success. [2]

The shoulder joint is chiefly innervated by the suprascapular nerve. [3] The anaesthetic block of the suprascapular nerve has been studied for the treatment of acute and chronic shoulder pain.

Pulsed radiofrequency is a mode of radiofrequency treatment in which electric signals are applied to the target tissue in short bursts of 10-20 milliseconds with a frequency of 2-5 Hertz. The rationale behind the application of pulsed radiofrequency to a neural structure for pain relief is that it preserves the cellular integrity of the nervous tissue which is important in the case of sensory and motor nerves. In the present study, we intend to evaluate the efficacy of pulsed radiofrequency of suprascapular nerve to relieve the chronic shoulder pain in patients suffering from frozen shoulder.

Materials and Methods

This retrospective observational study is conducted after approval from the institutional ethical committee. This study included patients who underwent ultrasound guided (USG) pulsed radiofrequency lesioning of the suprascapular nerve for frozen shoulder pain from January 2017 to December 2018.

Inclusion criteria

1. Patients who underwent pulsed radiofrequency lesioning after successful diagnostic suprascapular nerve block. The successful diagnostic suprascapular nerve block was defined as more than 50% pain relief for at least 24 hours after anaesthetic block with 5 ml of 1% lignocaine.
2. Patients who failed to get adequate pain relief with intraarticular steroid.

Exclusion criteria

1. The patients with a history of trauma, surgery of shoulder joint or systemic inflammatory diseases were excluded.
2. Intraarticular steroid injection within 3 months of the suprascapular nerve block.

The hospital records of these patients were reviewed for demographic data, duration of symptoms, side, and pain VAS scores pre and post procedure at 1 week, 1 and 3 months. VAS score for pain was calculated using a 0 to 10 cm horizontal line where 0 corresponds to no pain and 10 to severe pain. The patient was asked to mark his or her current pain on this line. The point where the patient marked was measured and reported as the score. The informed consent was taken from all the patients regarding the procedure and possible publication of data.

Diagnostic suprascapular nerve block procedure

The procedure was performed under standard American Society of Anesthesiologists (ASA) monitoring. The intravenous access was obtained before beginning the procedure. The procedure was performed with the patient in the sitting position with the clinician standing behind. The ultrasound machine was kept in the front for better ergonomics for the clinician. (Figure 1) The shoulder area was prepared aseptically with chlorhexidine and povidone-iodine solution. The high frequency (6–13 MHz) linear probe of the ultrasound machine (M-Turbo, Fujifilm Sonosite, USA) was placed in a transverse plane to visualize the suprascapular notch. (Figure 1) The suprascapular artery and the transverse scapular ligament were visualized in the suprascapular notch. A 2–3 ml of lignocaine 1% was infiltrated into the skin and subcutaneous tissue. A 22 G, 10 cm Quincke spinal needle is inserted in the “in-plane technique” towards the suprascapular notch (Figure 2). 5 ml of 1% lignocaine is deposited in the suprascapular notch to block the suprascapular nerve. (Figure 3)

Pulsed radiofrequency suprascapular nerve lesioning procedure

The procedure for pulsed radiofrequency is the same as for diagnostic block except in it, the radiofrequency needle is used instead of the spinal needle. The 10 cm radiofrequency needle (Cosman cannula CC, Cosman Medical Inc, Burlington, MA, USA) with 5 mm active tip was inserted with an “in-plane” approach from the medial side and placed in the suprascapular notch close to the suprascapular nerve. The proximity of the needle to the suprascapular nerve was confirmed with sensory and motor testing with the radiofrequency generator (G4-257, Cosman Medical Inc, Burlington, MA, USA). The sensory stimulation was given at 50 herz (Hz) frequency. On sensory testing, the patient was asked

Volume 4, Issue 2; March-April 2021; Page No 787-795

to report pain or paresthesia in the shoulder joint. The motor stimulation was done at a frequency of 2 Hz. On motor testing, contraction of the supraspinatus and infraspinatus was sought. The sensory and motor contractions at < 0.5 V of stimulation was considered as a sign of proximity to the suprascapular nerve. The Pulsed radiofrequency (PRF) treatment was given for 3 cycles of 120 seconds duration each at 42° C, 45 V, 2 Hz and 20 ms pulse duration, targeting different parts of the suprascapular nerve. After that, the needle was removed, and a sterile dressing applied. Then patients were transferred to post anaesthesia care unit (PACU). The patients were observed in the PACU for 2 hours and was discharged.

All the patients were advised a short course of oral aceclofenac 100 mg twice a day for 3 days and thereafter oral tramadol/paracetamol combination (37.5 mg/325 mg) if they experience pain with VAS >3. All the patients were advised to continue home-based joint mobilization and rotator cuff strengthening exercises.

Statical analysis

The quantitative data are presented as mean±SD and qualitative data as frequency and percentage. The VAS values are compared between pre and post procedure at 1 week, 1 month and 3 months with one-way repeated measures of ANOVA test. A p value<0.05 is considered statically significant. The statistical analysis is done with SPSS software version 13.0 (SPSS Inc., Chicago, Ill., USA)

Results

20 patients suffering from frozen shoulder underwent pulsed radiofrequency lesioning of suprascapular nerve after failed conservative therapy from January 2017 to December 2018. The demographic data are presented in Table 1. The VAS scores at pre and post-procedure presented in Table 2.

The VAS scores at baseline and 1 week, 1 month and 3 months post-procedure is presented in Table 2.

As shown in table 2 there is a significant decrease in VAS scores from pre-procedure to 1 week, 1 and 3 months post-procedure.

Discussion

This study shows that there is significant relief in shoulder pain as compared to pre-procedure at 1 week, 1 and 3 months after the USG pulsed radiofrequency of the suprascapular nerve in frozen shoulder patients.

Frozen shoulder is a clinical condition due to the formation of excessive scar tissue or adhesions across the glenohumeral joint, leading to stiffness, pain, and dysfunction. [1, 4] This painful stiffness of the shoulder can adversely affect activities of daily living and consequently impair quality of life. Clinically it can be characterized by 4 stages. [5] Stage 1 presents predominately with pain in the shoulder joint rather than stiffness, in stage 2, patients start experiencing stiffness in the shoulder joint. Both stage 1 and 2 lasts 3 to 9 months. Stage 3 is characterized by stiffness with pain at the end of the range of motion of the joint, which lasts for 4 to 12 months. In stage 4, stiffness predominates which lasts 12 to 42 months. It is usually a self-limiting disease that resolves in approximately 1 to 3 years. But 20% and 50% of patients may go on to develop long-lasting symptoms. [6] The mean duration of symptoms in the present study is 11.09±3.31 months (Range, 6–18 months) which mean the patients are in the third or fourth stage of the disease. The intraarticular steroids have good efficacy when given in the first and second stage of the frozen shoulder during which synovitis predominates. [7] This may be the reason for the poor response of these patients to intraarticular steroids.

The treatment of frozen shoulder consists of physical therapy, non-steroidal anti-inflammatory drugs, intra-articular steroids, manipulation under anaesthesia and arthroscopic or capsular repair with limited success. [2]

Suprascapular nerve block has been used for the treatment of chronic shoulder pain of adhesive capsulitis, glenohumeral osteoarthritis, rotator cuff tear, subacromial bursitis and post-stroke origin. [8] The suprascapular nerve is the greatest contributor to sensory innervation of the shoulder joint. [9] The rest of the innervation includes articular branches of the lateral pectoral, axillary and lower subscapular nerve. [3] The blockade of sensory supply of a chronic painful joint lead to an improvement in its pain relief and function. In this study, all the patients reported more than 50% pain relief with the local anaesthetic block (lidocaine 1%) of the suprascapular nerve for at least 24 hours. The analgesic effect of the local anaesthetic block in chronic painful conditions usually outlives the duration of action of the local

Volume 4, Issue 2; March-April 2021; Page No 787-795

anaesthetic. It may be because the local anaesthetic leads to temporary interruption of nociceptive input to dorsal root ganglion, which helps in decreasing the central sensitization. Once the action of local anaesthetic ends, it may take a noxious input considerable time to develop central sensitization again. [10] This may be the reason for the patients, included in the present study experiencing pain relief for more than 24 hours after the diagnostic block.

A suprascapular nerve block with only local anaesthetic provided a noticeably short duration of pain relief. [11] So the local anaesthetic in combination with steroids have been tried for suprascapular nerve block which resulted in pain relief and functional improvement for up to 12 weeks. [12, 13] However, locally administered steroids are not without side effects. It may lead to suppression of the hypothalamic-pituitary-adrenal axis, the duration of which depends upon type, dose and frequency of glucocorticoid injection. Other metabolic effects of locally administered glucocorticoids include the development of Cushing's syndrome, hyperglycemia in both diabetic and non-diabetic patients and decreased bone mineral density. It may also lead to immunosuppression with a risk of infection as well as depression or mania in known psychiatric patients. [14]

The pulsed radiofrequency (PRF) lesioning, one of the modes of radiofrequency ablation of the peripheral nerves can be used to augment the pain relief without damaging the integrity of the nerve. It avoids the side effects associated with steroids. The radiofrequency electric signals can be used either in conventional or pulsed mode. In conventional mode, the application of radiofrequency (RF) electric signals to neural tissue creates an electromagnetic field around it which leads to oscillation of molecules at high frequency. This oscillation of molecules at high frequency leads to the generation of heat energy, ultimately leading to thermal ablation. [15]

PRF mode applies short pulses of electric signals to the neural tissue. In this mode, because the pulse duration is only a small percentage of the time between pulses, so the tissue temperature does not rise much as compared to conventional RF at the same voltage level. So higher voltage could be applied to neural tissue as compared to conventional RF. The low frequency of pulses and the high voltages in PRF induces long term depression of synaptic transmission at the spinal cord, and in so doing, antagonizes the long-term potentiation that is purported to underlie many chronic pain states. [16, 17] The various mechanisms have been proposed for the pain-relieving effects of pulsed radiofrequency including generation of transmembrane potentials, induction of C-fos gene, disruption of the myelin sheath of nerve fibers and enhancing descending inhibitory noradrenergic and serotonergic modulatory system. [18] A neuromodulatory effect via changing gene expression in pain processing neurons has also been suggested for PRF effects. [19]

The PRF is used for a wide variety of chronic pain states that includes cervical radicular pain, Lumbar zygapophyseal joint pain, lumbosacral radicular pain, trigeminal neuralgia, and also chronic shoulder pain with varying success. [18]

PRF of the suprascapular nerve has been studied for chronic shoulder pain of adhesive capsulitis, rotator cuff disorders, glenohumeral osteoarthritis and subacromial bursitis. These studies have demonstrated benefit in pain relief and shoulder function for up to 6 months in patients of chronic shoulder pain of mixed etiology. [20, 21, 22, 23, 24] The present study agrees with the previous studies that the PRF of the suprascapular nerve led to an improvement in pain and function. But the present study included patients of only frozen shoulder who failed conservative treatment and intra-articular steroid injection as compared to previous studies which included patients of chronic shoulder pain of mixed etiology.

Gofeld et al [23] compared PRF of suprascapular nerve and anaesthetic block (1% lidocaine) for chronic shoulder pain of varied etiology. They found PRF superior to the 1% lidocaine in pain relief and functional improvement for 6 months. Eyigor et al [25] compared intraarticular steroid and pulsed radiofrequency lesioning of suprascapular nerve for chronic shoulder pain. They reported improvement in pain, function, quality of life and depression scores in both steroid and pulsed radiofrequency group for 12 weeks. They found intraarticular steroid better than pulsed radiofrequency of suprascapular nerve for treatment of chronic shoulder pain of varied etiology. Although our study did not include any comparison group, we observed the same improvement in pain

Volume 4, Issue 2; March-April 2021; Page No 787-795

scores for up to 3 months in chronic shoulder pain after pulsed radiofrequency treatment of suprascapular nerve.

The suprascapular nerve can be blocked by different approaches. This includes anatomic landmark-based, fluoroscopic guide or ultrasound-guided approach. The USG guided approach is more efficacious, safer, and free from radiation effects as compared to landmark and fluoroscopic approach. [26] So the present study utilized the USG approach for both diagnostic block and PRF treatment of suprascapular nerve.

In summary, this study reiterates that USG pulsed radiofrequency treatment of suprascapular results in significant relief in frozen shoulder pain for a duration of up to 3 months.

Limitations of the study

- Retrospective observational study
- No comparison group
- Small sample size

References

1. Manske RC, Prohaska D. Diagnosis and management of adhesive capsulitis. Curr Rev Musculoskelet Med. 2008 Dec;1(3-4):180-9. doi: 10.1007/s12178-008-9031-6. PMID: 19468904; PMCID: PMC2682415.
2. Le HV, Lee SJ, Nazarian A, Rodriguez EK. Adhesive capsulitis of the shoulder: review of pathophysiology and current clinical treatments. Shoulder Elbow. 2017 Apr;9(2):75-84. doi: 10.1177/1758573216676786. Epub 2016 Nov 7. PMID: 28405218; PMCID: PMC5384535.
3. Laumonerie P, Dalmas Y, Tibbo ME, Robert S, Faruch M, Chaynes P, Bonnevialle N, Mansat P. Sensory innervation of the human shoulder joint: the three bridges to break. J Shoulder Elbow Surg. 2020 Dec;29(12): e499-e507. doi: 10.1016/j.jse.2020.07.017. Epub 2020 Jul 23. PMID: 32712453.
4. Neviaser AS, Neviaser RJ. Adhesive capsulitis of the shoulder. J Am Acad Orthop Surg. 2011 Sep;19(9):536-42. doi: 10.5435/00124635-201109000-00004. PMID: 21885699.
5. Neviaser RJ, Neviaser TJ. The frozen shoulder. Diagnosis and management. Clin Orthop Relat Res. 1987 Oct;(223):59-64. PMID: 3652593.
6. Hand C, Clipsham K, Rees JL, Carr AJ. Long-term outcome of frozen shoulder. J Shoulder Elbow Surg. 2008 Mar-Apr;17(2):231-6. doi: 10.1016/j.jse.2007.05.009. Epub 2007 Nov 12. PMID: 17993282
7. Challoumas D, Biddle M, McLean M, Millar NL. Comparison of Treatments for Frozen Shoulder: A Systematic Review and Meta-analysis. JAMA Netw Open. 2020 Dec 1;3(12):e2029581. doi: 10.1001/jamanetworkopen.2020.29581. PMID: 33326025; PMCID: PMC7745103.
8. Fernandes MR, Barbosa MA, Sousa AL, Ramos GC. Suprascapular nerve block: important procedure in clinical practice. Rev Bras Anestesiol. 2012 Jan-Feb;62(1):96-104. doi: 10.1016/S0034-7094(12)70108-3. PMID: 22248771.
9. Laumonerie P, Blasco L, Tibbo ME, Bonnevialle N, Labrousse M, Chaynes P, Mansat P. Sensory innervation of the subacromial bursa by the distal suprascapular nerve: a new description of its anatomic distribution. J Shoulder Elbow Surg. 2019 Sep;28(9):1788-1794. doi: 10.1016/j.jse.2019.02.016. Epub 2019 Apr 26. PMID: 31036420.
10. Hogan QH, Abram SE. Neural blockade for diagnosis and prognosis. A review. Anesthesiology. 1997 Jan;86(1):216-41. doi: 10.1097/00000542-199701000-00026. PMID: 9009957.
11. Ritchie ED, Tong D, Chung F, Norris AM, Miniaci A, Vairavanathan SD. Suprascapular nerve block for postoperative pain relief in arthroscopic shoulder surgery: a new modality? Anesth Analg. 1997 Jun;84(6):1306-12. doi: 10.1097/00000539-199706000-00024. PMID: 9174311.
12. Shanahan EM, Ahern M, Smith M, Wetherall M, Bresnihan B, FitzGerald O. Suprascapular nerve block (using bupivacaine and methylprednisolone acetate) in chronic shoulder pain. Ann Rheum Dis. 2003 May;62(5):400-6.

doi: 10.1136/ard.62.5.400. PMID: 12695149; PMCID: PMC1754520.

13. Jones DS, Chattopadhyay C. Suprascapular nerve block for the treatment of frozen shoulder in primary care: a randomized trial. Br J Gen Pract. 1999 Jan;49(438):39-41. PMID: 10622015; PMCID: PMC1313316
14. Stout A, Friedly J, Standaert CJ. Systemic Absorption and Side Effects of Locally Injected Glucocorticoids. PM R. 2019 Apr;11(4):409-419. doi: 10.1002/pmrj.12042. Epub 2019 Mar 29. PMID: 30925034.
15. Rea W, Kapur S, Mutagi H. Radiofrequency therapies in chronic pain. Contin Educ Anaesth Crit Care Pain 2011; 11:35-38. doi: 10.1093/bjaceaccp/mkq057
16. Munglani R. The longer term effect of pulsed radiofrequency for neuropathic pain. Pain. 1999 Mar;80(1-2):437-9. doi: 10.1016/s0304-3959(98)00183-3. PMID: 10204759.
17. Pockett S. Spinal cord synaptic plasticity and chronic pain. Anesth Analg. 1995 Jan;80(1):173-9. doi: 10.1097/00000539-199501000-00026. PMID: 7802274.
18. Chua NH, Vissers KC, Sluijter ME. Pulsed radiofrequency treatment in interventional pain management: mechanisms and potential indications-a review. Acta Neurochir (Wien). 2011 Apr;153(4):763-71. doi: 10.1007/s00701-010-0881-5. Epub 2010 Nov 30. PMID: 21116663; PMCID: PMC3059755.
19. Higuchi Y, Nashold BS Jr, Sluijter M, Cosman E, Pearlstein RD. Exposure of the dorsal root ganglion in rats to pulsed radiofrequency currents activates dorsal horn lamina I and II neurons. Neurosurgery. 2002 Apr;50(4):850-5; discussion 856. doi: 10.1097/00006123-200204000-00030. PMID: 11904038.
20. Sinha P, Sarkar B, Goswami S, Ray Karmakar P, Dasgupta SR, Basu S. Effectiveness of Combination of Ultrasonography-Guided Pulsed Radiofrequency Neuromodulation With Steroid at the Suprascapular Nerve in Chronic Shoulder Pain. Pain Pract. 2020 Jan;20(1):16-23. doi: 10.1111/papr.12820. Epub 2019 Aug 24. PMID: 31310702.
21. Liliang PC, Lu K, Liang CL, Tsai YD, Hsieh CH, Chen HJ. Pulsed radiofrequency lesioning of the suprascapular nerve for chronic shoulder pain: a preliminary report. Pain Med. 2009 Jan;10(1):70-5. doi: 10.1111/j.1526-4637.2008.00543.x. PMID: 19222771.
22. Jang JS, Choi HJ, Kang SH, Yang JS, Lee JJ, Hwang SM. Effect of pulsed radiofrequency neuromodulation on clinical improvements in the patients of chronic intractable shoulder pain. J Korean Neurosurg Soc. 2013 Dec;54(6):507-10. doi: 10.3340/jkns.2013.54.6.507. Epub 2013 Dec 31. PMID: 24527194; PMCID: PMC3921279.
23. Gofeld M, Restrepo-Garces CE, Theodore BR, Faclier G. Pulsed radiofrequency of suprascapular nerve for chronic shoulder pain: a randomized double-blind active placebo-controlled study. Pain Pract. 2013 Feb;13(2):96-103. doi: 10.1111/j.1533-2500.2012.00560.x. Epub 2012 May 4. PMID: 22554345.
24. Ergonenc T, Beyaz SG. Effects of ultrasound-guided suprascapular nerve pulsed radiofrequency on chronic shoulder pain. Med Ultrason. 2018 Dec 8;20(4):461-466. doi: 10.11152/mu-1543. PMID: 30534653.
25. Eyigor C, Eyigor S, Korkmaz OK, Uyar M. Intra-articular corticosteroid injections versus pulsed radiofrequency in painful shoulder: a prospective, randomized, single-blinded study. Clin J Pain. 2010 Jun;26(5):386-92. doi: 10.1097/AJP.0b013e3181cf5981. PMID: 20473045.
26. Chan CW, Peng PW. Suprascapular nerve block: a narrative review. Reg Anesth Pain Med. 2011 Jul-Aug;36(4):358-73. doi: 10.1097/AAP.0b013e3182204ec0. PMID: 21654552.

Volume 4, Issue 2; March-April 2021; Page No 787-795

Age (Mean±SD)	52.35±9.34 years
Sex M/F(n/%)	14(70)/6(30)
Duration of symptoms (Mean±SD)(Median) (Range)	11.09±3.31 months, (11 months) (6-18 months)
Site R/L (n/%)	12(60)/8(40)

Table 1: Distribution of demographic data (n=20)

	VAS score (Mean±SD)
Pre procedure	8.85±0.88
1 week	3.40± 1.10
1 month	4.35± 0.88
3 months	5.05 ± 0.94
One-way Repeated measures of ANOVA test (*p* value)	<0.001
Pair wise comparison form pre procedure to 1 month, 3 months, 6 months and 12 months (p value<0.05)	

Table 2: Distribution of VAS scores (n=20)

Volume 4, Issue 2; March-April 2021; Page No 787-795

Figure 1: Position of the patient & placement of ultrasound probe

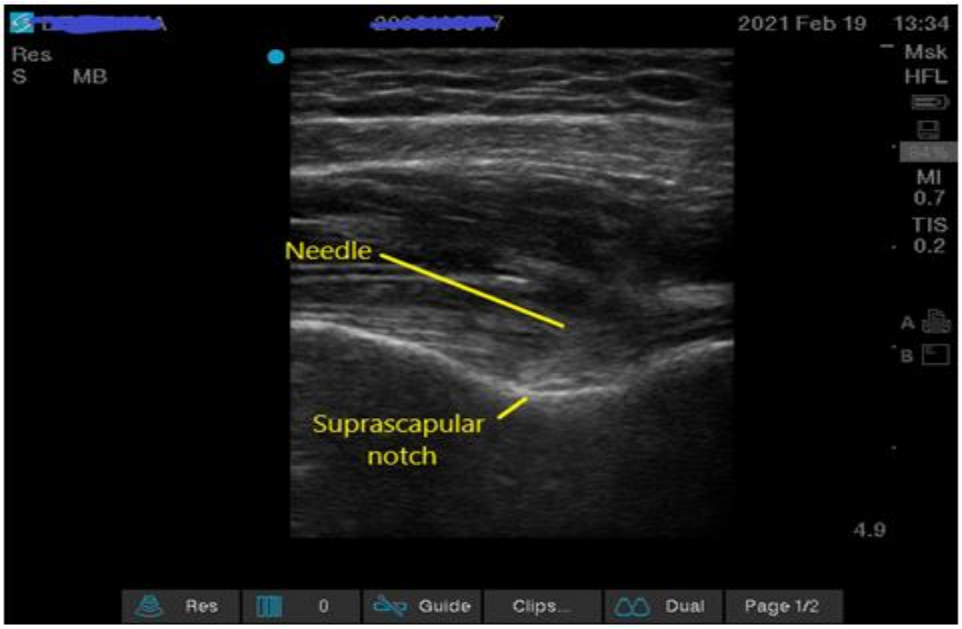

Figure 2: Spinal needle in suprascapular notch

Volume 4, Issue 2; March-April 2021; Page No 787-795

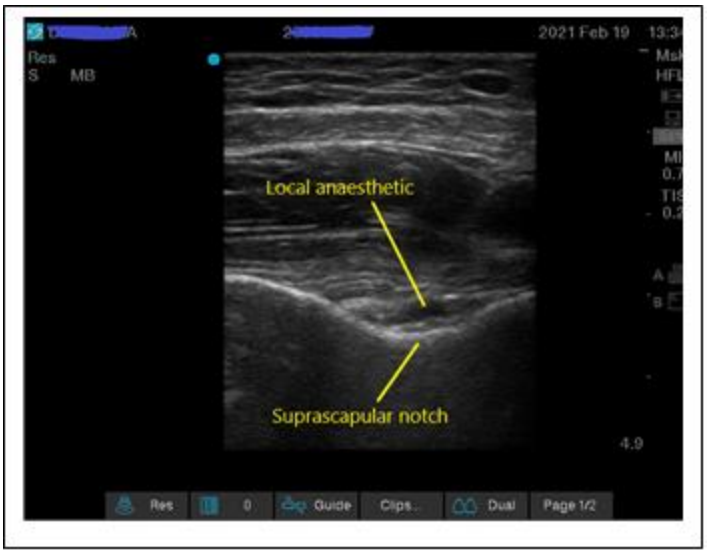

Figure 3: Local anaesthetic spread

Volume 4, Issue 2; March-April 2021; Page No 787-795