(International Print/Online Journal)

SJIF IMPACT FACTOR: 5.565
PUBMED-National Library of Medicine ID-101739732

ISSN (Print): 2209-2870
ISSN (Online): 2209-2862

International Journal of Medical Science and Current Research (IJMSCR)
Available online at: www.ijmscr.com
Volume4, Issue 2, Page No: 554-561
March-April 2021

Study of resistant, relapsed and neglected congenital talipes equino varus treated by differential distraction using Joshi's external stabilization system

Chitta Ranjan Sahu[1] T Stalin Chowdary[2] Mangu Hanumantha Rao[3]
[1]Professor and Head, [2]Consultant, [3]Senior Professor
[1]Department of Orthopaedics, [2]Orthopaedic Surgeon, [3]Anaesthesiology and Executive Director
[1,3]Sri Balaji Medical College Hospital and Research Institute, Tirupati – 517520, Andhra Pradesh India
[2]Capital-Hospital, 15-177/1, Vijayawada Road, Poranki, Vijayawada - 521137, Andhra Pradesh, India

***Corresponding Author:**
Dr. Chitta Ranjan Sahu
404 Tulip Residency, Cherlopalli-Alipiri Road, Tirupati – 517505, Andhra Pradesh, India

Type of Publication: Original Research Paper
Conflicts of Interest: Nil

ABSTRACT

Background: Late, neglected, rigid and relapsed congenital talipes equino varus (CTEV or club foot) are not uncommon and pose a challenge in the treatment. This prospective study was done to evaluate the role of Joshi's external stabilization system (JESS) in the correction of these subset of deformity by ligamentotaxis.

Patients and methods: A total of 44 feet (42 patients), age 1-12(Mean 4.79) years were put on JESS for deformity correction and were followed for a minimum period of 14 months.

Results: Mean Dimeglio score improved from 10.72 (range 8-13) SD 1.43 to 3.34 (range 2-4) SD 1.05 pre to post application of the fixator respectively. Functional outcome evaluated using Simon's criteria showed satisfactory result in 40 patients and unsatisfactory in 2 patients. Important complications encountered were metatarsophalangeal joint flexion in 7 cases and osteomyelitis at tibial half pin site in 1 patient.

Conclusion: Differential distraction by JESS is an effective and minimally invasive method in the treatment of neglected idiopathic CTEV.

Keywords: CTEV, JESS, ligamentotaxis, club foot, differential distraction.

INTRODUCTION

Congenital talipes equino varus (CTEV or club foot) remains one of the most commonly encountered diagnosis in a paediatric foot and ankle clinic.[1] Around the world, 150,000 – 200,000 babies with clubfoot are born each year.[1,2] In rural Indian population clubfoot was the commonest congenital anomaly at 0.9 per 1000 population.[3] In developed countries clubfoot is usually corrected early in life leaving little or no disability.[4] In the developing world it is not uncommon to see clubfoot late, neglected, with recurrence or relapse of deformity.[5,6] Although initial non operative treatment with manipulative reduction and plaster casting described by Ignasio V. Ponseti[7-11] is widely accepted as an effective method, lack of understanding of anatomy, kinematics and pathology of clubfoot among orthopaedists has led to major errors in treatment thus creating space for invasive and minimally invasive surgical techniques. [12-19] One such treatment modality is differential distraction with Joshi's external stabilization system (JESS).[20] Various studies on clubfoot correction using JESS have evidenced satisfactory results establishing JESS as a viable option in the treatment of clubfoot.[21] A clinico-radiological correlation following full correction remains a grey area.[22-24] The present study intends to address the lacuna and suggest modifications based on the difficulties and complications encountered.[25-28]

Patients and methods

This prospective study was conducted in a 300 bedded tertiary care referral orthopaedic centre in the Southern India over a period of 24 months with a minimum follow up period of 14 months. The study methodology, its necessity and relevance were presented before the Institutional Ethics Committee and approval was obtained. This study was conducted upon patients with idiopathic clubfoot not responding to serial manipulations, neglected, recurrent and relapsed cases. Patients aged 1 year to 12 years with idiopathic clubfoot were included in the study. Both unilateral and bilateral cases were included. Non idiopathic clubfoot patients were excluded from the study. Patients were evaluated both clinically and radiologically[29]. Clinical evaluation was done using Dimeglio scoring system[30,31] in which parameters namely sagittal plane evaluation of equinus, frontal plane evaluation of varus, derotation of calcaneopedal block and forefoot adduction in relation to hind foot in the horizontal plane were recorded. Severity of deformity was classified based on Dimeglio score (Figure 1). Radiological evaluation was done by standard anteroposterior radiographs which were taken with the foot kept flat on the plate with maximal possible correction of deformity with x-ray beam focused on the talus and lateral view taken with the lateral border of foot touching the plate with foot in maximally dorsiflexed position and the tube directed vertically downwards. Radiological indices measured were talocalcaneal angle and talofirstmetatarsal angle in anteroposterior view, tibiocalcaneal and talocalcaneal angles in lateral view (Figure 2). Talocalcaneal index which is the sum of talocalcaneal angle in anteroposterior and lateral radiographs was also calculated. Surgical intervention was undertaken after adequate pre-operative assessment was made and only after taking informed consent.

All patients were operated under spinal subarachnoid block. Surgical procedure included sequential placement of K- wires, attachment of L-rods and Z-rods, interconnection with distractors both medially and laterally. There were basically three sets of K-wires which were introduced. First set was passed through the fore foot, second set through the hind foot and third set through the proximal tibia. In the forefoot, the first K-wire was passed in a lateral to medial direction through the head of the 5th metatarsal that exited through the head of the 1st metatarsal. This wire holds the fifth, fourth second and first metatarsals. It may or may not hold the third metatarsal. The second K-wire was passed just proximal to the first one at an appropriate distance as per the size of the clamp in a lateral to medial direction maintaining the arch of the foot. This passes through the fifth and fourth metatarsals. The third one was passed in a similar manner in a mediolateral direction through the first and the second metatarsals. In the hind foot, two parallel K-wires were passed through the calcaneum in a mediolateral direction at an appropriate distance as per the clamp and in line with the sole of the foot. The third wire was passed unicortically into the calcaneum in a posterior to anterior direction along its long axis. This wire was passed at the end through the central clamp of the posterior connecting rod after assembling the fixator as shown (Figure 3). In the proximal tibia, two parallel K-wires were passed in a lateral to medial direction at the metaphyseodiaphyseal junction. These wires were passed at a maximum distance as allowed by the horizontal part of the Z-rod. The third wire was passed in an antero-posterior direction through the central clamp of the connecting rod to the tibia and is uni-cortical. Distraction was initiated on third postoperative day. Differential distraction schedule was followed. Medial distraction was done twice as much as on lateral. Simultaneous passive extension of all toes was done. Pin site dressing was done regularly. End point of distraction was judged clinically and radiologically. Static phase was continued for double the time needed for correction initially with JESS and following JESS removal with above knee plaster casting in slightly overcorrected position. Following plaster cast removal Dennis Brown shoes were given for maintenance of correction. Functional evaluation was done using Simons criteria (Table2)[32].

Results

A total of 44 feet (42 patients) were studied age ranging from 1 to 12 years. Mean age being 4.79 years and 3 years being mode of the class. Male to female ratio was 3:1 with 31(74%) male patients and 11 female (26%) patients. 22 patients (52.38%) presented with left sided CTEV and 18 patients (42.85%) with right sided CTEV. Two patients had bilateral deformity in whom deformity correction was done one side at a time. Mean preoperative Dimeglio

Volume 4, Issue 2; March-April 2021; Page No 554-561

score was 10.72 (range 8-13) ± 1.43. Mean postoperative Dimeglio score was 3.34 (range 2-4) with standard deviation of 1.05. Average preoperative talocalcaneal index was observed to be 20.90^0 (range 13^0 - 38^0) with a standard deviation of 5.62^0. Following full deformity correction with JESS average postoperative talocalcaneal index was observed to be 43.61^0 (range 27^0 - 69^0) with a standard deviation of 9.52^0 (Normal talocalcaneal index is > 40^0). Average preoperative talus first metatarsal angle was observed to be 24.27^0 (range 7^0 to 38^0) with a standard deviation of 6.76^0. Following full deformity correction with JESS average postoperative talus first metatarsal angle was observed to be 2.93^0 (range -7^0 to 24^0) with a standard deviation of 6.31^0 (Normal angle is 0^0 to -20^0. An angle above 0^0 denotes fore foot adduction). Average preoperative tibiocalcaneal angle was observed to be 112.02^0 (range 95^0 to 139^0) with a standard deviation of 10.22^0. Following full deformity correction with JESS average postoperative tibiocalcaneal angle was observed to be 87.97^0 (range 73^0 to 102^0) with a standard deviation of 6.88^0. The average time taken for correction was 4.06 weeks least being 2 weeks and highest 8 weeks with a standard deviation of 2.778 weeks. Functional outcome in all patients was evaluated using Simon's criteria.[33-35] In our study 40 patients showed satisfactory result and 2 patients showed unsatisfactory result. Both cases have Grade III Dimeglio severity of clubfoot preoperatively. Time taken for correction was also more in comparison with other cases.

All scores were significantly different when compared preoperatively and postoperatively. The significance of difference between preoperative and postoperative values were computed using the Student paired t – test (Table-1). The results were significant within a 95% Confidence Interval.

Complications

The most common complication was metatarsophalangeal joint flexion seen in 7(0.16%) feet and osteomyelitis at tibial half pin site was found in 1(0.02) foot. Three feet had persistent forefoot adduction deformity.

Discussion

Efficacy of JESS in CTEV correction has been proven through various studies. Our understanding of principle of correction of CTEV with JESS is close to Ponseti's method of sequential manipulation and casting.[7] Placement of metatarsal wires and linking them with calcaneal wires with distractor brings both hind foot and forefoot into same plane of supination. Distraction from here occurs simultaneously along forefoot and hind foot, while medial foot distraction addresses forefoot adduction.

Gender distribution in our study population was similar to other studies i.e. Ognesian and Istomina[35], Suresh S, Ahmed A et al[36], Anwar Marthya H[37], Arun B Manjappa CN with male predominance and majority of unilateral cases.

We achieved an average talocalcaneal index of 43.61^0 from 20.9^0 with 108.66% improvement which is inferior only to Ajay Singh study[38] (63.1^0 post-operative with 228% improvement) but our sample size was larger as compared to the study.

In the present study 42 children (44 feet) were studied. Preoperative and post-operative clinical assessment using Dimeglio score was done. A post-operative Dimeglio score of <5 was taken as good, 5-10 as fair and >10 as poor result. 41 (93.18%) achieved good result, 3 (6.81%) fair result and poor in none. Patients with fair result with postoperative Demeglio score of 5-10 had varying degrees of persistent forefoot adduction which was later addressed by doing a lateral closing wedge osteotomy of cuboid bone. Metatarsophalangeal joint flexion were managed initially by passive extension of toes. Resistant cases were managed by forcible manipulation and maintenance in POP cast at the time of JESS removal. Osteomyelitis at tibial half pin site necessitated change of K-wire position. Loosening of link joints was managed by periodic tightening with Allen key during every follow up. None of the above mentioned complications necessitated early removal of JESS. Three feet had persistent forefoot adduction deformity and were managed later by lateral closing wedge osteotomy of cuboid.

Conclusion

Current study reiterates the role of controlled differential distraction with JESS for CTEV as an effective procedure to correct all the deformities

Volume 4, Issue 2; March-April 2021; Page No 554-561

simultaneously with minimal surgical trauma and postoperative scar. Functional distraction using JESS apparatus is an easy method, which does not require any sophisticated instrumentation or image intensification. Adequate period of static phase is necessary before removal of the apparatus.

There is considerable clinical improvement as measured by Dimeglio score. Functional outcomes evaluated by Simon's criteria showed satisfactory results in majority of cases.

Radiological outcome correlates positively with clinical and functional outcome.

As the period of follow up in current study is medium term (14 months) further follow up is required to reiterate the strength of correlation.

Connecting medial distraction rods may be difficult in cases with very severe deformity. Such cases require extra caution in terms of pin placement and size of K-wires to be selected.

Patient compliance takes paramount importance for success of JESS. Loosening of the link joints is common which should be tightened at regular intervals. We advise continuous supervision with patient under admission during distraction phase in order to avoid improper and over distraction leading to complications like talocalcaneal subluxation.

Metatarsophalangeal flexion deformity can be avoided by regular passive extension of all toes during the distraction phase.

Disclosure

The author reports no conflicts of interest in this work.

References

1. Dobbs MB, Morcuende JA, Gurnett CA, Ponseti IV. Treatment of idiopathic clubfoot: an historical review. Iowa Orthop J. 2000;20:59–64.
2. Boo NY, Ong LC. Congenital talipes in Malaysian neonates: incidence, pattern and associated factors. Singapore Med J. 1990;31(6):539–42.
3. Cummings RJ, Lovell WW. Current Concepts Review : Operative Treatment of Congenital Idiopathic Clubfoot. J Bone Joint Surg. 1988;76A(7):1108–1112.
4. Ikeda K. Conservative treatment of idiopathic clubfoot. Journal of Pediatric Orthopaedics. Vol. 12. p. 217–223,1992.
5. Grill F, Franke J. The ilizarov distractor for the correction of relapsed or neglected clubfoot. J Pediatr Orthop. 1988;8(1):120.
6. Makhdoom A, Qureshi PAL, Jokhio MF, Siddiqui KA. Resistant clubfoot deformities managed by Ilizarov distraction histogenesis. Indian J Orthop. 2012;46(3):326–32.
7. Ponseti IV, Smoley EN. Congenital clubfoot-the results of treatment. The Journal of Bone and Joint Surgery. 1963;45(2):134–141.
8. McKay DW. New concept of and approach to clubfoot treatment: section II—correction of the clubfoot. Journal of Pediatric Orthopaedics. 1983;3(1):10–21.
9. Herzenberg JE, Radler C, Bor N. Ponseti versus traditional methods of casting for idiopathic clubfoot. J Pediatr Orthop. 2002;22(4):517–21.
10. Paley D. The correction of complex foot deformities using Ilizarov's distraction osteotomies. Clin Orthop Relat Res. 1993;(293):97–111.
11. Kite JH. Principles involved in the treatment of congenital clubfoot. The Journal of Bone and Joint Surgery. 1939;21(3,pp):122–129.
12. Irani RN, Sherman MS. The pathological anatomy of idiopathic clubfoot. Clin Orthop Relat Res. 1972;84:14–20.
13. Diaz VA, Diaz VJ. Pathogenesis of Idiopathic Clubfoot. Clin Orthop. 1984;185:14–24.
14. Wynne-Davies R. Family Studies and Cause of Congenital Clubfoot. J Bone Joint Surg. 46B:445:96.
15. DePuy J, Drennan JC. Correction of Idiopathic: A Comparison of Result of Early Versus Delayed Posteromedial Release. J Pediatr Orthop. 1989;9:44–48.
16. Grant AD, Atar D, Lehman WB. The Ilizarov technique in correction of complex foot

deformities. Clin Orthop Relat Res. 1992;NA;(280):94–103.

17. Spiegelberg B, Parratt T, Dheerendra SK, Khan WS, Jennings R, Marsh DR. Ilizarov principles of deformity correction. Ann R Coll Surg Engl. 2010;92(2):101–5.
18. Herzenberg JE, Carroll NC, Christofersen MR, Lee EH, White S, Munroe R. Clubfoot analysis with three-dimensional computer modeling. J Pediatr Orthop. 1988;8(3):257–62.
19. Crawford AH, Gupta AK. Clubfoot controversies: complications and causes for failure. Instr Course Lect. 1996;45:339–46.
20. Joshi BB, Laud NS, Warrier S, Kanaji BG, Joshi AP, Dabake H. Treatment of CTEV by Joshi's External Stabilization System (JESS. In: Kulkarni GS, editor. 1st ed. New Delhi: Jaypee Brothers Medical Publishers; 1999.
21. Shinde A, Kamble S, Shah S, Shinde R. A clinical study of ligamentoaxis using an external fixator, modified frame in the management of a neglected, relapsed, resistant older congenital Talipes Equino varus child. Med j Dr D Patil Univ. 2013;6(3):274.
22. Varun GBS, Muralidhar N, Bharathidasan K. Radiological Outcomes of Management of Congenital Clubfoot Using JESS. Int J Sci Stud. 2016;4(2).
23. Osterman K, Merikanto J. Critical aspects of neonatal surgery in clubfoot. J Pediatr Orthop B. 1996 Winter;5(1):55–6.
24. Vizekelety T, Szepesi K. Reoperation in treatment of clubfoot. J Pediatr Orthop. 1989;9:144–7.
25. Dwyer FC. Osteotomy of the calcaneum for pes cavus. J Bone Joint Surg Br. 1959;41-B(1):80–6.
26. Lichtblau S. A medial and lateral release operation for clubfoot. J Bone Jt Surg Am. 1973;55:1377–1384.
27. Crawford AH, Marxen JL, Osterfeld DL. The Cincinnati incision: a comprehensive approach for surgical procedures of the foot and ankle in childhood. J Bone Joint Surg Am. 1982;64(9):1355–8.
28. K. RP, P SO. Correction of clubfoot by combined posteromedial and subtalar release. Ind J Ortho. 1986;14:94–96.
29. Carroll N. C:Preoperative clinical assessment of club foot. The club foot.
30. Diméglio A, Bensahel H, Souchet P, Mazeau P, Bonnet F. Classification of clubfoot. J Pediatr Orthop B. 1995;4(2):129–36.
31. Harrold AJ, Walker CJ. Treatment and prognosis in congenital clubfoot. J Bone Joint Surg Br. 1983;
32. Simons G W. Complete subtalar release in club feet. Part II--Comparison with less extensive procedures. J Bone Joint Surg Am. 1985 Sep;67(7):1056-65.
33. Sadana A, Pal CP, Dinkar KS. An Assessment of the results of Controlled Fractional Distraction by Joshi's External Stabilization System in Club Foot. Journal of Foot and Ankle Surgery (Asia Pacific). 2015;2(1):13–6.
34. Lehman WB, Atar DG, D A. Functional rating system for evaluation of the long term results of club foot surgery. The clubfoot Ed G.
35. Oganesyan OV, Istomina IS, Kuzmin VI. Treatment of equinocavovarus deformity in adults with the use of a hinged distraction apparatus. J Bone Joint Surg Am. 1996;78(4):546–56.
36. Suresh S, Ahmed A, Sharma VK. Role of Joshi's external stabilisation system fixator in the management of idiopathic clubfoot. J Orthop Surg (Hong Kong). 2003;11(2):194–201.
37. Anwar MH, Arun B. Short term results of Correction of CTEV with JESS Distractor. J Orthopaedics. 2004;1(1).
38. Singh A. Evaluation of neglected idiopathic ctev managed by ligamentotaxis using JESS: a long-term followup. Adv Orthop. 2011;2011:218489.

Volume 4, Issue 2; March-April 2021; Page No 554-561

Table 1: Pre and post operative scores and radiological assessment

	Mean	SD	Df	t	p (two-tail)
Preop DS	10.73	1.44	43	47.15	<0.001
Postop DS	3.34	1.06			
Preop TCI	22.91	5.63	43	-17.19	<0.001
Postop TCI	43.61	9.53			
Preop TFMA	24.27	6.77	43	25.99	<0.001
Postop TFMA	2.93	6.31			
Preop TCA	112.02	10.23	43	18.12	<0.001
Postop TCA	87.98	6.89			

DS –Dimeglio Score ; TCI – Talocalcaneal index ; TFMA – Talus First Metatarsal Angle ; TCA – Tibiocalcaneal angle; MTPFC – Metatarsophalangeal flexion contracture; SD – Standard Deviation; Df – Degree of freedom

Table 2: Functional evaluation as per Simon's criteria

	Satisfactory	Unsatisfactory
Symptoms	None	Mild to severe pain with normal activity
Appearance of the hind part of the foot	Normal, or mild deformity. Zero to +1	Moderate to significant residual deformity. +2 to +4
Adduction of the fore part of the foot	None to +2	+2 to +4
Foot-knee malalignment	None to +1	+2 to +4
Functional weakness of the calf (when possible to test)	None to +1 weakness, weight supported on toes	+2 to +4, cannot support weight on toes
Range of motion of the ankle	Dorsiflexion > 10 degrees, plantar flexion > 15 degrees	Dorsiflexion < 10 degrees, plantar flexion < 15 degrees
Range of motion of the subtalar joint	+3 to +1	Zero
Additional treatment needed	None, cast, or minor surgery of the fore part of the foot	Frequent treatment with a cast or major reconstructive procedure necessary
Complications	None to two minor complications, no major complications	One or more major complications

Volume 4, Issue 2; March-April 2021; Page No 554-561

Figure 1: Dimeglio classification system

Classification

Classification Grade	Type	Frequency (%)	Score
I	Benign	20	(<5)
II	Moderate	33	(=5<10)
III	Severe	35	(=10<15)
IV	Very severe	12	(=15<20)

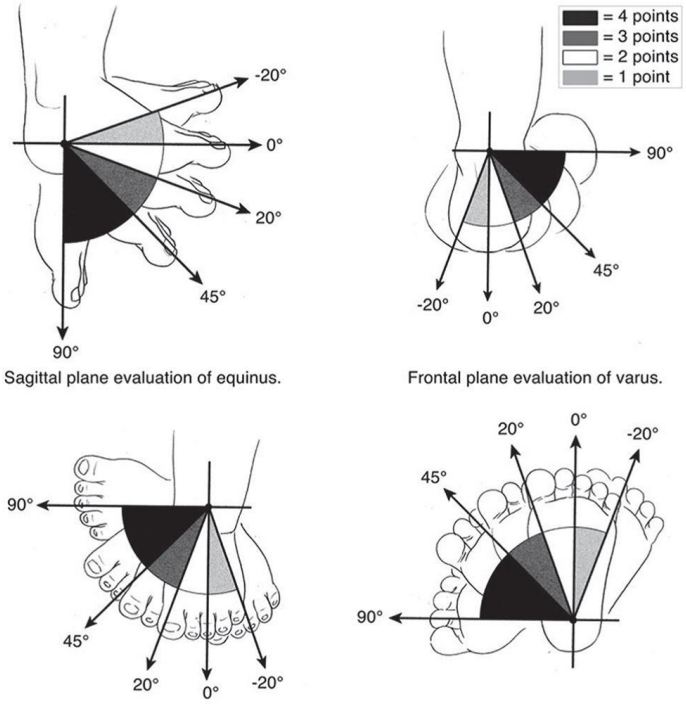

Sagittal plane evaluation of equinus.

Frontal plane evaluation of varus.

Horizontal plane evaluation of derotation of the calcaneopedal block.

Horizontal plane evaluation of forefoot relative to hindfoot.

Assessment of Clubfoot by Severity Scale

Characteristics: Reproducibility	Points	Characteristics: Other parameters	Points
90°-45°	4	Posterior crease	1
45°-20°	3	Medial crease	1
20°-0°	2	Cavus	1
<0° to -20°	1	Poor muscle condition	1

Figure 2: Radiological indices measured

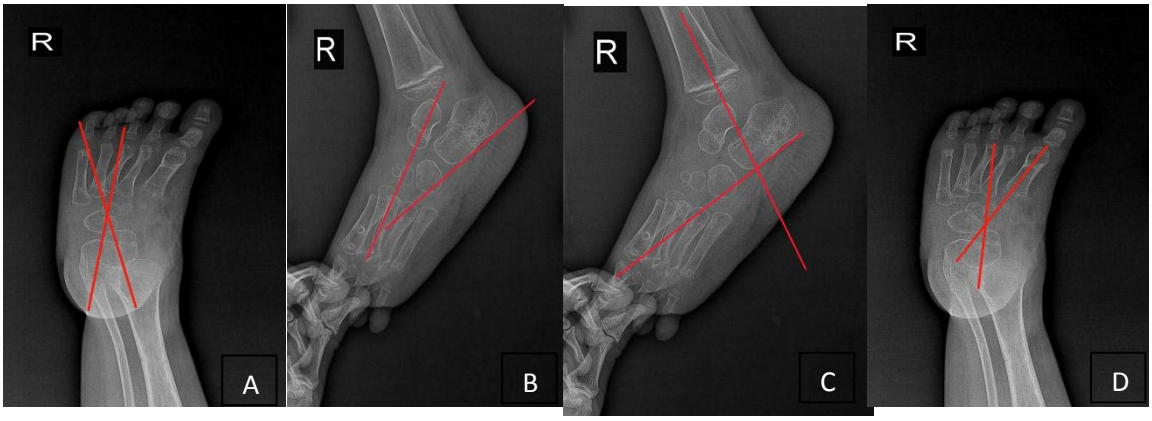

A,B Talo-calcaneal angle in AP and Lateral views, C Tibio-calcaneal angle, D Talo-1st metatarsal angle.

Volume 4, Issue 2; March-April 2021; Page No 554-561

Figure 3: Showing the placement of the posterior calcaneal wire and after complete frame application

Figure 4: Comparative analysis of pre-operative and post-operative Dimeglio score with the time taken for correction.

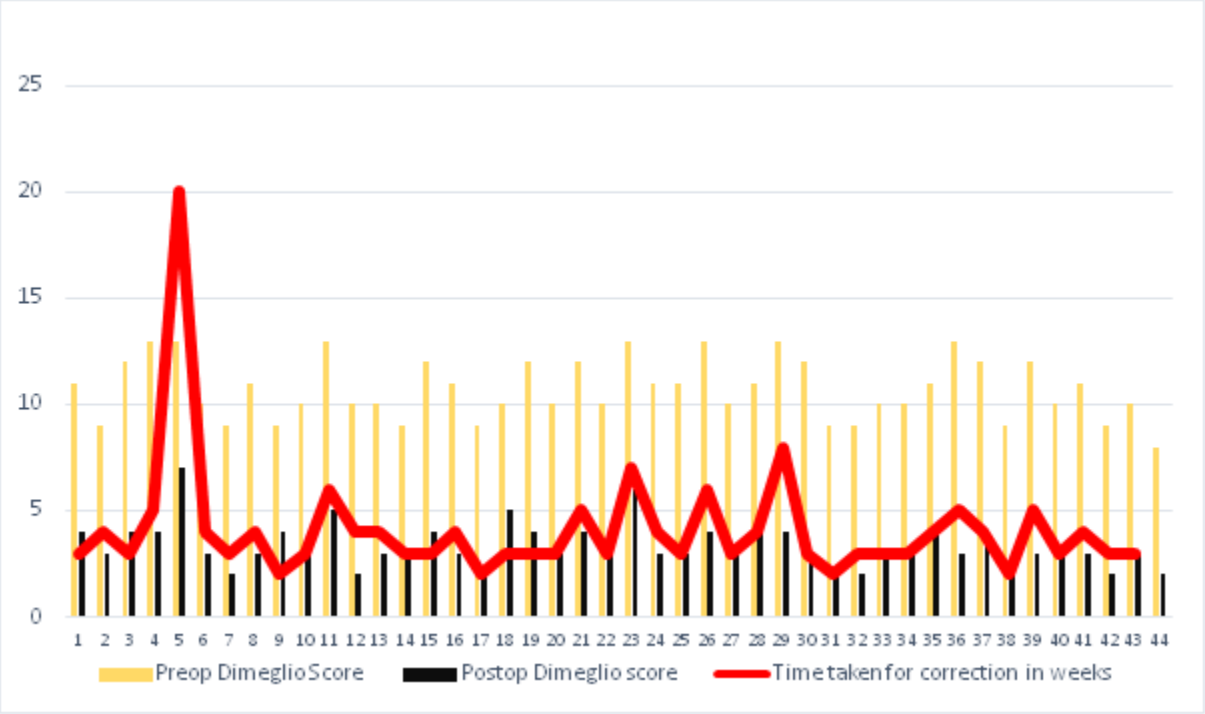

Volume 4, Issue 2; March-April 2021; Page No 554-561