(International Print/Online Journal)

SJIF IMPACT FACTOR: 5.565
PUBMED-National Library of Medicine ID-101739732

ISSN (Print): 2209-2870
ISSN (Online): 2209-2862

International Journal of Medical Science and Current Research (IJMSCR)
Available online at: www.ijmscr.com
Volume4, Issue 1, Page No: 159-165
January-February 2021

Reactive lesions of oral cavity: Clinico-pathologic evaluation of 363 cases

Dr. J.G. Humbe, Dr. N.N. Kaorey, Dr. J.D. Bhavthankar, Dr. M.S. Mandale, Dr. V.A. Nandkhedkar, Dr. S.C. Pawar
Oral Pathology and Microbiology

***Corresponding Author:**
Dr. N.N. Kaorey
133, Department of Oral Pathology and Microbiology, Government Dental college and hospital, Dhanvanthri nagar, Aurangabad-431001

Type of Publication: Case Report
Conflicts of Interest: Nil

ABSTRACT
Although reactive lesions of oral cavity do not raise any alarm when encountered in routine practice, it may sometimes prove to be a deceptive entity when the histopathology is revealed. Even on its own, they form a group of oral lesions harboring a diverse spectrum. These entities vary from an absolute benign, incipient lesion to a moderately aggressive form resulting in destruction of adjacent parenchyma. It should also be taken into consideration that several of these lesions are so alike in their clinical presentation, that histopathological evaluation is mandated in deciding their management and outcome. Owing to a recent decline in demographic studies pertaining to oral reactive lesions, this study aims to supplement and replenish the knowlwdge regarding these entities.

Keywords: oral reactive lesions, epulis, traumatic fibroma, mucosal reactive lesions, fibrous hyperplasia

INTRODUCTION

The oral cavity is susceptible to countless chronic irritating factors due to its diverse functions including its masticatory and protective role. It is exposed to diverse substances that may cause trauma and inflammation[1]. The spectrum of oral reactive lesions include focal epithelial hyperplasia, irritational fibroma, fibroepithelial polyp, epulis, peripheral ossifying fibroma and peripheral giant cell granuloma etc[2]. They often exhibit a close resemblance in their clinical appearance. These proliferations are painless masses in varying hues of pink to red that may either be pedunculated or sessile. The outward form is variable from non-ulcerated smooth to ulcerated mass. Usually the dimension ranges from a few millimetres to centimetres [2, 3].

Different studies have reported a wide variation in the distribution of data of these lesions in terms of diagnosis, site, age, gender and frequency that may provide an insight into the diagnosis of such cases [4-6]

Number of studies assessing the demographic distribution of oral reactive lesions have decreased in the past couple of years.

With this forethought, the aim of the present study was to contribute towards the current distribution data of oral reactive lesions and study its clinico-pathologic profile.

Materials and method:

The study was retrospective review of oral reactive lesions reporting to the institute. The records of patients with provisional diagnosis of oral reactive lesions for past 8 years were obtained from the departmental archives of the Institution. Age, gender, site and clinical presentation were recorded for each lesion. Histopathologic sections were independently examined by two pathologists. Final diagnosis was confirmed after histopathologic evaluation.

Inclusion criteria-

- Cases with complete clinical and histopathological records
- Cases with undefined clinical features were categorised as inflammatory fibrous hyperplasia type.

Exclusion criteria –

- Incomplete registered records and missed pathologic slides.

Data analysis was done using OpenEpi software version 3.1 using descriptive statistical method i.e. chi-square test. P-values less than 0.05 were considered statistically significant.

Results:

A total of 363 cases of oral reactive lesions were extracted. Fibroepithelial hyperplasia was the most frequently reported oral reactive lesion (n=165) followed by inflammatory fibrous hyperplasia (n=53), Pyogenic granuloma (PG) (n=49), fibroma (n=47), Peripheral giant cell granuloma (PGCG) (n=26), peripheral ossifying fibroma (POF) (n=17) and telengectatic granuloma (TG) (n=6).

Sex and Age – Table 1 shows each oral reactive lesion by sex. Out of the 363 cases considered under oral reactive lesions, 229 were females and 134 were male subjects (M:F = 1: 1.6). There was no significant gender predilection for PGCG, fibroma and TG. Whereas, a significant female predominance was noted in POF, PG, fibro-epithelial hyperplasia and inflammatory fibrous hyperplasia.

Lesions	Male	Female	Total	p value (chi square test)
PGCG	13	13	26	1.000
POF	03	14	17	0.008
Fibroma	18	29	47	0.109
PG	16	33	49	0.015
FEH	66	99	165	0.010
IFH	16	37	53	0.004
TG	02	04	06	0.414
Total	134	229	363	

Table 1: Distribution of cases as per lesion and gender

We divided the age groups as per decades, with maximum cases occurring in 3rd and 4th decades, however no statistically

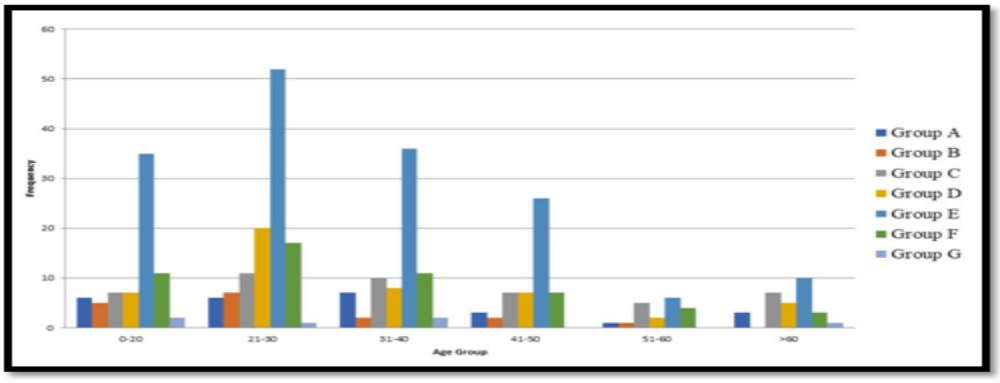

Volume 4, Issue 1; January-February 2021; Page No 159-165
© 2021 IJMSCR. All Rights Reserved

Significant difference between the age groups was noticed. (graph 1).

Graph 1: Age-wise distribution of cases

Site distribution – Gingiva was the most commonly affected site with oral reactive lesions. Out of 363 266 cases were observed on the gingiva, among which fibro-epithelial hyperplasia and inflammatory fibrous hyperplasia were the most frequent lesions (n=140 and n=47 respectively). Next frequently affected site was buccal mucosa (n=33) trailed by alveolar mucosa (n=31), palate (n=16) and lip (n=13). In our study, we found tongue to be the least affected site with n=4 (Table 2).

Site	PGCG	POF	Fibroma	PG	FEH	IFH	TG	Total
Gingiva	22	10	12	29	140	47	06	266
Buccal mucosa	00	03	18	04	07	01	00	33
Lip	00	00	08	02	03	00	00	13
Palate	02	02	03	03	05	01	00	16
Tongue	00	01	02	01	00	00	00	04
Alveolar mucosa	02	01	04	10	10	04	00	31
Total	26	17	47	49	165	53	06	363

Table2: site wise distribution of oral reactive lesions

Clinico-pathologic correlation – Although the clinical diagnosis of reactive lesions of the oral cavity was backed up by histologic findings, we came across a few instances wherein the clinical appearances proved to be misleading. We observed 9 cases which were clinically diagnosed as oral reactive lesions, conversely the histopathology depicted something far more perplexing. Table 3 includes a list of such cases.

Age/Sex	Provisional diagnosis	Final diagnosis
28/M	Fibroma	Oral focal mucinosis
50/F	Traumatic fibroma	Benign fibrous histiocytoma
50/F	Fibrous epulis	Plasma cell granuloma
65/F	Peripheral giant cell granuloma	Melanoma
75/M	Denture irritation fibroma	Squamous cell carcinoma secondary to lung metastasis
17/M	Pyogenic granuloma	Plasmablastic lymphoma
70/M	Denture irritation fibroma	Oral tuberculosis
59/F	Giant cell granuloma	Primary Intraosseous carcinoma
19/F	Peripheral ossifying fibroma	Peripheral adenomatoid odontogenic tumor

Volume 4, Issue 1; January-February 2021; Page No 159-165

© 2021 IJMSCR. All Rights Reserved

31/F	Gingival epulis	Peripheral calcifying epithelial odontogenic tumor
64/M	Traumatic fibroma	Peripheral odontogenic keratocyst
30/F	Peripheral giant cell granuloma	Peripheral ameloblastoma
42/M	Epulis	Odontogenic myxoma

Table 3: List of provisional and final diagnosis of cases that clinically presented as oral reactive lesions but were histopathologically diagnosed as diverse entities

Discussion:

As deduced from the numbers stated below, biopsies of the oral reactive lesions form a significant chunk of the routine oral

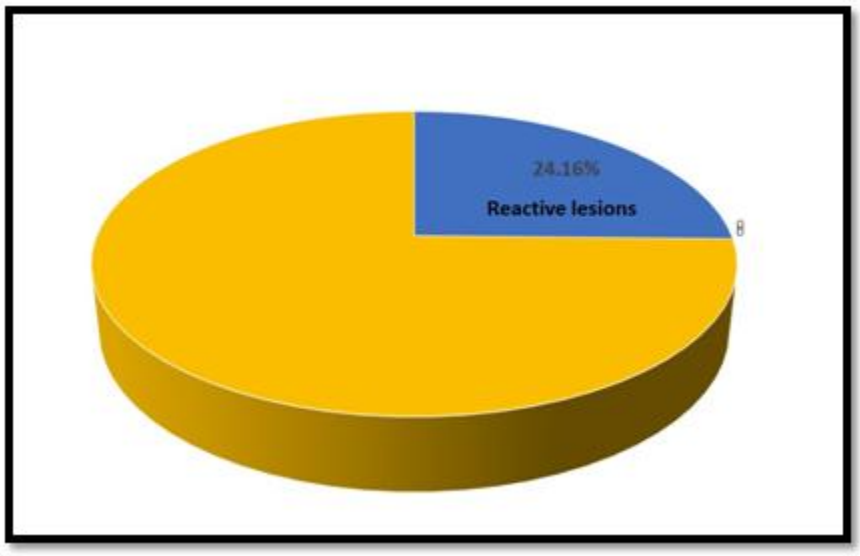

Pathology practice. It was observed that reactive lesions comprised of 24.16% of the total reported cases in our department (graph 2). Thus, the present study was undertaken with the intention of having a detailed analysis of the clinic-pathologic presentation of these lesions.

Graph 2 : Distribution of cases and share of oral reactive lesions among the reported cases of the institution

Reactive lesions of the oral cavity broadly encompass group of fibrous connective tissue and sometimes epithelial lesions that commonly occur in the oral mucosa as a result of injury or chronic irritation. Granulation tissue formation due to chronic trauma can induce inflammation which manifests in form of mucosal overgrowth. These tumour-like lesions are not neoplastic, but they indicate a chronic process of exaggerated repair which sometimes may mimic the neoplasm by which they differ in behaviour and treatment [7, 8].

The age distribution of patients affected by oral reactive lesions was quite diverse in our study which was similar to the observations by other authors on the case[9]. Individuals in 3rd and 4th decades of life made up majority of the study population in our reports which was analogous to the findings of Reddy V et al(2012) [7] and Awange DO et al (2009)[10].

We also observed an increased female predisposition for such cases with the Female: male ratio being about 1.6:1 which bore a close resemblance to the values put forth by Aghbali AA et al (2010) which was 1.8: 1 [11] and Effiom OA et al (2011) which was 1.7:1 [12]. From our data, we found that the significant gender predilection was seen only in POF, PG, fibro-

Volume 4, Issue 1; January-February 2021; Page No 159-165
© 2021 IJMSCR. All Rights Reserved

epithelial hyperplasia and inflammatory fibrous hyperplasia which was consistent with the findings of Effiom OA et al (2011) and Kfir Y et al (1980)[13] . Thus, the predisposition towards females may be an attribute in favour of hormonal etiology.

Our observation regarding fibro-epithelial hyperplasia being the most common oral reactive lesion was supported by the findings of Buchner A et al (2010) [14]. Whereas, Nader NJ et al (2012) reported Peripheral giant cell granuloma as the most prevalent lesion followed by pyogenic granuloma[4].

Gingiva was the most frequently associated site with respect to oral reactive lesions in our study followed by buccal and alveolar mucosa, palate lip and lastly, tongue. Kadeh H et al (2015) and Pour H et al (2008) also observed consistent findings in terms of anatomic distribution. The occurrence of these lesions in the gingiva indicates that reactive lesions may possibly arise from the periodontal ligament and connective tissue. Moreover, aggregation of bacterial plaque and food particles within the interdental region may expose the gingiva to persistent irritation [15, 16].

A step ahead of the oral reactive lesions is the seldom encountered unusual presentations. We came across few scenarios wherein the histopathological evaluation of oral mucosal swellings resembling reactive lesions varied from focal mucinosis to squamous cell carcinoma and also malignant melanoma. Mariani G et al reported one such localised gingival swelling that was histologically proven to be oral melanocytic nevus [17]. Similarly, Manor Y et al presented 3 different cases of odontogenic tumors that mimicked localised gingival swellings[18]. Our records demonstrated more of such bizarre cases wherein, oral tuberculous lesion presented clinically as denture irritation hyperplasia and Plasma cell granuloma as an epulis (figure1). On similar grounds , A case of Plasmablastic lymphoma was clinically misdiagnosed as pyogenic granuloma and Squamous cell carcinoma secondary to lung metastasis presented as denture irritation fibroma (figure 2). These occurrences have demonstrated the dire need for subjecting the seemingly benign cases for histopathologic evaluation.

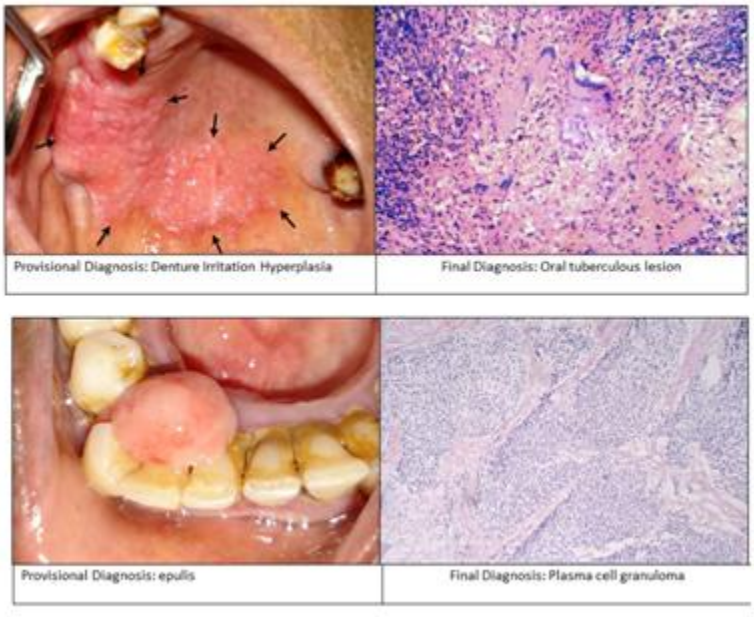

Figure 1: Cases of oral tuberculous lesion misdiagnosed as denture irritation hyperplasia and Plasma cell granuloma misdiagnosed as Epulis

Volume 4, Issue 1; January-February 2021; Page No 159-165
© 2021 IJMSCR. All Rights Reserved

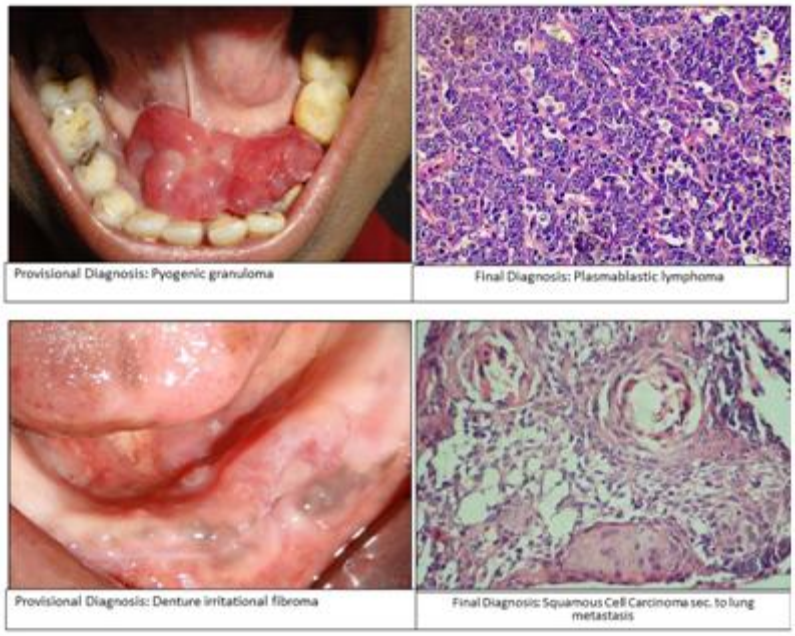

Figure 2: Cases of Plasmablastic lymphoma misdiagnosed as pyogenic granuloma and Squamous cell carcinoma secondary to lung metastasis misdiagnosed as denture irritation fibroma

Conclusion:

The purview of oral reactive lesions includes a wide array of clinico-pathologic factors that dictate their form and biologic behaviour. Hence, an understanding of these factors may enable dentists to make a sound clinical diagnosis that is necessary for a comprehensive treatment planning. Along the same lines, it is also vital to stress upon the importance of histologic examination of all such reactive oral lesions that a dentist may come across, no matter how benign and insignificant appearance they may project. As, these lesions may be deceiving regarding their true nature.

References:

1. AO Akinyamoju, BF Adeyemi, B Kolude. Localized Reactive Lesions Of The Oral Cavity: A Review Of 246 Cases In Ibadan. The Internet Journal of Dental Science. 2013;12(1). Corpus ID: 79263323
2. Neville BW, Damm DD, Allen CM, Bouquot JE. Oral and maxillofacial pathology. 3rd ed. China: Saunders; 2009. pp. 510–23.
3. Regezi JA, Sciubba JJ, Jordan RCK. Oral pathology: Clinical pathologic correlations. 5th ed. China: Saunders; 2008. pp. 156–60.
4. Naderi NJ, Eshghyar N, Esfehanian H. Reactive lesions of the oral cavity: A retrospective study on 2068 cases. Dent Res J (Isfahan). 2012;9(3):251-5.
5. Salum FG, Yurgel LS, Cherubini K, De Figueiredo MA, Medeiros IC, Nicola FS. Pyogenic granuloma, peripheral giant cell granuloma and peripheral ossifying fibroma: Retrospective analysis of 138 cases. Minerva Stomatol. 2008;57:227–32
6. Awange DO, Wakoli KA, Onyango JF, Chindia ML, Dimba EO, Guthua SW. Reactive localised inflammatory hyperplasia of the oral mucosa. East Afr Med J. 2009;86:79–82.
7. Reddy V, Saxena S, Saxena S, Reddy M. Reactive hyperplastic lesions of the oral cavity: A ten year observational study on North Indian Population. J Clin Exp Dent. 2012 Jul 1;4(3):e136-40. doi: 10.4317/jced.50670. PubMed PMID: 24558543; PubMed Central PMCID: PMC3917636.
8. Shadman N, Ebrahimi SF, Jafari S, Eslami M. Peripheral giant cell granuloma: a review of 123 cases.Dent Res J (Isfahan). 2009 Spring; 6(1):47-50.

Volume 4, Issue 1; January-February 2021; Page No 159-165
© 2021 IJMSCR. All Rights Reserved

9. Zarei, M. R., Chamani, G., & Amanpoor, S. (2007). Reactive hyperplasia of the oral cavity in Kerman province, Iran: A review of 172 cases. British Journal of Oral and Maxillofacial Surgery, 45(4), 288–292.

10. DO Awange, KA Wakoli, JF Onyango, ML Chindia, EO Dimba, SW Guthua. Reactive Localised Inflammatory Hyperplasia Of The Oral Mucosa. East African Medical Journal, 2009; 86(2):79-82.

11. Aghbali AA, Hosseini SV, Harasi B, Janani M, Mahmoudi SM. Reactive hyperplasia of the oral cavity: a survey of 197 cases in Tabriz, Northwest Iran. Journal of Dental Research, Dental Clinics, Dental Prospects. 2010;4(3):87.

12. Effiom OA, Adeyemo WL, Soyele OO. Focal reactive lesions of the gingiva: an analysis of 314 cases at a tertiary health institution in Nigeria. Nigerian medical journal: journal of the Nigeria Medical Association. 2011 Jan;52(1):35.

13. Kfir Y, Buchner A, Hansen LS. Reactive lesions of the gingiva: a clinicopathological study of 741 cases. Journal of periodontology. 1980 Nov;51(11):655-61.

14. Buchner A, Shnaiderman-Shapiro A, Vered M. Relative frequency of localized reactive hyperplastic lesions of the gingiva: a retrospective study of 1675 cases from Israel. Journal of oral pathology & medicine. 2010 Sep;39(8):631-8.

15. Kadeh H, Saravani S, Tajik M. Reactive hyperplastic lesions of the oral cavity. Iran J Otorhinolaryngol. 2015 Mar;27(79):137-44. PubMed PMID: 25938085; PubMed Central PMCID: PMC4409958.

16. Hashemi Pour MA, Rad M, Mojtahedi A. A survey of soft tissue tumor-like lesions of oral cavity: a clinicopathological study. Iranian Journal of Pathology. 2008;3(2):81–7.

17. Mariani G, Astolfi F, Trapani A, Varoni E, Decani S. Uncommon gingival swelling. Ann Stomatol (Roma). 2013 Oct 24;4(Suppl 2):26. PubMed PMID: 24353792; PubMed Central PMCID: PMC3860255.

18. Manor Y, Merdinger O, Katz J, Taicher S. Unusual peripheral odontogenic tumors in the differential diagnosis of gingival swellings. Journal of clinical periodontology. 1999 Dec;26(12):806-9.

Volume 4, Issue 1; January-February 2021; Page No 159-165

© 2021 IJMSCR. All Rights Reserved