(International Print/Online Journal)

SJIF IMPACT FACTOR: 5.565
PUBMED-National Library of Medicine ID-101739732

ISSN (Print): 2209-2870
ISSN (Online): 2209-2862

International Journal of Medical Science and Current Research (IJMSCR)
Available online at: www.ijmscr.com
Volume3, Issue 6, Page No: 830-845
November-December 2020

VASCULITIS – Myriads of presentation

Sruthi Meenaxshi.S.R, Rai.M
Department of Internal Medicine, Institute of Medical Sciences, BHU, Varanasi

***Corresponding Author:**
Sruthi Meenaxshi.S.R
Department of Internal Medicine, Institute of Medical Sciences, BHU, Varanasi

Type of Publication: Review Article
Conflicts of Interest: Nil

ABSTRACT:

Vasculitis has a myriad spectrum of clinical presentation which serves as a diagnostic challenge for physicians and justifies an integrated approach to management. Conceptualizing vasculitic disease based on vessel size, site and organ involvement can be useful, but it is not an absolute definition. It still remains very crucial for the physician to diagnose the disease early so that therapeutic measures can be taken in order to prevent the complications, sequelae and mortality associated with it.

Keywords: vasculitis, presentation

INTRODUCTION

Vasculitis refers to a heterogenous group of disorders in which there is inflammation and damage in blood vessel walls, leading to tissue necrosis. These are relatively uncommon disorders, with a reported annual incidence of 40 to 54 cases per 1 million persons. Primary vasculitic disorders account for less than 1% cases seen in a rheumatology clinic. The incidence appears to be affected by geography, age, and seasonal challenges. Vasculitis may be limited to skin or other organs, or may be a multisystem disorder with multiple manifestations.

History and Evolution of Classification system :

Numerous classifications of vasculitis have been proposed. The American College of Rheumatology has classification criteria for seven primary vasculitides and did not include antineutrophilic cytoplasmic antibody (ANCA) testing for the diagnosis of small vessel vasculitis or require biopsy or angiography for vasculitis classification. The criteria have poor reliability when applied as diagnostic criteria. In 1994, the Chapel Hill Consensus Conference proposed a nomenclature based on vessel size (large, medium, and small and revised in the 2012 CHCC.

Table 1: Definitions for vasculitides adopted by the 2012 International Chapel Hill Consensus Conference on the Nomenclature of Vasculitides (CHCC2012)

CHCC2012 nomenclature	CHCC2012 definition
Large-vessel vasculitis	Vasculitis affecting large arteries more often than other vasculitides. Large arteries are the aorta and its major branches. Any size artery may be affected. Arteritis, often granulomatous, predominantly affecting the aorta and/or its major branches. Onset usually in

Takayasu arteritis (TAK)	patients younger than 50 years.Associated with HLA B*52. Pulseless disease.
Giant cell arteritis (GCA)	Arteritis, often granulomatous, usually affecting the aorta and/or its major branches, with a predilection for the branches of the carotid and vertebral arteries. Often involves the temporal artery. Onset usually in patients older than 50 years and often associated with polymyalgia rheumatica. Familial aggregation and has association with HLADR4.
Medium-vessel vasculitis	Vasculitis predominantly affecting medium arteries defined as the main visceral arteries and their branches. Any size artery may be affected. Inflammatory aneurysms and stenosis are common.
Polyarteritis nodosa (PAN)	Necrotizing arteritis of medium or small arteries without glomerulonephritis or vasculitis in arterioles, capillaries, or venules, and **not associated with antineutrophil cytoplasmic antibodies (ANCAs).**
Kawasaki disease (KD)	Arteritis associated with the mucocutaneous lymph node syndrome and predominantly affecting medium and small arteries. Coronary arteries are often involved. Aorta and large arteries may be involved. Usually occurs in infants and young children.
Small-vessel vasculitis	Vasculitis predominantly affecting small vessels, defined as small intraparenchymal arteries, arterioles, capillaries, and venules. Medium arteries and veins may be affected.
ANCA-associated vasculitis (AAV)	Necrotizing vasculitis, with few or no immune deposits, predominantly affecting small vessels. Associated with myeloperoxidase (MPO) ANCA or proteinase 3 (PR3) ANCA. Not all patients have ANCA. Add a prefix indicating ANCA reactivity, eg, MPO-ANCA, PR3-ANCA, ANCA-negative.
	Necrotizing vasculitis, with few or no immune deposits, predominantly affecting small vessels. Necrotizing

Volume 3, Issue 6; November-December 2020; Page No 830-845

Microscopic polyangiitis (MPA)	arteritis involving small and medium arteries may be present. Necrotizing glomerulonephritis is very common. Pulmonary capillaritis often occurs. **Granulomatous inflammation is absent. P-ANCA is present in > 90 % patients with MPA.**
Granulomatosis with polyangiitis (Wegener's) (GPA)	Necrotizing granulomatous inflammation usually involving the upper and lower respiratory tract, and necrotizing vasculitis affecting predominantly small to medium vessels. Necrotizing glomerulonephritis is common. ANCA is present in >80 % patients with GPA. Associated with the HLA-DPB1*0401 allele, the PI*Z allele of SERPINA1 and the PRTN3 gene.
Eosinophilic granulomatosis with polyangiitis (Churg-Strauss) (EGPA)	Eosinophil-rich and necrotizing granulomatous inflammation often involving the respiratory tract, and necrotizing vasculitis predominantly affecting small to medium vessels, and associated with asthma and eosinophilia. ANCA is more frequent when glomerulonephritis is present.ANCA is present in 40 % of patients with EGPA,usually anti MPO ANCA.
Immune complex vasculitis	Vasculitis with moderate to marked vessel-wall deposits of immunoglobulin and/or complement components predominantly affecting small vessels (ie, capillaries, venules, arterioles, and small arteries). **Glomerulonephritis is frequent.**
Anti-glomerular basement membrane (anti-GBM) disease	Vasculitis affecting glomerular capillaries, pulmonary capillaries, or both, with GBM deposition of anti-GBM autoantibodies. Lung involvement causes pulmonary hemorrhage, and renal involvement causes glomerulonephritis with necrosis and crescents.
Cryoglobulinemic vasculitis (CV)	Vasculitis with cryoglobulin immune deposits affecting small vessels and associated with serum cryoglobulins. Skin, glomeruli, and peripheral nerves are often involved.Associated with Hepatitis C infection and haematological malignancies. Vasculitis, with IgA1-dominant immune deposits, affecting small vessels. Often involves skin and gastrointestinal tract, and frequently causes arthritis. Glomerulonephritis indistinguishable from IgA nephropathy may occur.

Volume 3, Issue 6; November-December 2020; Page No 830-845

IgA vasculitis (Henoch-Schönlein) (IgAV) **Hypocomplementemic urticarial vasculitis (HUV) (anti-C1q vasculitis)**	Vasculitis accompanied by urticaria and hypocomplementemia affecting small vessels and associated with anti-C1q antibodies. Glomerulonephritis, arthritis, obstructive pulmonary disease, and ocular inflammation are common.
Variable-vessel vasculitis	Vasculitis with no predominant type of vessel involved that can affect vessels of any size (small, medium, and large) and type (arteries, veins, and capillaries).
Behçet's syndrome	Vasculitis occurring in patients with Behçet's syndrome that can affect arteries or veins. Behçet's syndrome is characterized by recurrent oral and/or genital aphthous ulcers accompanied by cutaneous, ocular, articular, gastrointestinal, and/or central nervous system inflammatory lesions. Small-vessel vasculitis, thromboangiitis, thrombosis, arteritis, and arterial aneurysms may occur. Associated with HLA B*51. Pathergy test positive.
Cogan's syndrome	Vasculitis occurring in patients with Cogan's syndrome. Cogan's syndrome is characterized by ocular inflammatory lesions, including interstitial keratitis, uveitis, and episcleritis, and inner ear disease, including sensorineural hearing loss and vestibular dysfunction. Vasculitic manifestations may include arteritis aortitis, aortic aneurysms, and aortic and mitral valvulitis.
Single-organ vasculitis Vasculitis	in arteries or veins of any size in a single organ that has no features that indicate that it is a limited expression of a systemic vasculitis. The involved organ and vessel type should be included in the name (eg, cutaneous small-vessel vasculitis, testicular arteritis, central nervous system vasculitis).
Vasculitis associated with systemic disease	Vasculitis that is associated with and may be secondary to (caused by) a systemic disease (eg, rheumatoid vasculitis, lupus vasculitis, etc).
Vasculitis associated with probable etiology	Vasculitis that is associated with a probable specific etiology. eg, hydralazine-associated microscopic polyangiitis, hepatitis B virus-associated vasculitis, hepatitis C virus-

Volume 3, Issue 6; November-December 2020; Page No 830-845

associated cryoglobulinemic vasculitis, etc).

Jennette JC, Falk RJ, Bacon PA, et al. 2012 revised International Chapel Hill Consensus Conference Nomenclature of Vasculitides. Arthritis Rheum 2013; 65:1. Reproduced with permission from John Wiley & Sons, Inc. Copyright © 2013 by the American College of Rheumatology. All rights reserved

A major international effort is now under way to use data-driven methods to develop both a revised single classification system for the vasculitides and a validated set of diagnostic criteria for the vasculitides in accordance with standards established by the ACR and the European League Against Rheumatism (EULAR); the study is named 'Diagnosis and Classification of Vasculitis (DCVAS)', and is supported by grants from the Vasculitis Foundation, the American College of Rheumatology (ACR) and the European League Against Rheumatism (EULAR).

Figure 1: Schematic representation of Classification of Vasculitis

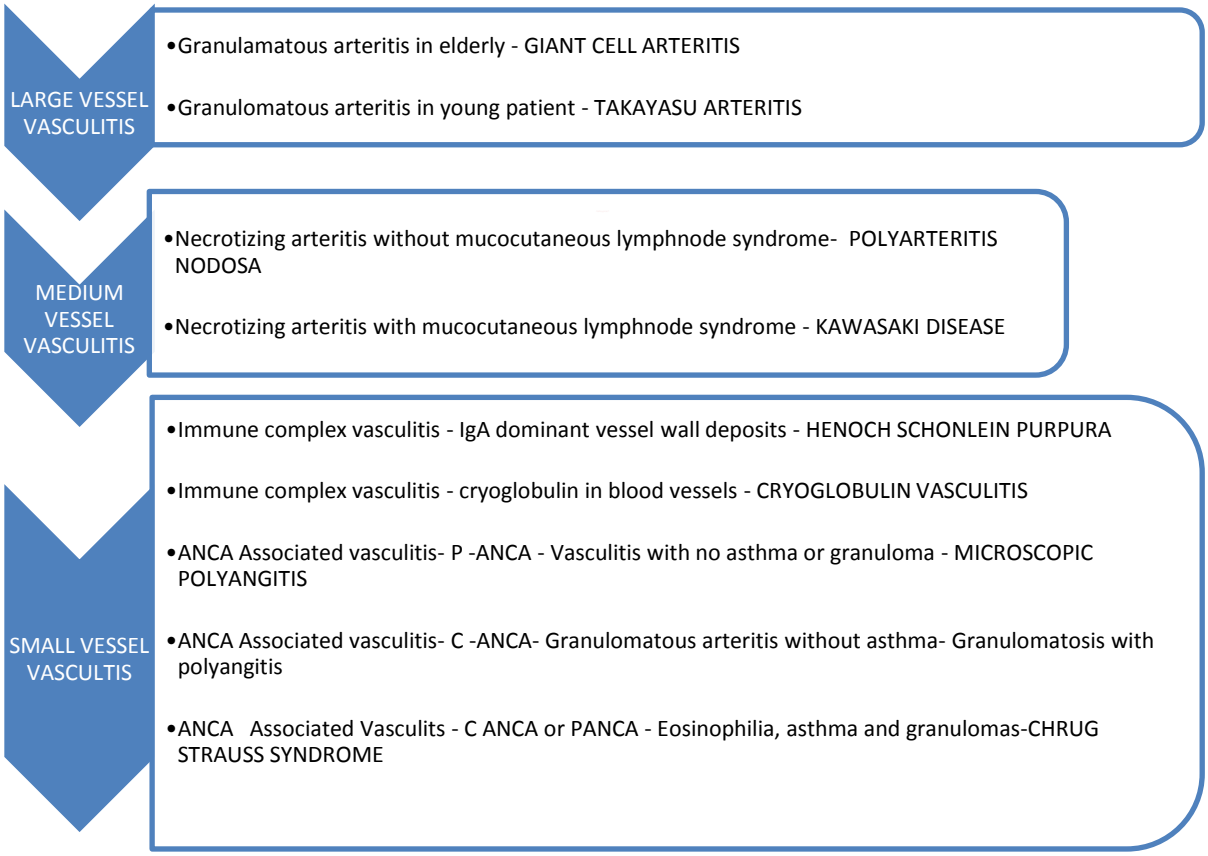

When to suspect vasculitis?

The cutaneous and systemic features of vasculitides are not pathognomonic of these conditions in most of the cases. However, certain cutaneous features like palpable purpura, punched-out ulcers, livedo reticularis, and subcutaneous nodules with or without certain systemic features like abdominal angina, glomerulonephritis,

Volume 3, Issue 6; November-December 2020; Page No 830-845

recurrent sinusitis, pneumonitis, peripheral neuropathy may point to a vasculitic etiology. There are certain conditions mimicking cutaneous or systemic vasculitis which have to be excluded.

Table 2 : Clinical Features That Raise Suspicion of Vasculitis

CLINICAL FEATURE	*PRESENTING SIGNS*	*TYPE OF VASCULITIS*
Constitutional symptoms	Fever, fatigue, malaise, anorexia, weight loss	Any type of vasculitis
Polymyalgia rheumatica	Proximal muscle pain with morning stiffness	Giant cell arteritis (34%); less commonly, other vasculitides
Nondestructive oligoarthritis	Joint swelling, warmth, painful range of motion	Polyarteritis (64%), Wegener's granulomatosis(67%),behcets disease(50 %)
Skin lesions	Livedo reticularis, necrotic lesions, ulcers, nodules, digital tip infarcts	Polyarteritis(43%),MPA(44%) henoch schonlein purpura, churg strauss syndrome (51%), hypersensitivity vasculitis, behcets disease (80%)
	Palpable purpura	Any type of vasculitis except giant cell arteritis and Takayasu's arteritis
Multiple mononeuropathy (mononeuritis multiplex)	Injury to two or more separate peripheral nerves (e.g., patient presents with both right foot drop and left wrist drop)	Polyarteritis(51%), Churg-Strauss vasculitis(72%), Wegener's granulomatosis, cryoglobulinemia
Renal involvement	Ischemic renal failure related to arteritis	Affected in most of vasculitis except TAK. Renin mediated hypertension is present in PAN Wegener's granulomatosis, MPA(100%)
	Glomerulonephritis	Microscopic polyangiitis, Wegener's granulomatosis(77%), cryoglobulinemia- MPGN (80 %), Churg-Strauss vasculitis, Henoch-Schönlein purpura Absent in classical PAN
Central nervous system	Headache Cerebro vascular accident , seizure, altered mental	GCA(76%) Takayasu's arteritis (10%),MPA(28%),PAN(23%),neuro

Volume 3, Issue 6; November-December 2020; Page No 830-845

	status	behcets , Primary CNS vasculitis
Cardiovascular	Myocardial infarction Ischemic cardiomyopathy (congestive heart failure Pulselessness	Kawasaki s disease Takayasu arteritis PAN(36 %)
Lungs	Alveolar hemorrhage Bilateral lung opacities Nodules with or without cavities Infarction	Wegener granulomatosis (66%) Churg strauss disease Microscopic polyangitis(50%)
Ocular	Scleritis , episcleritis Uveitis ,Blindness – Anterior ischemic optic neuropathy Interstitial keratitis	Wegeners granulomatosis (16%) Giant cell arteritis (15-24%) Behcets disease (50%) Cogans syndrome
Gastrointestinal	Ischemic mucosal necrosis of bowel hemetemesis and malena Pancreatic and hepatic infarction	Polyarteritis nodosa Henoch scholein purpura (70%)
Genitourinary	Testicular pain and epididymo orchitis Genital ulceration	Polyarteritis nodosa(25%) Behcets disease

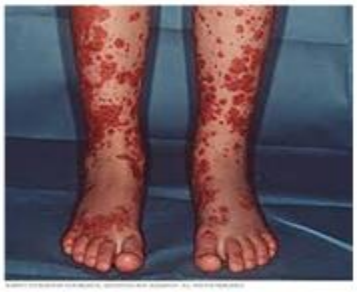

Figure 3: Henoch schonlein purpura showing recent onset purpuric rashes over the legs with coalescence of lesions

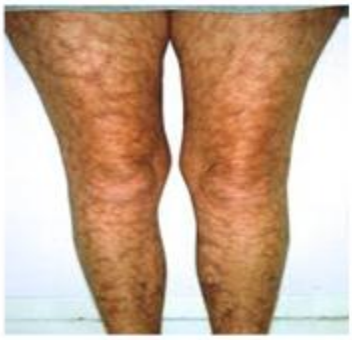

Figure 4 : livedo reticularis in a patient with Polyarteritis nodosa

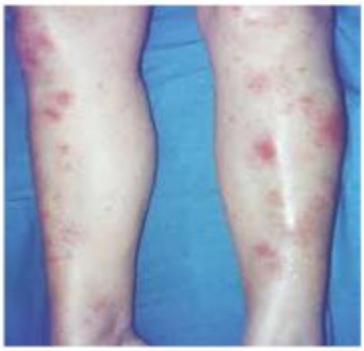

Figure 5: Erythema nodosum like lesion in case of behcet's disease

Volume 3, Issue 6; November-December 2020; Page No 830-845

Constitutional symptoms like fever, weight loss , malaise , arthralgia or arthritis is common to all "large" generally denotes the aorta and the major branches (eg. Subclavian and carotid arteries)

"Medium" refers to vessels that are smaller than the major aortic branches , yet large enough to contain four elements initima , continuous internal elastic lamina , muscular media , and an adventitia " Small" vessels include capillaries , post capillary venules and arterioles . such vessels are typically less than 500 µ in outer diameter. Since Glomeruli have capillaries , small vessel vasculitis are associated with Glomerulonephritis

Capillaries in lung may lead alveolar hemorrhage

Table 3: Vasculitis Triggers

Triggers	Vasculitis
HBsAg	PAN
Staph Aureus	WG
Gr A Streptococci and mycoplasma	HSP
Hepatitis C	Essential cryoglobinemia
Drugs	Cutaneous Leucocytoclastic vasculitis

Table 4: Conditions that can mimic systemic vasculitis :

Infectious diseases:

Bacterial Endocarditis

Disseminated gonococcal infection

Pulmonary Histoplasmosis

Coccidiomycosis

Syphilis

Lyme's disease

Rocky mountain Spotted fever

Whipples disease

Coagulopathies and thrombotic microangiopathies

Antiphospholipid syndrome

Thrmobotic thrombocytopenic syndrome

Neoplasm:

Atrial myxoma

Lymphoma

Drug toxicity (cocaine , levimisole , amphetamine , ergot,methysergide ,arsenic)

Sarcoidosis

Atheroembolic disease

Amyloidosis

Migraine

Laboratory diagnosis:

1. General Laboratory Findings: Acute inflammatory markers, such as erythrocyte sedimentation rate (ESR), CRP, and white blood cell (WBC) count, may be present. In cases with eosinophilic granulomatosis with polyangiitis (EGPA), a significant increase in eosinophil is observed. At times, high level of plasma renin activity or HBV antigen positivity can be seen in a patient with polyarteritis nodosa (PAN).

2. Urinalysis: Even in its early stage, proteinuria, erythruria, leukocyturia, and cylindruria can be found in patients with microscopic polyangiitis (MPA). However, in PAN and granulomatosis with polyangiitis (GPA), there are cases in which abnormal urinary findings appear over time rather than immediately.

3. Biochemical markers: In MPA, PAN, and GPA, renal dysfunction, such as elevation of serum creatinine, a rise in BUN, and a decline in creatinine clearance, can be observed. As interstitial pneumonia is one of representative clinical features in MPA, a

Volume 3, Issue 6; November-December 2020; Page No 830-845

rise in **KL-6** can also be seen. Tam et al, investigated urinary **monocyte chemoattractant protein 1** (MCP-1) and fractalkine as a potential non-invasive biomarkers for renal vasculitisin adults with AAV. Recently, O' Reilly et al. suggested that **urinary soluble CD163** (sCD163) may provide an even better biomarker of renal vasculitis than urinary MCP -1.

4. Antineutrophil cytoplasmic antibody (ANCA): In MPA and EGPA, it is common (50%-80% of cases) to detect myeloperoxidase (MPO)- ANCA (perinuclear [p] staining pattern with an indirect immunofluorescent [IIF] assay, p-ANCA). Antineutrophil cytoplasmic antibody testing is usually negative in PAN (< 20 % ANCA positive). In GPA ,proteinase 3 (PR3)- ANCA (cytoplasmic (c) staining pattern with IIF assay , C –ANCA) is positive (90%). Atypical staining (A or X ANCA) ie mixed fluorescence pattern an antibodies directed against lactoferrin and elastase of the neutrophil show high association with drug induced vasculitis (Choi HK et al, 2000).In recent years, genetic factors, biological environment factors ,the induction of neutrophil extracellular traps [NETs] from neutrophil caused by bacterial infection , scientific environment factors ,antithyroid drugs such as propyl thiouracil , atmospheric environmental chemicals such as silica have been presumed as causes of ANCA positivity. Detailed history taking via an interview is highly important to distinguish primary vasculitis from genetic or environmental factor associated vasculitis in a patient with positive ANCA and equivocal clinical features of vasculitis. Circulating antibodies against α-enolase of endothelial cells, selenium binding protein and anti-saccharomyces cerevisiae is observed in behcets disease.

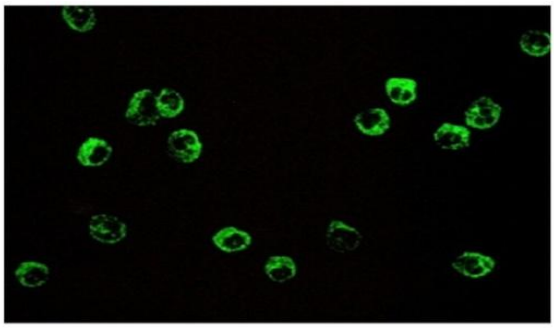

Figure 6 : C- ANCA - cytoplasmic pattern Anti proteinase 3 (PR3 ANCA) by Indirect immunofluorescence assay

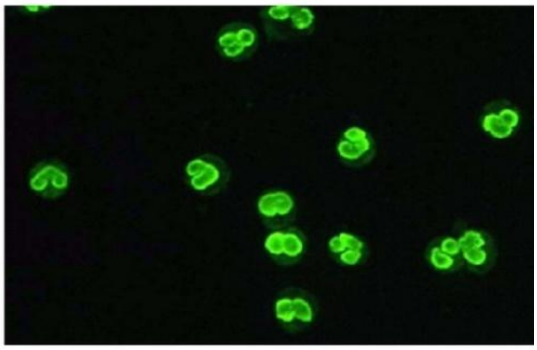

Figure 7 : P – ANCA perinuclear pattern antimyeloperoxidase MPO ANCA) by Indirect immunofluorescence assay

5. Antiglomerular basement membrane (GBM) antibody: Especially in cases exhibiting RPGN and /or alveolar hemorrhage, it is essential to suspect anti GBM disease. Serum anti – GBM antibody is specific to laboratory findings for anti – GBM disease. Although there are various methods to detect anti-GBM antibody , such as the IIF assay, hemagglutination assay, radioimmunoassay (RIA) method, and enzyme – linked immunoassay (ELISA) method, the RIA and ELISA method have superior sensitivity (>95 %) and specificity(>97 %).

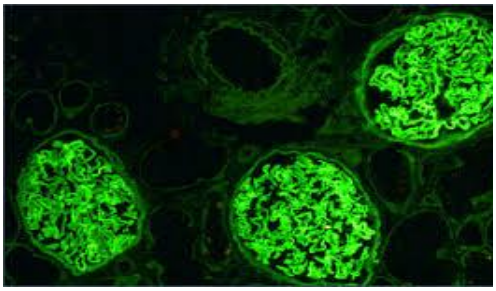

Volume 3, Issue 6; November-December 2020; Page No 830-845

6. Imaging study: Plain radiographs of the chest and paranasal sinuses, ultrasonography, CT, MRI, and thermography have been used to confirm abnormal vascular wall structure and blood flow dysfunction. If acute-phase Takayasu disease (TAK) is present, aortic wall thickening will be densely stained with gadolinium on contrast-enhanced MRI. As MRA can clearly outline whether or not there are any irregularities, contractions, or occlusion of the vascular walls, this imaging modality is often useful for interpretation of symptoms related to ischemia. Further, it may be possible to localize aortic inflammation using 18F-fluorodeoxyglucosepositron emission tomography (FDG-PET). Increased glycolytic metabolism in inflammatory tissues or malignant tumors is the rationale behind the common use of FDG-PET.Diagnostic imaging studies of the thorax (X-rays, CT, MRI) may show interstitial infiltrative shadows in the lung field in a patient with MPA. Granulomatous lesions can also be accompanied by infiltrative shadows in patients with EGPA and GPA. PAN can cause multiple microaneurysms and/or contractions in association with inflammation of medium-sized and small arteries. Aneurysms can be frequently detected in the branches of the abdominal aorta (eg, renal, mesenteric, and hepatic arteries) and can be confirmed via angiography. However, aneurysms are usually not detected during the acute phase. In some cases, it is possible to detect impaired blood flow using MRA or the ultrasonic Doppler method. However, in Japan, some physicians tend to avoid conventional angiography because of its invasiveness and because PAN can typically be diagnosed via biopsy. In PACNS characteristic abnormality is 'string of beads' pattern produced by segmental arterial narrowing alternating with dilations.

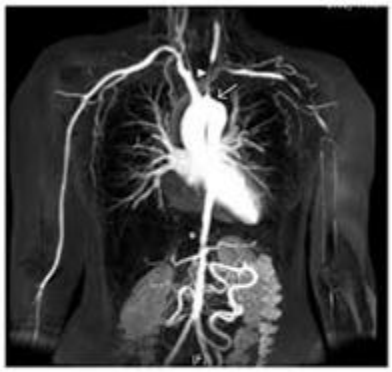

Figure 9 : MR angiogram showing stenotic left common carotid in Takayasu 's arteritis .

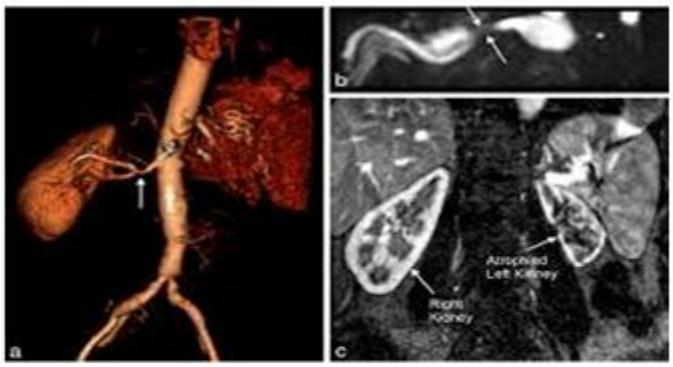

Figure 10 . Takayasu 's arteritis 3D-reconstruction of a contrast-enhanced MRA demonstrating absence of the left renal artery (prior occlusion), and an apparent severe stenosis of the proximal right renal artery (white arrow).

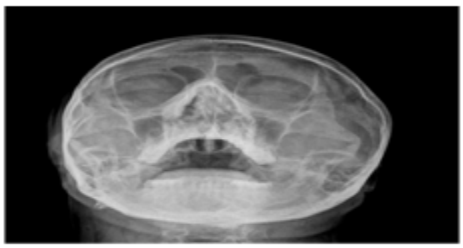

Figure 11 : X ray PNS waters view of patient of wegeners granulomatosis with extensive soft tissue opacification of nasal cavities and thinning of nasal septum.

Volume 3, Issue 6; November-December 2020; Page No 830-845

Xray Chest : In WG, multiple bilateral and chronic (>1 month) fixed, solid nodules and cavities, while in CSS and MPA diffuse and migratory non cavitary infiltrates may be seen. ANCA associated vasculitis (AAV) may be complicated by intra alveolar hemorrhage leading to extensive, evanescent bilateral lung infiltrates.

Computed Tomography of lungs may show nodules, cavities and granuloma in WG and infiltrates in CSS and MPA. Peripheral, bilateral ground glass opacities / alveolar haemorrhages may be seen in any of ANCA associated vasculitides.

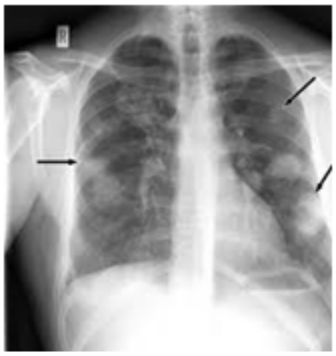

Figure 13 : CXR of patient with WG showing multiple focal discrete opacities and nodules rounded or oval 2-4 cm with no zonal predilection resolved completely after IS

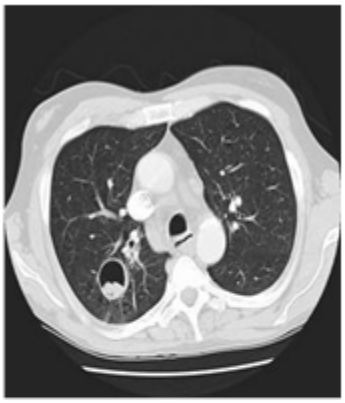

Figure 14: HRCT scan of patient with wegener's granulomatosis showing bilateral varing size lung nodules with cavitation

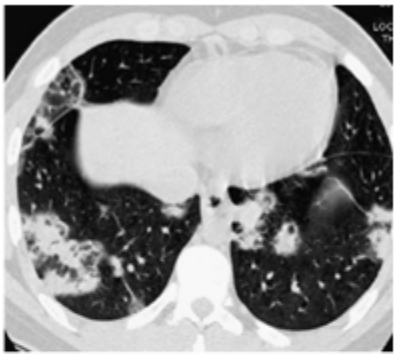

Figure 15 : Wegener's granulomatosis, atoll sign. This axial CT scan shows bilateral subpleural opacities with central ground-glass attenuation and peripheral consolidation, consistent with the atoll or reverse ground-glass halo sign.

8.Tissue biopsy With regard to small-vessel vasculitis, it is essential to test for ANCA and immune complexes. However, these are definitive factors for diagnosis; rather, tissue biopsy is the most important diagnostic method for vasculitic syndrome. If it is necessary to differentiate ANCA-associated vasculitis (AAV) from immune complex-mediated vasculitis, it is preferable to prepare the materials for IIF staining in advance before conducting the tissue biopsy. Because the primary lesions of TAK are in the aorta and those of Kawasaki disease (KD) are in the coronary arteries, it is not possible to perform a biopsy for diagnosis of these diseases. Hence, in such cases, diagnostic imaging study plays a central role in diagnosis.

For other primary vasculitis syndromes, biopsy of the affected vessels is the most useful method for diagnosis. Some considerations with regard to tissue biopsy for systemic vasculitis are as follows:

1. Giant cell arteritis (GCA): A biopsy of the temporal artery is essential for diagnosis. As noncontiguous segmental lesions develop in GCA, it is crucial to prepare serial sections of biopsy specimens.

2. PAN: Although the typical histological finding of PAN is necrotizing angiitis, which is characterized by fibrinoid necrosis in the tunica media, old and new lesions are often observed within the same tissues. By definition, PAN does not include inflammation of the arterioles, venules, and capillaries, meaning that PAN is not associated with glomerulonephritis.

3. MPA: The typical histological finding of MPA is necrotizing angiitis in arterioles and capillaries in the kidneys, indicating necrotizing crescentic glomerulonephritis.

4. GPA: A finding of necrotizing granulomatous lesions with giant cells in lesion sites of the upper

Volume 3, Issue 6; November-December 2020; Page No 830-845

respiratory tract (eg, nose, paranasal sinuses, and soft palate) is useful for early diagnosis. Various patterns of glomerulonephritis can also be found in kidney biopsy specimens.

5. EGPA: Biopsy specimens from peripheral nerves, muscles, and lungs with infiltration show vasculitides and granulomas with prominent invasion with eosinophils.

6. Anti-GBM Disease: Diffuse crescentic glomerulonephritis is a distinctive feature of this disease. IIF staining can show deposition of IgG and C3 along the glomerular capillary walls.

7. IgA vasculitis (IgAV): Necrotizing angiitis can be observed with blood vessels in the area from the papillary layer to the reticular layer of the skin. Using immunofluorescent staining, in accordance with the areas where necrotizing angiitis has occurred, deposition of IgA in areas from the vascular endothelial cells to the vascular lumen can be observed.

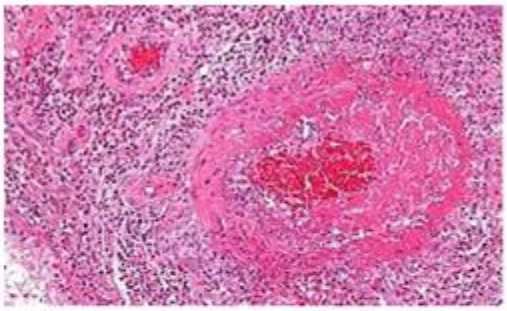

Figure 16 :microscopy of sural nerve biopsy in a patient with CSS showing epineural extravascular eosinophils and vasculitis associated with axonal degeneration.

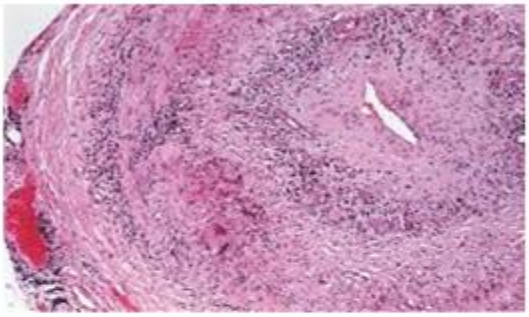

Figure 17 : Temporal artery biopsy in patient of GCA showing transmural mononuclear cell infiltration with occlusion of vessel lumen.

Treatment:

Large vessel Vasculitis:

Corticosteroids (CS) : Prednisolone 1 mg /kg/ day for 6 weeks followed by 10 -20 % tapering every 2 weeks and maintainence dose (0.15 mg/kg/day) for 2-4 years may be required. ESR and CRP are not reliable to monitor disease activity while IL6 may be better marker for the disease activity. In GCA, if there is impending visual loss, IV methyl prednisolone 500 – 1000 mg/day for 3 – 5 days should be given.

Immunosuppresive drugs: Methotrexate (MTX) (15 -25 mg/week) , Azathioprine (AZA) (2mg/kd/day), Mycophenolate mofeltil (1.5-2 g/ day) may be added to low dose of CS (0.25mg/kg/day) as steroid sparing agents . Tocilizumab an interleukin 6 receptor alpha antibody has shown sustained glucocorticoid free remission in patients with giant cell arteritis[Giant-Cell Arteritis Actemra (GiACTA) trial , 2017]

Medium vessel vasculitis:

PAN: CS and Cyclophosphamide (CPM) either orally or intravenously are given. Since PAN is a monophasic illness , survival of patient is increased to 80 % with corticosteroids and Cyclophosphamide. PAN who are positive for hepatitis B virus should be treated with interferon and Lamivudine and may be combined with plasmaphersis (to remove immune complexes) in refractory cases.

Kawasaki Disease: CS are contraindicated as coronary arteries may be weakned and thrombosed by the treatment with these agents . IV immunoglobulin 2g/kg as single dose may be given (70 g maximum).Low dose aspirin may be used if there is thrombocytosis as prophylactic agent.

Small vessel vasculitis (WG,CSS,MPA) :

Volume 3, Issue 6; November-December 2020; Page No 830-845

Induction phase: CS (1mg/kg/d) and CPM (oral 2 mg/kg/d or IV 750-1000 mg/ m2 every 4 wks) are preferred initially in patients with active severe life threatening WG for 6 months.Remission

rates were similar for both daily and intermittent regimes. IV CPM pulses are associated with less adverse effects while oral CPM is associated with higher dosage and significant increase in infection risk.

Maintenance phase: MTX (25mg/ wk) or AZA (2 mg/kg/d) may replace CPM and is continued for 24 months and in patients who remain ANCA positive, immunosuppression should be continued upto 5 years though in one third patients ANCA levels may not correlate with activity of WG. Patients intolerant of CPM may be given mycophenolate mofetil or leflunomide (upto 40mg/d), the latter has been used to maintain remission in an open label trial by Metzler C et al. 2004.In severe life threatening renal failure and pulmonary haemorrhage, plasma exchanges may be combined with CS and CPM (Jayne DR, et al, 2007)

Limited WG: Methotrexate (15-25 mg / wk) is preferred over CPM. Trimethoprim and sulfamethoxazole is used in limited WG of the upper airways to maintain remission and nasal mupirocin may eradicate staphylococcus aureus infection which is a trigger for relapse of WG. CSS was associated with good outcome when CS and CPM were combined with synchronized cycles of plasmapheresis andIV immunoglobulin (Danieli M Get al , 2007). For CSS, modulation of eosinophils with interferon–alpha and Interleukin 5 is been tried. Mepolizumab, an anti-IL5 monoclonal antibody, demonstrated significant benefits for patients with refractory cases of CSS.

Other small vessel vasculitis

Henoch Scholein Purpura: NSAIDs for symptomatic treatment (Palpable purpura) or antihistamine for urticaria may suffice. CS and immunosuppressants for persistent renal involvement may be given.

Leucocytoclastic Vasculitis or hypersensitivity vasculitis : Dapsone for mild disease while for severe systemic or recurring disease (e.g. persistent nephrotic syndrome, rapidly progressive GN, severe abdominal pain or bleeding) CS with AZA or CPM may be used to inhibit immune mediated inflammation.

Cryoglobuminemic vasculitis CGV: For hyperviscosity plasmapheresis and for underlying malignancy chemotherapy may be required. Ribavirin (1000 -1200mg/d) and interferon –α (1 µg/kg /week)can be used in hepatitis C associated Cryoglobulinemia and may lead to viral eradication and correction of Cryoglobinemia..For severe disease CS and CPM may be needed.

Bechets disease : Colchicine (1.5 -2 mg / d), thalidomide (100mg /d) for mild orogenital ulcers is useful. For severe disease in any organ system CS, CPM, CsA, Chlorambucil, methotrexate, interferon alfa may be given. Apremilast (phosphodiesterase 4 inhibitor) used for oral ulcers in behcet's disease (NEJM,2015).

Table 6: Current biological agents in treatment of vasculitis :

Agent	Indication
T cell Depletion with	
Anti thymoyte globulin	
Anti CD 52 (CAMPATH , Alemtuzumab)	Consider in refractory AAV
B Cell Depletion with	
Rituximab (RAVE trial)	Consider in refractory AAV

Volume 3, Issue 6; November-December 2020; Page No 830-845

Tumour necrosis factor alpha blockade	
Etanercept , infliximab and adalimumab	For refractory AAV, GCA and TA Found to be associated with leucocytoclastic vasculitis
Deoxyspergualin	Promising results in refractory AAV
Interleulin 5 blockade : **Mepolizumab (MATOCSS Trial)**	First FDA approved drug for refractory Chrug straus syndrome
Interleukin 6 blockade : **Toclizumab (GiACTA trial)**	Approved for refractory Giant cell arteritis

AAV- ANCA associated vasculitis, GCA- Giant cell arteritis , TA- Takayasu's arteritis

Monitoring treatment response:

Response to treatment during induction must be monitored to identify whether remission is achieved. Induction monitoring requires complete assessment of organsystem involvement at every visit with tools such as the Birmingham Vasculitis Activity Score (BVAS), Vasculitis Damage Index (VDI), Disease Extent Index (DEI), Five factor Score (FFS) .If new or worsening symptoms develop during induction therapy, then the patient needs assessment for continued disease activity as well as treatment complications such as infections related to immunosuppressive therapy. The FFS provides a prognostic indication and guide to intensity of treatment for patients with polyarteritis nodosa , churg strauss syndrome and microscopic polyangitis. It scores the presence of serum creatinine above 1.58mg/dl, proteinuria above1 g/day , severe gastrointestinal tract invovelment, cardiomyopathy and central nervous system involvement.It is not appropriate for follow up, and is complementary to the BVAS. It is not entirely satisfactory, as the 5-year mortality is 12 % with none of the risk factors. It is up to 46 % with two or more risk factors and 45 - 95 % when three or more of the five factors are present.

Table 7: EULAR Definitions of disease status

Status	Definition
Remission	**Absence of activity that merits maintaining treatment IS**
Response	**50 % of reduction in an activity score and absence of new manifestation** **Recurrence or debut of an manifestation**

Volume 3, Issue 6; November-December 2020; Page No 830-845

Relapse	**attributable to active disease**
▪ **Major**	**With vital or organ compromise**
▪ **Minor**	**Without vital or organ compromise**
Resistance	**Stable or increasing activity in spite of 4 weeks of standard treatment**
▪ **Lack of response**	**< 50 % of reduction of an activity score after 6 weeks of therapy**
▪ **Persistent disease**	**Presence of ≥one major item or 3 minor ones (BVAS or BVAS/ WG) after 12 weeks of treatment**
Low activity	**Persistance of minor symptoms that improve with discrete increases in GC**

BVAS , Birmingham Vasculitis Activity Score : VBAS/WG . Birmingham Vasculitis Activity Score for Wegener Granulomatosis ; GC, glucocorticoids

Birmingham Vasculitis Activity Score (version 3)

Patient ID: **Date of birth:** **Total score:**

Assessor: **Date of assessment**

Tick an item **only** if attributable to active vasculitis. If there are no abnormalities in a section, please tick 'None' for that organ-system.

If **all** abnormalities are due to persistent disease (active vasculitis which is not new/worse in the prior 4 weeks), tick the **PERSISTENT** box at the bottom right corner

Is this the patient's first assessment? **Yes** ○ **No** ○

	None	Active disease
1. General	○	
Myalgia		○
Arthralgia / arthritis		○
Fever ≥38° C		○
Weight loss ≥2 kg		○
2. Cutaneous	○	
Infarct		○
Purpura		○
Ulcer		○
Gangrene		○
Other skin vasculitis		○
3. Mucous membranes / eyes	○	
Mouth ulcers		○
Genital ulcers		○
Adnexal inflammation		○
Significant proptosis		○
Scleritis / Episcleritis		○
Conjunctivitis / Blepharitis / Keratitis		○
Blurred vision		○
Sudden visual loss		○
Uveitis		○
Retinal changes (vasculitis / thrombosis / exudate / haemorrhage)		○
4. ENT	○	
Bloody nasal discharge / crusts / ulcers / granulomata		○
Paranasal sinus involvement		○
Subglottic stenosis		○
Conductive hearing loss		○
Sensorineural hearing loss		○
5. Chest	○	
Wheeze		○
Nodules or cavities		○
Pleural effusion / pleurisy		○
Infiltrate		○
Endobronchial involvement		○
Massive haemoptysis / alveolar haemorrhage		○
Respiratory failure		○

	None	Active disease
6. Cardiovascular	○	
Loss of pulses		○
Valvular heart disease		○
Pericarditis		○
Ischaemic cardiac pain		○
Cardiomyopathy		○
Congestive cardiac failure		○
7. Abdominal	○	
Peritonitis		○
Bloody diarrhoea		○
Ischaemic abdominal pain		○
8. Renal	○	
Hypertension		○
Proteinuria >1+		○
Haematuria ≥10 RBCs/hpf		○
Serum creatinine 125-249 µmol/L*		○
Serum creatinine 250-499 µmol/L*		○
Serum creatinine ≥500 µmol/L*		○
Rise in serum creatinine >30% or fall in creatinine clearance >25%		○
***Can only be scored on the first assessment**		
9. Nervous system	○	
Headache		○
Meningitis		○
Organic confusion		○
Seizures (not hypertensive)		○
Cerebrovascular accident		○
Spinal cord lesion		○
Cranial nerve palsy		○
Sensory peripheral neuropathy		○
Mononeuritis multiplex		○
10. Other	○	
a.		○
b.		○
c.		○
d.		○
PERSISTENT DISEASE ONLY: (Tick here if **all** the abnormalities are due to persistent disease)		☐

References:
Version 1: Luqmani, RA, et al. (1994). "Birmingham Vasculitis Activity Score (BVAS) in systemic necrotizing vasculitis." QJM **87**(11):671-8.
Version 2: Luqmani, RA, et al. (1997). "Disease assessment and management of the vasculitides." Baillieres Clin Rheumatol **11**(2): 423-46.
Version 3: Mukhtyar C, et al (2008). "Modification and validation of the Birmingham Vasculitis Activity Score (version 3). Ann Rheum Dis. 2008 Dec 3. [Epub ahead of print]

IS, Immuno suppressants

Volume 3, Issue 6; November-December 2020; Page No 830-845

Conclusion:

Vasculitis has a myriad spectrum of clinical presentation which serves as a diagnostic challenge for physicians and justifies an integrated approach to management. Conceptualizing vasculitic disease based on vessel size, site and organ involvement can be useful, but it is not an absolute definition. It still remains very crucial for the physician to diagnose the disease early so that therapeutic measures can be taken in order to prevent the complications, sequelae and mortality associated with it.

References:

1. Richard A. Watts et al, Epidemiology of vasculitis – Lessons learnt from the differences in different geographical areas. indian journal of rheumatology 10 (2015) s6–s10
2. Joshi VR, Mittal G. Vasculitis-Indian Perspective. J Assoc Physicians India 2006; 54 (Suppl):12-14.
3. Jennette JC, Falk RJ, Bacon PA, et al. 2012 revised International Chapel Hill Consensus Conference Nomenclature of Vasculitides. Arthritis Rheum 2013; 65:1.
4. Palk RJ, Hoffman GS. Controversies in small vessel vasulitis – Comparing the rheumatology and nephrology views , Curr opin Rheumat 2007;19:1-9
5. Choi HK , Merkel PA ,Walker Am , Niles JL. Drug induced ANCA positive vasculitis . Arthritis Rheum 2000;43 : 405 – 13
6. Malaviya A.N . Vasculitis – An update .J Indian Rheumat Assoc 2001; 9 :3
7. Renu Saigal , Amit kansal. Approach to vasculitis Medicine Update-2010 (publication of annual conference of journals of association of physicians), Edition: Medicine update 2010, Chapter: Approach to systemic vasculitis, pp.816-821
8. Cornelia M .Weyand , James W. Fulbright , Gene G.Hunder et al . Treatment of Giant cell arteritis : Interleukin – 6 as a biological marker of disease activity .Arth and Rheumat May 2000;43(5):1041-48
9. Hatemi G et al. Apremilast for Behcet's Syndrome – A Phase 2 , Placebo controlled study. N Engl J Med 2015; 372:1510-1518,
10. Okazaki T, Shinagawa S, Mikage H.Vasculitis syndrome—diagnosis and therapy. *J Gen Fam Med*.2017;18:72–78. https://doi.org/10.1002/jgf2.4
11. D Groot K et al .Randomised Controlled trial of daily oral versus pulse CPM for induction and CPM for induction of remission in ANCA associated systemic vasculitis. Kidney Blood pressRes28:195
12. Metler C et al , . Maintainence of remission with leflunomide in WG.Rheumatology (oxf) 2004 ;43:315-320
13. Danieli MG , Cappelli M , MAcangi G , et al. Long term effectiveness of Intravenous immunoglobulin in CSS. Ann Rheum Dis 2004;63 : 1649-54
14. Walsh M jayne D.Rituximab in the treatment of antineutrophil cytoplasm antibody associated vasculitis nad systemic lupus erythematosis: Past , present and future . Kidney int 2007 ;72:676
15. Palit A, Inamadar AC. Vasculitis: Approach to diagnosis and therapy. Indian J Dermatol Venereol Leprol 2006;72:334-45.
16. Luqmani RA, Bacon PA, Moots RJ, Janssen BA, Pall A, Emery P, Savage C, Adu D.
17. Birmingham Vasculitis Activity Score (BVAS) in systemic necrotizing vasculits. QJM. 1994 Nov;87(11):671-8

Volume 3, Issue 6; November-December 2020; Page No 830-845