(International Print/Online Journal)

SJIF IMPACT FACTOR: 5.565
PUBMED-National Library of Medicine ID-101739732

ISSN (Print): 2209-2870
ISSN (Online): 2209-2862

International Journal of Medical Science and Current Research (IJMSCR)
Available online at: www.ijmscr.com
Volume3, Issue 6, Page No: 335-338
November-December 2020

Pulmonary Alveolar Microlithiasis – Rare Disease: A Case Report

Balbir Malhotra[1], Dilbag singh[2], Amritpal kaur[2]
[1.] Professor, [2.] Junior resident
Department of pulmonary Medicine, Government Medical College, Amritsar Punjab, India

***Corresponding Author:**
Dilbag singh
Junior resident, Department of pulmonary Medicine, Government Medical College, Amritsar Punjab, India

Type of Publication: Case Report
Conflicts of Interest: Nil

ABSTRACT

Pulmonary alveolar microlithiasis (PAM) is a rare, chronic lung disease with bilateral intra-alveolar calcium and phosphate deposition throughout the lung parenchyma with predominance to lower and midzone. Although, etiology and pathogenesis of PAM is not fully understood, the mutation in SLC34A2 gene that encodes a sodium-phosphate co-transporter in alveolar type II cells resulting in the accumulation and forming of microliths rich in calcium phosphate (due to impaired clearance) are considered to be the cause of the disease. Chest radiograph and high-resolution CT of thorax are nearly pathognomonic for diagnosing PAM. HRCT demonstrates diffuse micronodules showing slight perilobular predominance resulting in calcification of interlobular septa. We present a case of 30 year female diagnosed with this rare disease.

Keywords: Pulmonary alveolar microlithiasis (PAM) ,Chest xray , HRCT Chest , TBLB

INTRODUCTION

Pulmonary alveolar microlithiasis (PAM) is a rare disease, characterized by presence of diffuse innumerable minute calculi called microliths in the alveoli of the lungs. PAM was first reported by Norwegian Harbitz in 1918;[1] accordingly, it is also known as Harbitz′ syndrome. It was named as Pulmonary Alveolar Microlithiasis by Ludwig Puhr of Hungary in 1933. Less than 800 cases have been reported worldwide in medical literature till date from all the continents of the globe without any particular geographic or racial distribution. Asia and Europe shared nearly one-third cases each. Most of the cases have been reported from Turkey, Japan and Italy. PAM occurs in both sexes with a slight predominance among males worldwide except in Italy where female predominance has been reported. Although, PAM is seen in all age groups, it is most frequently diagnosed from birth to 40 years of age. The age at diagnosis spans a wide range, with predominance of younger age of nearly half of Japanese patients diagnosed in the paediatric age group, whereas one-fifth patients are found at over 40 years of age.[2] Two reviews on the subject have been reported with mean age of 27–30 years at the time of diagnosis.[3,4] Of the 576 patients analyzed together, 35.8% were below 20 years of age and 88.2% were under 50 years.[4] There was no sex difference as far as the rate of occurrence, age at diagnosis and the progression of the disease was concerned.[3–5] The youngest reported cases were premature twins and two newborn, while the most elderly was of 80 years of age.[5] It was first reported from India by Viswanathan.[6] Not more than 30 cases are reported in literature from different regions of India till date.[7–11]

We present a case of symptomatic PAM in a 30-year-old female, due to rarity of this disease.

CASE REPORT

A 30 year-old women presented with a 1 year history of progressive shortness of breath on exertion and dry

cough. At physical examination, auscultation of the lungs has revealed coarse crackles. Cardiac auscultation was normal, and no cyanosis, clubbing and lymphadenopathy or peripheral edema was observed. There was no history of smoking, occupation or previous known pulmonary disease. On routine blood examination, blood counts and serum chemistries were found to be normal. Pulmonary function tests (PFT) showed a mild restrictive ventilatory defect. The sputum was negative for AFB and CBNNAT was also negative for MTB. Human immunodeficiency virus testing was negative as well.

The chest plain films revealed a diffuse symmetric dense bilateral micronodular pattern (Figure 1). Based on this finding, HRCT scan was obtained, revealing diffuse ground glass attenuation and septal thickening, more pronounced in lower pulmonary regions, with calcifications along the interlobar septa and subpleural regions.(Figure 2). The patient underwent a fiberoptic bronchoscopy with bronchoalveolar lavage and transbronchial lung biopsy. The lavage fluid was negative for tuberculosis or fungi. Microliths were not found. Histology revealed round, concentrically laminated microliths in the alveoli associated with slightly thickened interstitial septa, consistent with the diagnosis of PAM.

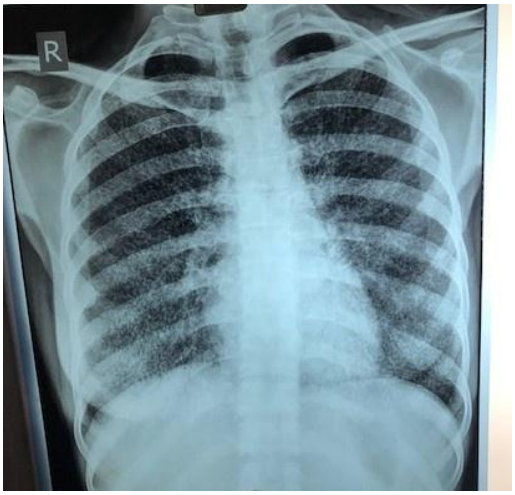

Figure 1-Chest radiographs shows a diffuse symmetric lung lesion with confluence of dense micronodular infiltrate.

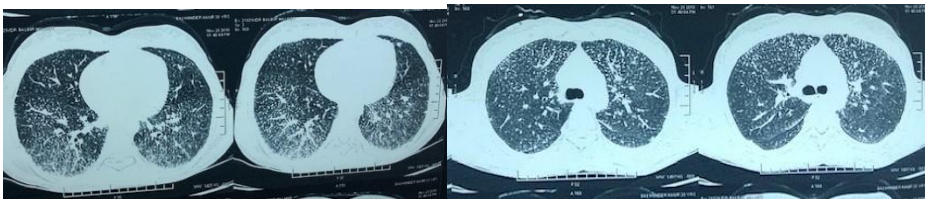

Figure 2(a-b) High-resolution CT scan reveals diffuse ground glass attenuation and septal thickening, more pronounced in lower pulmonary

DISCUSSION

PAM is a rare disease that presents chronic evolution, poorly defined etiology and pathogenesis, and is basically characterized by numerous small calculi (denominated calciferites, calcospherites or microlites) within air spaces [11–17]. Patients may remain asymptomatic for many years and do usually become symptomatic between the third and fourth decades [13, 16]. At clinical presentation patients usually demonstrate a lung disorder with restrictive pattern , as seen in our case. Adult patients commonly show progressive deterioration of the pulmonary function and death usually occurs in mid-life because of respiratory failure associated with cor pulmonale . Mean age at the time of diagnosis in the literature is 35 years and apparently there is no important predominance of gender [12, 14], The disease presents a high incidence of familial occurrence (approximately one-third of the cases) suggesting an autosomal recessive inheritance pattern . Recently, a few reports have described the role of mutation in the type IIb sodium-phosphate cotransporter gene (SCL34A2 gene), which is involved in phosphate homeostasis in several organs, including the lung [18,19]. SCLC34A2 expression is observed in type II alveolar cells. These cells use phospholipids to produce surfactant and are also responsible for recycling and degrading the outdated surfactant. It is believed that the dysfunction in SCLC34A2 may reduce the clearance of the phosphate released in this process, leading to the formation of microliths. For this reason, it is now

Volume 3, Issue 6; November-December 2020; Page No 335-338
© 2020 IJMSCR. All Rights Reserved

accepted that this mutation is responsible for the pathologic changes seen in the pulmonary parenchyma in PAM . Besides that, some authors demonstrated the usage of measuring the serum concentration of surfactant protein-A (SP-A) and surfactant protein-D (SP-D) in patients with PAM. Alveolar type II cells and Clara cells produce these two proteins in the lungs. The diffuse parenchyma fibrosis, consequent to PAM, causes an increase in permeability, leading to an increase in the levels of these two proteins in the blood. Therefore, SP-A and SP-D measurement may be an alternative to monitor the progression and activity of the disease. [17]. These exams were not performed in our patient. Nevertheless, no effective treatment for end stage PAM currently exists, with the exception of lung transplantation. Until then, seven successful cases have been reported, with no recurrence of the disease. Transplantation should be considered in cases where either severe respiratory failure or right heart failure are present. Patients who undergone lung transplantation have showed an increase in right ventricular ejection fraction and regression of right ventricular hypertrophy [14].

In the radiological diagnosis of PAM, chest radiographs usually reveal diffuse, bilateral areas of micronodular calcifications (‘‘sand storm’’) that predominate in the middle and lower lung areas [12–17]. The heart borders and the diaphragm are usually obliterated.The chest radiographs of our patient showed a diffuse symmetric lung lesion with dense micronodular aspect, corroborating the pattern described in the literature.

The HRCT findings in patients with alveolar microlithiasis vary considerably [12–17]. This pattern occurs probably due to small calculi in the air space. Subpleural linear calcification, confluent and diffuse calcified nodules and dense consolidations are also a common finding. Calcifications along the bronchovascular bundles and at the central region of the bronchovascular tree can also be seen [12–17]. Recently, it was described the unique characteristics of the mosaic pattern seen in alveolar microlithiasis, in which the interlobular septa are of calcium density due to the deposition of calcipheriths within the peripheral lobular parenchyma, adjacent to the septa. Some authors consider this pattern very specific and even pathognomonic of PAM on the HRCT scan, since this aspect has not been described in any other disease . Clinicians should have in mind that some findings seen in PAM, such as nodular calcifications, can be found in other diseases like tuberculosis, metastatic osteosarcoma, amyloidosis and silicoproteinosis. Besides that, dense consolidations can also be found in metastatic pulmonary calcification, talcosis and amiodarone lung toxicity. In this way, associated CT findings and clinical features should always be correlated, since these diseases have different kinds of presentation and evolution [18].

CONCLUSION

In conclusion, PAM is a rare disease that can affect young patients, with chronic and deteriorating evolution. Clinicians should be aware of it existence and the radiological features associated. The micronodular pattern seen in chest radiography can sometimes be misdiagnosed as miliary tuberculosis or other diseases that present with this pattern. In this way, HRCT should always be performed since it can reveal characteristic patterns of alveolar microlithiasis, reserving lung biopsy for atypical and inconclusive case

REFERENCES

1. Harbitz E. Extensive calcification of the lungs as a distinct diseases. Arch Intern Med. 1918;21:139–46. [Google Scholar]
2. Tachibana T, Hagiwara K, Johkoh T. Pulmonary alveolar microlithiasis: Review and management. Curr Opin Pulm Med. 2009;15:486–90. [PubMed] [Google Scholar]
3. Ucan ES, Keyf AI, Aydilek R, Yalcin Z, Sebit S, Kudu M, et al. Pulmonary alveolar microlithiasis: Review of Turkish reports. Thorax. 1993;48:171–3. [PMC free article] [PubMed] [Google Scholar]
4. Mariotta S, Ricci A, Papale M, De Clementi F, Sposato B, Guidi L, et al. Pulmonary alveolar microlithiasis: Report on 576 cases published in the literature. Sarcoidosis Vasc Diffuse Lung Dis. 2004;21:173–81. [PubMed] [Google Scholar]
5. Castellana G, Lamorgese V. Pulmonary alveolar microlithiasis. World cases and review of the literature. Respiration. 2003;70:549–55. [PubMed] [Google Scholar]

Volume 3, Issue 6; November-December 2020; Page No 335-338
© 2020 IJMSCR. All Rights Reserved

6. Viswanathan R. Pulmonary alveolar microlithiasis. Thorax. 1962;17:251–6. [PMC free article] [PubMed] [Google Scholar]
7. Gayathri Devi HJ, Mohan Rao KN, Prathima KM, Das JK. Pulmonary alveolar microlithiasis. Lung India. 2011;28:139–41. [PMC free article] [PubMed] [Google Scholar]
8. Chandra S, Mohan A, Guleria R, Das P, Sarkar C. Bilateral stony lung: Pulmonary alveolar microlithiasis. BMJ Case Rep 2009. 2009;1012 (Abstract) [PMC free article] [PubMed] [Google Scholar]
9. Hira HS, Singh T, Chowdhary V. Pulmonary alveolar microlithiasis: Role of transbronchial lung biopsy. J Assoc Physicians India. 2000;48:832–3. [PubMed] [Google Scholar]
10. Malhotra B, Sabharwal R, Singh M, Singh A. Pulmonary alveolar microlithiasis with calcified pleural plaques. Lung India. 2010;27:250–2. [PMC free article] [PubMed] [Google Scholar]
11. Singh NK, Gupta A. Pulmonary alveolar microlithiasis. J Assoc Physicians India. 1995;43:647–8. [PubMed] [Google Scholar]
12. G. Barbolini, G. Rossi, and A. Bisetti, “Pulmonary alveolar microlithiasis,” New England Journal of Medicine, vol. 347, no. 1, pp. 69–70, 2002. View at: Publisher Site | Google Scholar
13. E. Marchiori, C. M. Gonçalves, D. L. Escuissato, K.-I.-S. S. Teixeira, R. Rodrigues, M. M. Barreto, and M. Esteves, “Pulmonary alveolar microlithiasis: high-resolution computed tomography findings in 10 patients,” Jornal Brasileiro de Pneumologia, vol. 33, no. 5, pp. 552–557, 2007. View at: Publisher Site | Google Scholar
14. H. Hoshino, H. Koba, and H. Koba, “Pulmonary alveolar microlithiasis: high-resolution CT and MR findings,” Journal of Computer Assisted Tomography, vol. 22, no. 2, pp. 245–248, 1998. View at: Publisher Site | Google Scholar
15. P. Cluzel, P. Grenier, P. Bernadac, F. Laurent, and J. D. Picard, “Pulmonary alveolar microlithiasis: CT findings,” Journal of Computer Assisted Tomography, vol. 15, no. 6, pp. 938–942, 1991. View at: Google Scholar
16. M. A. Korn, H. Schurawitzki, W. Klepetko, and O. C. Burghuber, “Pulmonary alveolar microlithiasis: findings on high-resolution CT,” American Journal of Roentgenology, vol. 158, no. 5, pp. 981–982, 1992. View at: Google Scholar
17. T. H. Helbich, C. Wojnarovsky, P. Wunderbaldinger, G. Heinz-Peer, I. Eichler, and C. J. Herold, “Pulmonary alveolar microlithiasis in children: radiographic and high-resolution CT findings,” American Journal of Roentgenology, vol. 168, no. 1, pp. 63–65, 1997. View at: Google Scholar
18. E. L. Gasparetto, P. Tazoniero, D. L. Escuissato, E. Marchiori, R. L. Frare Silva, and D. Sakamoto, “Pulmonary alveolar microlithiasis presenting with crazy-paving pattern on high resolution CT,” British Journal of Radiology, vol. 77, no. 923, pp. 974–976, 2004. View at: Publisher Site | Google Scholar
19. G. Castellana, M. Gentile, R. Castellana, P. Fiorente, and V. Lamorgese, “Pulmonary alveolar microlithiasis: clinical features, evolution of the phenotype, and review of the literature,” American Journal of Medical Genetics, vol. 111, no. 2, pp. 220–224, 2002. View at: Publisher Site | Google Scholar

Volume 3, Issue 6; November-December 2020; Page No 335-338
© 2020 IJMSCR. All Rights Reserved