(International Print/Online Journal)

SJIF IMPACT FACTOR: 5.565
PUBMED-National Library of Medicine ID-101739732

ISSN (Print): 2209-2870
ISSN (Online): 2209-2862

International Journal of Medical Science and Current Research (IJMSCR)
Available online at: www.ijmscr.com
Volume3, Issue 4, Page No: 742-749
July-August 2020

Effect of Nicotine Smoke on Testes of Male Albino Rats: A Light Microscopic Study

PrenikaShangloo, Sunanda Raina, NusratJabeen
Post- graduate Department of Anatomy, Govt. Medical College Jammu

***Corresponding Author:**
PrenikaShangloo
Post- graduate Department of Anatomy, Govt. Medical College Jammu

Type of Publication: Original Research Paper
Conflicts of Interest: Nil

ABSTRACT

The harmful effects of nicotine have been reported on lungs and cardiovascular system in number of studies, but the most unexplored profile of the effect of nicotine has been the reproductive organs. In the current study we planned to evaluate the effects of nicotine smoke on one of the important reproductive organs i.e. the testes. The study was conducted on 12 inbred adult Wistar albino rats; 6 animals acting as control and remaining 6 acting as test group. The animals of control group were given only sterile water whereas animals of test group were exposed to smoke produced from the nicotine wrapped in a cotton wool in the dose of 6mg/day three times a day for each session of 5 minutes each for 5 days. Each rat was exposed to the smoke produced due to nicotine separately in a closed inhalational chamber and not in groups. The rats were sacrificed after the period of experimentation and testis were dissected out and subjected further to tissue processing for histological examination. The histological examination of tissue sections of test group revealed marked distortion and degeneration of seminiferous tubules and germ cell lineage along with distorted and widened interstitial spaces with loss of Leydig cells. On the other hand the tissue sections of control group showed normal histological architecture of testes with normal interstitial spaces and Leydig cells.

Keywords:Nicotine, nicotine smoke, testes

INTRODUCTION

Nicotine, a natural alkaloid found in the plant *Nicotianatabacum*, is considered as an important component of cigarettes. Nicotine chewing gums and dermal patches are the other ways in which nicotine is consumed through non-prescription nicotine replacement therapy. However, in man it is consumed primarily through cigarettes, pipes or cigars. Nicotine can also be found in electronic cigarettes (e-cig), which is a contemporary and wide spread way of smoking (1). Nicotine can be consumed in different forms ranging from smokeless tobacco product such as snuff and chewing tobacco but more often consumed as smoked tobacco. It constitutes 90-95% of the total alkaloids, which is absorbed quickly through the respiratory tract, oral mucosa and skin (2).

Burning tobacco leads to the formation of mixture of two forms of smoke called as secondhand smoke or environmental tobacco smoke. Secondhand smoke is further composed of mainstream smoke and sidestream smoke.

Mainstream smoke is exhaled by a smoker.

Sidestream smoke is the smoke from the lighted end of a cigarette, pipe, cigar or burning tobacco in a hookah. This type of smoke has higher concentration of cancer causing agents (carcinogens) and is more toxic than mainstream smoke. It also has smaller particles than mainstream smoke. These smaller

particles make their way into lungs and the body's cells more easily. When nonsmokers are exposed to secondhand smoke it's called involuntary smoking or passive smoking. Non- smokers who breathe in second hand smoke take in nicotine and toxic chemicals the same way smokers do (3).

Tobacco use is a major preventable cause of premature death and disease worldwide. Fact sheet of Global Adult Tobacco Survey, India (2009-2010) highlighted that current tobacco use in any form in India is 34.6% of adults; out of which tobacco smokers are 14% adults, 25.9% are smokeless tobacco users and 5.3% of the adults use both smoking and smokeless tobacco. Regarding the second- hand smoke exposure, Global Adult Tobacco Survey, India (2009-2010) estimated that about 52.3% adults were exposed to second- hand smoke at home whereas 29% of adults were exposed to the same at the public places mainly in public transports and restaurants and at workplace about 29.9% of adults were exposed to the second- hand smoke (4).

Nicotine poses several health hazards. The effects of nicotine, apart from amount taken; also depends on many factors including size, weight and health of a person, along with the fact that whether the person is used to taking it or not (5). In addition to being highly addictive nicotine has diverse and adverse effect on most but not all the body organs. Nicotine produces both immediate as well as remote effects (6).

Among the organs which nicotine effects, reproductive organ system is the least explored and evaluated system. In males, the effects of nicotine on reproductive system are erectile dysfunction, degeneration of seminiferous tubules, disruption of spermatogenesis, and affects germ cell structure and function at the cellular level (7, 8). Further, there is huge clinical relevance in evaluating the effect of nicotine on these organs. Hence, the current study was planned to evaluate the effect of nicotine on the testes of adult Albino rats.

MATERIALS AND METHODS:

Healthy Wistar Albino rats, twelve in number of male sex only weighing between 125- 160 gm were taken for the study. The rats were procured from the Central Animal House of Government Medical College, Jammu. The animals were left for acclimatization to the laboratory conditions for a week and were provided standard rodent chow/feed and water *ad-libitum* during the period of experimentation. Later, the rats were randomly divided into two groups i.e., test group (T) and control group (C) according to block permuted randomization plan and an identification number was given to rats of each group.

The animals were housed in polypropylene cages (4 animals per cage) with dust free rice husk as a bedding material under laboratory conditions with control environment of temperature 18 to 29ºC, humidity (30% to 70%) and 12h light/dark cycle (16.00-18.00) as per Committee for the Purpose of Control and Supervision of Experiments on Animals (CPCSEA), India, guidelines which are in accordance with the internationally accepted principles for laboratory animal use 9and care. The animals were fasted overnight and were weighed before the initiation of the experiment; using electronic weighing scale.

Group C rats received only distilled water and served as healthy control. The animals of control group were not subjected to any kind of smoke.

Group T rats served as the experimental group and were exposed to smoke produced from the nicotine wrapped in a cotton wool in the dose of 6mg/day three times a day for each session of 5 minutes each for 5 days. Each rat was exposed to the smoke produced due to nicotine separately in a closed inhalational chamber and not in groups.

All animals of test as well as control group were observed daily for physical or behavioral change throughout the experimental period. After the completion of experimental period, the animals were sacrificed 48 hrs after the administration of last dose by giving injection Thiopentone sodium. The experimental protocol was approved by the Institutional Animal Ethic Committee (IAEC).

The sacrificing of animals was followed by dissection. The testes were dissected out from the scrotum of each rat. The naked eye examination was done to see any external changes. The dissected out testis were cut into two halves and were placed in fixative. Later the tissues were embedded in paraffin wax, blocks were made, and sectioned using a rotatory microtome and sections of 5µm thickness

Volume 3, Issue4; July-August 2020; Page No.742-749
© 2020 IJMSCR. All Rights Reserved

were obtained. These sections were stained with Hematoxylin and Eosin and were examined under microscope.

RESULTS:

Behavioral Changes:

Rats in Group C showed no behavioral alterations. Rats were active and alert throughout the study period. They consumed the standard rodent chow/feed and water *ad-libitum* regularly. All the rats completed the experimental period and did not exhibit any case of mortality.

Rats in Group T used to become lethargic after exposure to nicotine smoke, but regained activity after sometime. They consumed the standard rodent chow/feed and water *ad-libitum* regularly. All the rats completed the experimental period and did not exhibit any case of mortality.

Microscopic Changes:

The cut section of testis of group C rats showed seminiferous tubules cut in various planes and each seminiferous tubule was surrounded by an outer layer of connective tissue with fibroblasts known as Tunica Albuginea, and an inner basement membrane. On the basement membrane rest several layers of spermatogenic cells called as germinal epithelium (Fig.1.1).

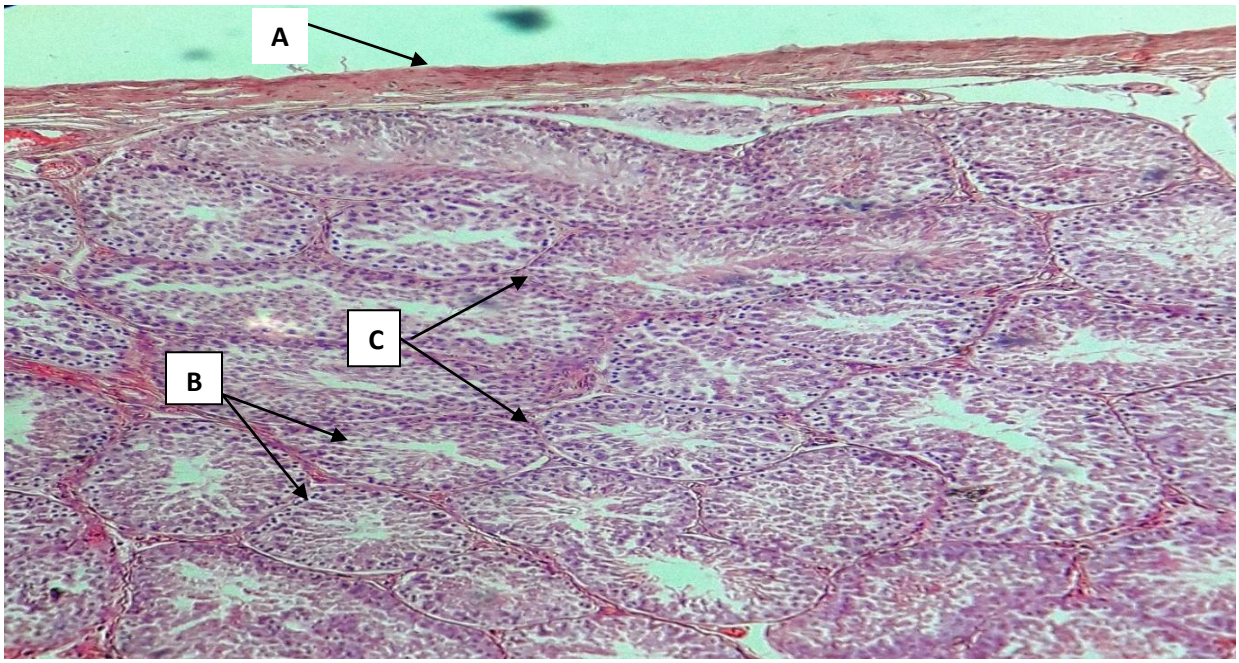

Fig. 1.1: Photomicrograph of testes showing tunica albuginea (A), seminiferous tubules (B) and interstitial tissue (C) (Control group 100X).

Volume 3, Issue4; July-August 2020; Page No.742-749
© 2020 IJMSCR. All Rights Reserved

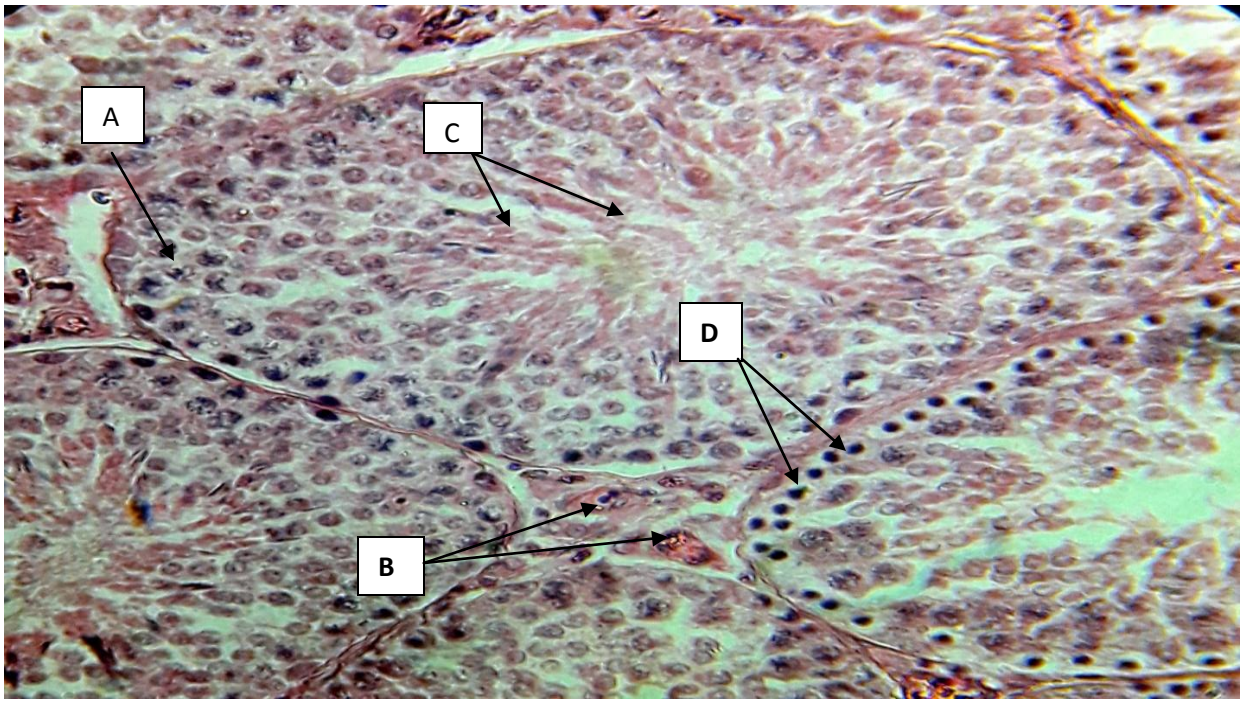

Fig. 1.2: Photomicrograph showing spermatogenic cells in stratified layers (A), Leydig cells (B), spermatids (C) and spermatogonia (D)(Control group 400 X).

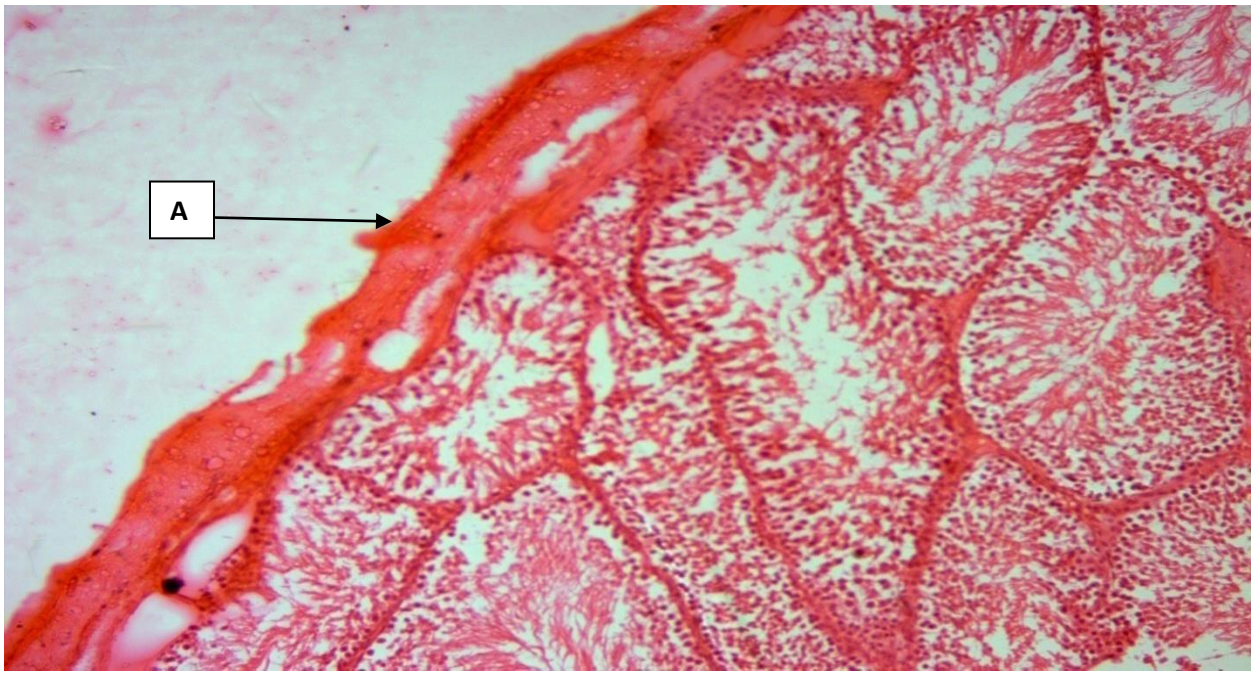

Fig. 1.3: Photomicrograph of testes showing thickened tunica albuginea (A) (Test group 400 X).

Volume 3, Issue4; July-August 2020; Page No.742-749
© 2020 IJMSCR. All Rights Reserved

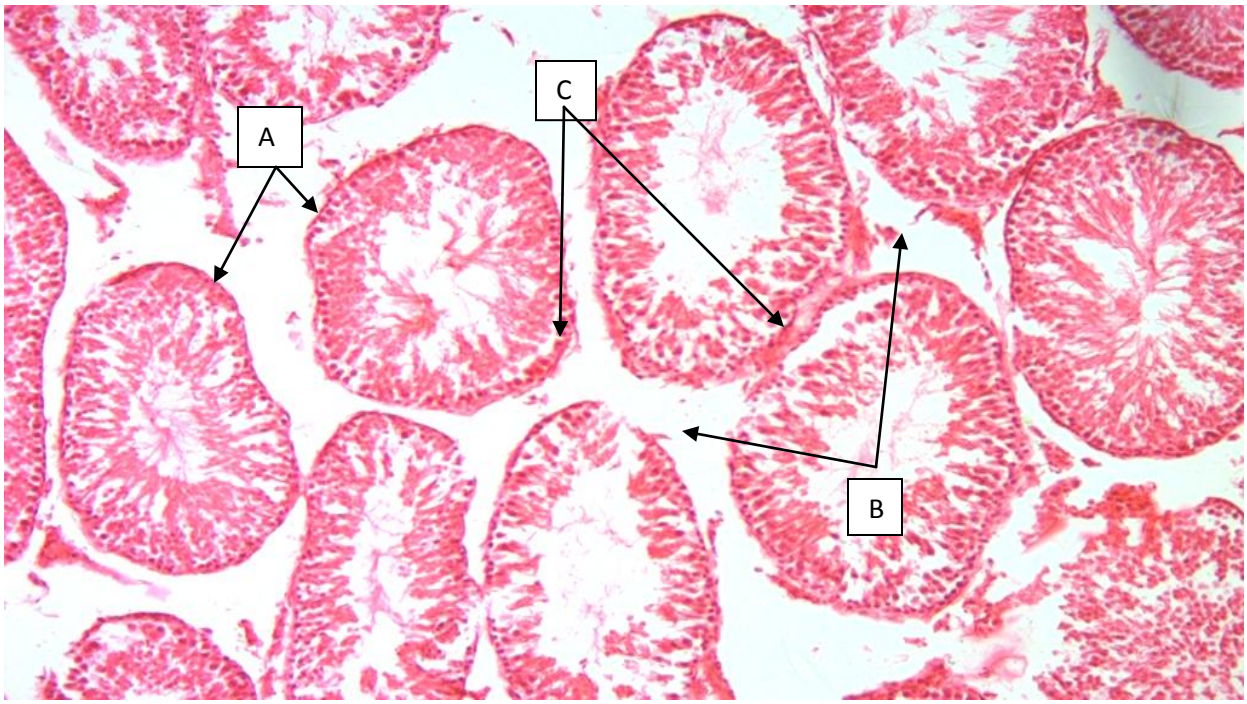

Fig. 1.4: Photomicrograph of testis showing shrunken seminiferous tubules (A), wide and empty interstitial spaces (B) and thickened basement membrane (C) (Test group 100X).

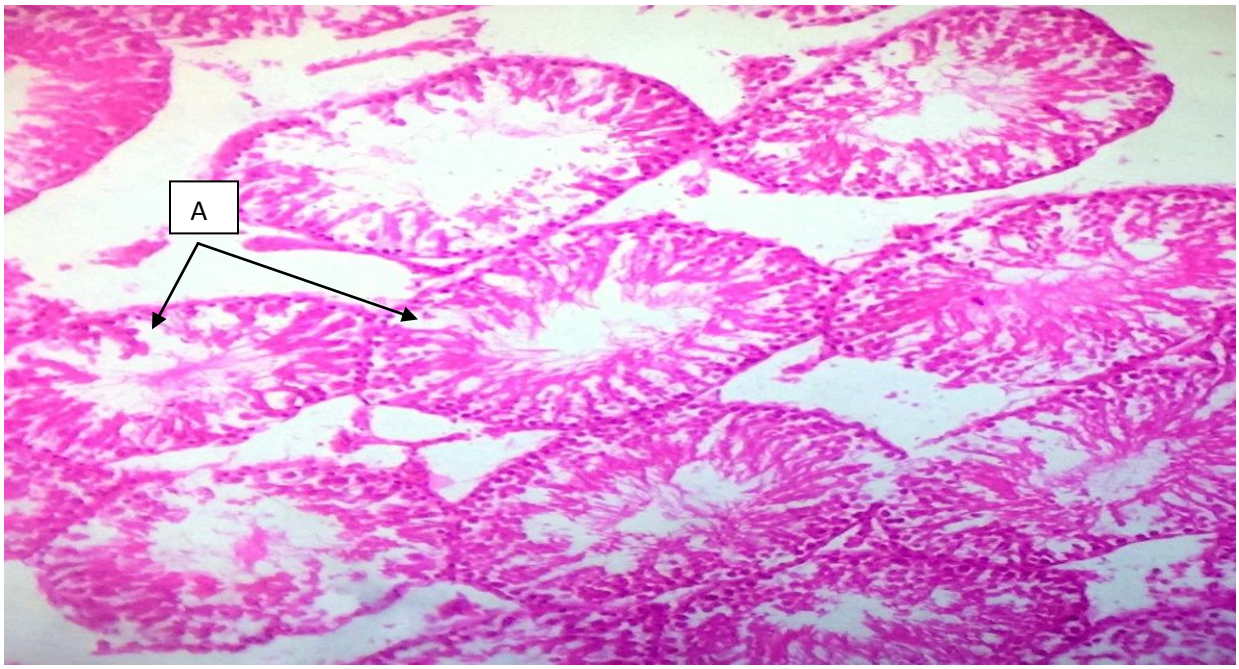

Fig. 1.5: Photomicrograph of testis showing vacuolation in seminiferous tubules (A) (Test group 100 X).

Volume 3, Issue4; July-August 2020; Page No.742-749
© 2020 IJMSCR. All Rights Reserved

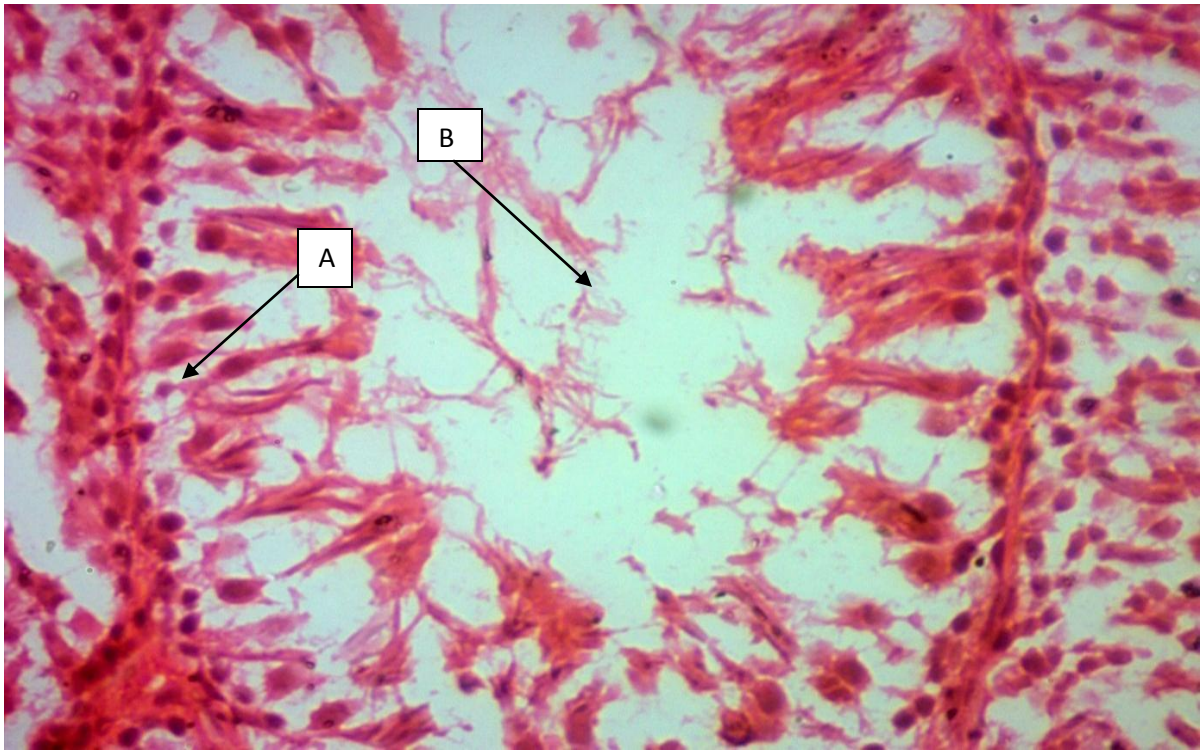

Fig.1.6: Photomicrograph of testis showing seminiferous tubule with decreased number of spermatogonia (A) and empty lumen (B) (Test group 400 X).

These spermatogenic cells were seen in different stages of development. Interstices of the testes consist of loose connective tissue lying in between the adjacent seminiferous tubules. The loose connective tissue was seen to consist of clusters of Leydig cells, blood vessels, nerves and lymphatics. The interstitial cells of Leydig were observed as large or polyhedral shaped large cells with lightly stained foamy cytoplasm and eccentric nucleus (Fig.1.2).

The tunica albuginea and tunica vasculosa of Group T rats were seen to be thickened (Fig. 1.3) with shrunken seminiferous tubules and wide interstitial spaces. Some of the seminiferous tubules appeared small in diameter, distorted and degenerated with thickened basement membrane (Fig 1.4). All the seminiferous tubules were widely separated with distorted interstitial tissue containing dilated blood vessels and few Leydig cells (Fig.1.4). Some of the seminiferous tubule showed vacuolations and some showed accumulation of cellular masses in their lumen (Fig. 1.5). The germinal epithelium showed variable degree of degeneration. The degenerated seminiferous tubules were found to have less number of layers of spermatogonia, few germinal cells and empty lumen indicating incomplete spermatogenesis (Fig.1.6). However, some seminiferous tubules appeared normal with normal stratification of germinal epithelium depicting complete spermatogenesis. Few primary spermatocytes were found to have distorted nucleus and other changes of Pyknosis and Karyolysis. There was desquamation of immature cells into the lumen of seminiferous tubules.

DISCUSSION:

The study focused on depicting the histological changes in the rat testes produced due the effect of nicotine smoke. The nicotine smoke exposure at the given dose for such a short period of 5 days produced thickening of tunica albuginea and tunica vasculosa of Group T rats with shrunken seminiferous tubules and wide interstitial spaces. Some of the seminiferous tubules appeared small in diameter, distorted and degenerated with thickened basement membrane. All the seminiferous tubules were widely separated with distorted interstitial tissue containing dilated blood vessels and few Leydig cells. These observations are well documented in various existing literature on effect of nicotine on testes (9-12,18).Additionally, it was observed that there was reduced spermatid volume, tubular depletion in form of small diameter and germinal epithelium dissociation. This supports the findings of some existing literatures which

Volume 3, Issue4; July-August 2020; Page No.742-749
© 2020 IJMSCR. All Rights Reserved

suggest that nicotine administration is associated with reduced spermatid volume (2, 11, 13, 15).

The stratified epithelium lining seminiferous tubules was found to be formed of two or three rows of spermatogenic cells including Sertoli cells denoting arrest of spermatogenesis. Some seminiferous tubules appeared small in diameter and distorted with incomplete spermatogenesis and empty lumen whereas some of the seminiferous tubules appeared normal with intact germ cells and complete spermatogenesis. These findings were supported positively by the evidence derived from the observations of the previously indexed studies (7, 10, 12, 14, 15, 18).

However, few studies concluded with the findings of disruption of normal orderly progression of the spermatogonia with tubules showing only one layer of spermatogonia with no changes in interstitial tissue and Leydig cells (16). Furthermore, few authorsalsodocumented the finding of gradual increase in number of spermatogonia with decreased number of spermatocytes and spermatids (17). These findings were not in accordance with the observations of the current study which showed decrease in all types of spermatogenic cells with changes in interstitial tissue.

Some of the seminiferous tubules showed vacuolar spaces as vacuoles have replaced the depleted cells with distorted germinal epithelium and degenerated germinal epithelial cells sloughed into the lumen of tubules. These findings were in concordance with observations of some existing studies (2,10,15,18,19).

The testicular histological changes seen in the present study, thus produced can be attributed to nicotine induced lipid per oxidation and the reduction in testosterone hormone level either directly through decrease of Leydig cells or indirectly by affecting the central nervous system and release of gonadotropin releasing hormones (GnRH) from pituitary.

CONCLUSION:

The observations of current study reinforce that nicotine, which is one of the most active chemicals in tobacco smoke that is acquired by active or passive smoking, is highly toxic and nicotine exposure even with small duration i.e. 5 days, can induce severe histopathological changes. It is also evident from the current study that nicotine not only affects the respiratory organs, as believed earlier, but other reproductive organs, and important among them being testes, also. Thus, affecting the reproductivity and health status of the people exposed to nicotine smoke. Therefore, it is prudent that efforts should be increased to stop smoking and prevent exposure to nicotine smoke at public places and the persons passively exposed to nicotine smoke should be sensitized about the hazards of nicotine exposure. Furthermore, there should be standardized adoption of protective measures in order to mitigate the risks associated with nicotine exposure.

REFERENCES:

1. Akomolafe OR, Imafidon CE, Olukiran OS, Oladele AA, Akanji BO. Sub-acute administration of lower doses of nicotine caused sex-dependent improvement of renal function in Wistar rats. *Toxicology Reports* (4) 2017; 535–42.
2. Oyeyemi WA, Kolawole TA, Shittu ST, Ajah R, Oyeyemi BF**.** Effects of ascorbic acid on reproductive functions of male Wistar albino rats exposed to nicotine. *Journal of African Association of Physiological Sciences*2014; 2(2): 110-16.
3. The American cancer society: Health risks of secondhand smoke 2015.
4. Global Adult Tobacco Survey 2009-2010: Fact sheet India: 2009-2010.
5. Australian Drug Foundation Tobacco Facts: Smoking: what are the effects? ; 2012.
6. Mishra A, Chaturvedi P, Datta S, Sinukumar S, Joshi P,Garg A: Harmful effects of nicotine. *Indian Journal of medical and pediatric Oncology* 2018; 36(1): 24-31.
7. Jana K, Samanta PK, De DK. Nicotine diminishes testicular gametogenesis, steroidogenesis, and steroidogenic acute regulatory protein expression in adult albino rats: Possible influence on pituitary gonadotropins and alteration of testicular antioxidant status. *Toxicol Sci*. 2010; 116:647–59.
8. Oyeyipo I P, Obembe O O, Oladokun OO, Raji Y: Sperm function and fertility profile

Volume 3, Issue4; July-August 2020; Page No.742-749
© 2020 IJMSCR. All Rights Reserved

following nicotine administration in male rats: Protective potentials of *Zingiberofficinale*. *Int J Green Pharm* 2014; *8:125-9.*

9. Aydos K, Guven MC, Can B, Ergun A. Nicotine toxicity to the ultra structure of the testis in rats. *BJU International* 2001; 88: 622-26

10. Hanadi BA, Kelany AHM, ElQudsi FM, Ameen HA, El Karium SA. The possible protective role of antioxidants (selenium, vitamin E) in reducing smoking effects on testes of Albino rats. *Ass. Univ. Bull. Environ. Res.*2011; 14(1): 61-76.

11. Mosadegh M, Hasanzadeh S, Razi M. Nicotine induced damages in testicular tissue of rats; evidences for bcl-2, p53 and caspase -3 expression. *Iranian Journal of Basic Medical Sciences* 2017; 20: 199-08.

12. Autifi MAH, Elsagheir AS, Almandouh MA. Effect of Nicotine on the Testis of Adult Albino Rat and the Possible Protective Effect of Vitamin E. *Nat Sci*2017;15(4):13-19. ISSN 1545-0740 (print); ISSN 2375-7167 (online). http://www.sciencepub.net/nature.doi:10.7537 /marsnsj150417.02.

13. Oyeyipo IP, Raji Y, Emikpe BO &Bolarinwa AF. Effects of Oral Administration of Nicotine on Organ Weight, Serum Testosterone Level and Testicular Histology in Adult Male Rats. *Nig J PhysioSci*2010; 25: 81– 86

14. Noorhafiza R, Majid AM, Hashida NH. Testosterone level and histological features of tualang honey and nicotine treated male rats. *Biomedical Research* 2013; 24(3): 383-88.

15. Coskun G, Ozgur H, Doran S, Polat S. Ameliorating effects of curcumin on nicotine-induced mice testes. *Turkish Journal of Medical Sciences* 2016; 46:549-60.

16. Audi SS, Abraham ME, Borker AS. Effect of cigarette smoke on body weight, food intake and reproductive organs in adult albino rats. *IndianJournal of Experimental Biology* 2006; 44: 562-65.

17. Reddy S, Londonkar R, Ravindra, Reddy S, Patil SB. Testicular changes due to graded doses of nicotine in Albino mice. *Indian J PhysiolPharmacol*1998; 42 (2): 276-80.

18. Gawish AM, Ramadan S, Hassan AM, Issa AM. Morphometrical, histopathological, and cytogenetical ameliorating effects of green tea extract on nicotine toxicity of the testis of rats. *Journal of Cytology and Histology* 2010; 1: 105. doi: 10.4172/ 2157- 7099.1000105.

19. Kolawole TA, Oyeyemi WA, Adigwe C, Leko B, Udeh C, Dapper DV. Honey attenuates the detrimental effects of nicotine on testicular functions in nicotine treated Wistar rats. *Niger. J. Physiol. Sci.* 2015; 30:11-16.

Volume 3, Issue4; July-August 2020; Page No.742-749
© 2020 IJMSCR. All Rights Reserved