(International Print/Online Journal)

SJIF IMPACT FACTOR: 4.617
PUBMED-National Library of Medicine ID-101739732

ISSN (Print): 2209-2870
ISSN (Online): 2209-2862

International Journal of Medical Science and Current Research (IJMSCR)
Available online at: www.ijmscr.com
Volume2, Issue 3, Page No: 189-192
May-June 2019

Bilateral Lower Limb Amputations Following High-Voltage Electrical Injury (HVEI): A Case Report

Bhat A Tanveer[1], Rasool Altaf[1], Wani A Hafiz[1]
[1]Department of Plastic and Reconstructive Surgery, SKIMS,Soura,Srinagar,J &K,India

***Corresponding Author:**

Dr. Tanveer Ahmad Bhat
Senior Resident
Department of Plastic and Reconstructive Surgery
Apartment No G9, Block B,Senior Resident Hostel, SKIMS Soura, Srinagar, J & K
India.PIN 190011

Type of Publication: Case Report
Conflicts of Interest: Nil

ABSTRACT
High tension electric burns are rare but devastating form of injuries**.** The human body conducts electricity very well. Direct contact with electric current can be lethal. The passage of electric current through the body is capable of producing a wide spectrum of injuries, including serious damage to the heart, brain, skin and muscles. Naked high-voltage electric cables negligently abandoned in residential, commercial and industrial areas are a recipe for disaster. This is a case report of a 40-year man who had bilateral lower limb amputation – right side via mid -thigh and left side via distal leg following electrical burns injury with dry gangrene of stumps. He presented with the emergency department in a conscious state but grossly irritable with severe pain and burnt right amputated foot with shoes intact brought by his attendant. His both lower limb stumps were deeply burnt up to mid-thighs, leading to bilateral above knee guillotine amputations**.**

Keywords: High-voltage electric current, bilateral lower limb gangrene, bilateral above knee amputation.

INTRODUCTION

Electricity is omnipresent in our daily life. Unfortunately, electric injury can result in some of the most devastating thermal trauma. It is not uncommon to see high-voltage electric cables haphazardly slung or running across densely populated industrial, residential, or commercial premises in our environment. Sometimes, these cables are 'live' with electricity even as they lie on the ground; hang negligently down from tree tops, and across farmlands, thereby posing serious safety challenges to the populace

Electrical currents can produce diverse and serious injuries to the heart, brain, skin and muscles. The extent of tissue damage following electrical injuries is related to the voltage of the current. High-voltage electrical injuries often produce severe burns and blunt trauma. Such burns are much worse than the thermal burns[1]. Electric burns are responsible for about 3-5% of all burns unit admissions and high-tension electrical injuries are usually from power lines.[2,3,4,5] Mortality depends on the voltage and the electrical contact and is estimated to be 3-15% [2,6]. Lack of access to prompt medical care in well equipped highly specialized units is a contributory factor to poor outcome for these patients.

CASE REPORT: A 14 year-old child sustained a high voltage electrical injury (HVEI) while playing in a playground where a live electric cable had fallen accidently on the ground. On arrival to the hospital,he was alert, grossly irritable and crying with pain. He has around 40 % visible total body surface area burns involving bilateral lower limbs and perineum with amputation of both limbs- right side via mid -thigh and left side via distal leg following

electrical burns injury with dry gangrene of stumps. Primary survey according to ATLS guidelines was normal. He presented with myoglobinuria. The packed cell volume at presentation was 39%. It later dropped to 21% and then 19%. Serum electrolytes, urea and creatinine were within normal limits. The patient was appropriately resuscitated with intravenous fluid, blood transfusion and broad spectrum antibiotics. He had bilateral above knee guillotine amputation through the proximal thighs, at the level where viable tissue was encountered, and diversion colostomy in view of perineal burn wounds. Postoperatively, the patient continued to receive appropriate antibiotics and blood transfusions as required. Nutritional support in the form of amino acid infusions and oral intake of high-protein and high-calorie feeds was instituted.He had daily dressings to the stump and burns wounds. The burns unit undertook subsequent wound care involving resurfacing with split skin grafting of the amputation stumps and residual burn wounds. Physiotherapy to both hips was also institute. Colostomy closure was done after healing of the wounds.The patient remained in hospital for a total of 81 days with initial 2 days in intensive care unit (ICU).

DISCUSSION

Electricity, although an important commodity, has become a significant cause of injury in our society[3]. Electrical injuries are caused by the conduction of electric current through the body. The injuries could be classified into low-voltage (<1000V) and high voltage (>1000V) injuries[3]. Although both low and high-voltage electrical injuries can have devastating effects, the high-voltage electrical injuries tend to produce more extensive tissue damage. Alternating current, the more commonly distributed form, is more dangerous than direct current due to the tetanic muscle spasms it produces and this results in prolonged contact of the victim with the source. The mechanisms of injury include flash burns which results from the luminous bridging that occurs when current is shorted, and the direct conduction of the current through the patient. Indirect injuries, such as fractures either from severe muscle contractions or falls, are also common[3].The high voltage electrical injuries in several instances resulted in the loss of one or more limbs. The percentage of such patients requiring amputation was as high as 86%. Majority of high-tension electrical injuries involve electricity workers. High-tension electrical injuries resulting from contact with either fallen or low lying live high-tension cables in neighborhoods have been documented. High tension electrical injuries make up a much smaller percentage of peadiatric ICU admissions unlike adults since most of these injuries are work related. However contact with exposed high-tension cables located near residential areas as reported in this case could account for a significant proportion of these injuries in children. In developing countries, most patients lack access to prompt medical care in wellequipped highly specialized units. The circumstances that led to the devastating injury in this case highlight the need to establish and enforce adequate safety regulations and enforcements. These include properly locating high-tension electrical cables to prevent accidental contact, prompt repair of fallen high-tension cables, and provision of specially designed wear and ladders for electricity workers. Appropriate education of the public would also help. These measures would reduce the incidence of high-tension electrical injuries which are mostly preventable.

CONCLUSIONS: Despite the devastating nature of this type of electrical injury, all hope is not lost. Prompt appropriate resuscitation as well as early surgical debridement or amputation would save the lives of these patients. With dedicated post-operative physiotheraphy they can very likely return to reasonably useful life.

REFERENCES

1. Handschin AE, Vetter S, Jung FJ,Guggenheim M,Kunzi W, Giovanoli P. A Case –matched controlled studyon high voltage electriv injuries vs thermal burns. J burns care Res.2009:30:400-407 [PubMed]
2. Lee RC. Injury by electrical forces: Pathophysiology, manifestations and therapy. Curr Probl Surg1997; 34(9): 677-764.
3. Spies C, Trohman RG. Narrative review: Electrocution and life threatening electrical injuries. Ann Intern Med Oct2006; 145(7): 531-7.
4. Koumbourlis AC. Electrical injuries. Crit Care Med 2002; 30(11): 424-30.
5. Rai J, Jeschke MG, Barrow RE, Herndon DN. Electrical injuries: A 30-year review. J Trauma 1999; 46(5): 933-6.

Volume 2, Issue 3; May-June 2019; Page No. 189-192

6. Luz DP, Millan LS, Alessi MS. Electrical burns: A retrospective analysis across a 5-year period. Burns2009; 35(7): 1015-9

Photo 1: Showing bilateral amputation of lower limbs with charred stumps following high voltage electric injury (HVEI).

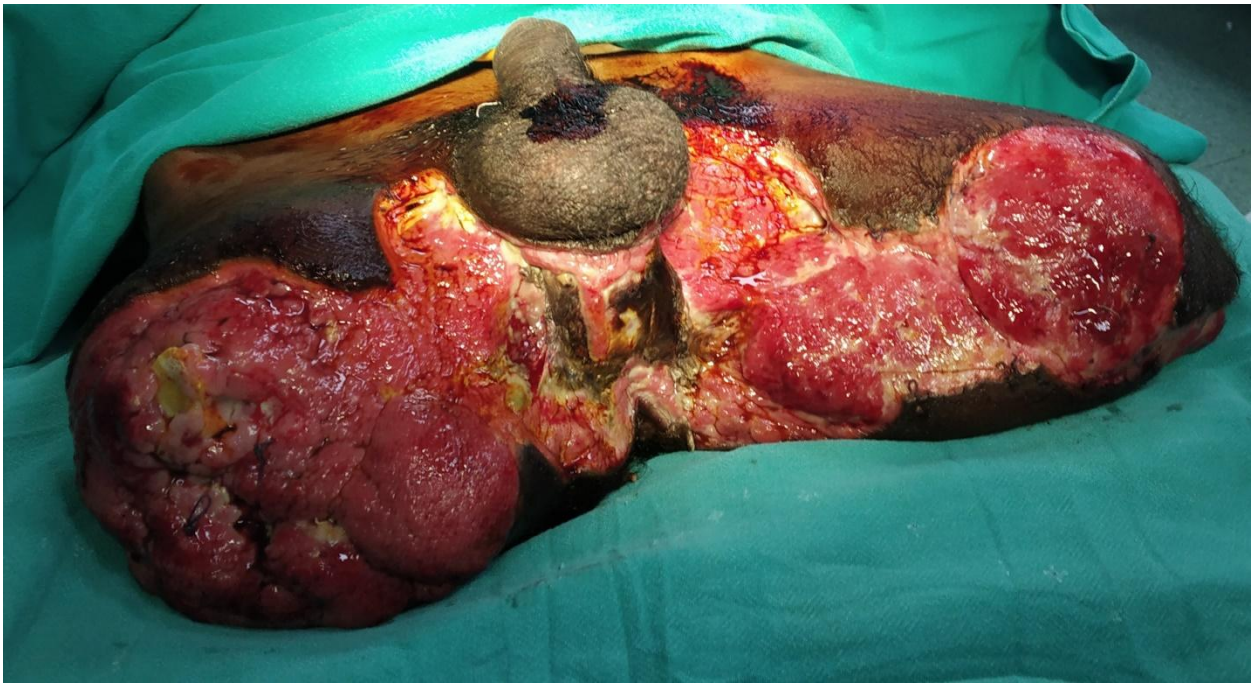

Photo 2: Showing raw areas over the bilateral stumps and perineum after multiple debridements.

Volume 2, Issue 3; May-June 2019; Page No. 189-192

Photo 3: Showing small residual raw area over right stump with healthy soft tissue cover of left stump

Volume 2, Issue 3; May-June 2019; Page No. 189-192