(International Print/Online Journal)

SJIF IMPACT FACTOR: 4.617
GADIF IMPACT FACTOR: 1.49

ISSN (Print): 2209-2870
ISSN (Online): 2209-2862

International Journal of Medical Science and Current Research (IJMSCR)
Available online at: www.ijmscr.com
Volume1, Issue 2, Page No: 197-206
July-August 2018

IJMSCR

To Evaluate the Role of Endoscopic Surgery in the Management of Dry Central Perforation of Tympanic Membrane- A Study of 62 Cases

Dr. S. M. Kanade[1], Dr. Preeti Singh[2*], Dr. Priyadershini Rangari[3]

[1]M.B.B.S., M.S.(ENT), Head And Associate Professor, Department Of Otolaryngology, Rajiv Gandhi Medical College And Chhatrapati Shivaji Maharaj Hospital, Thane, Maharashtra, [2*]M.B.B.S., D.L.O.,D.N.B (ENT), Assistant Professor, Department Of Otolaryngology, SGT Medical College, Gurgaon, Haryana, [3]MDS (Oral Medicine And Radiology), Assistant Professor, Department Of Dentistry, Sri Shankaracharya Medical College, Bhilai, Durg, Chhattisgarh

Corresponding Author:
Dr. Preeti Singh
SGT Medical College, Gurgaon, Haryana, India

Type of Publication: Original Research Paper
Conflicts of Interest: Nil

ABSTRACT

This study aimed to evaluate the role of endoscope in the management of the dry central perforation of tympanic membrane in one year. In this study, there was 90% Graft take up rate with endoscopic approach.

Introduction: Same-day closure of tympanic membrane perforation is a quick and more comfortable procedure for the patients. However, conventional unilateral same-day tympanoplasty or myringoplasty has been rarely performed because of the theoretical risk of postoperative complications.

Methods; 62 patients with unilateral dry tympanic membrane perforations who had some degree of hearing loss corresponding to the size and location of the perforation entered the study. There was no suspicion to disrupted ossicular chain, mastoid involvement or other middle or inner ear pathology. Endoscopic transcanal cartilage tympanoplasty was done using the underlay (medial) technique. The graft was harvested from cymba cartilage in just one ear with preservation of perichondrium in one side. A 1.5 cm × 1.5 cm cartilage seemed to be enough for tympanoplasty in both sides.

Results: sixty two patients (34 males and 28 females) with the mean age of 34.9 years underwent endoscopic tympanoplasty in a same-day surgery. The mean duration of follow up was 12 months. There were detected no complications including hearing loss, otorrhea and wound complication with no retraction pocket or displaced graft during follow-up period. The grafts take rate was 90% (six cases of unilateral incomplete closure). The mean of air-bone gap overall improved from 13.88 dB preoperatively to 9.16 dB postoperatively ($p < 0.05$).

Conclusion: unilateral endoscopic transcanal cartilage tympanoplasty can be considered as a safe minimally invasive procedure that can be performed in a same-day surgery. It reduces the costs and operation time and is practical with a low rate of postoperative complications.

Keywords: MR Urography, Static MRU, Excretory MRU, Urolithiasis

INTRODUCTION

The term tympanoplasty was first coined in1953 by Wullstein to describe surgical technique of reconstruction of the hearing mechanism of the middle ear that had been destroyed by chronic suppurative otitis media [CSOM]1. In 1965, the American Academy of Ophthalmology and Otolaryngology Subcommittee on Conservation of Hearing defined tympanoplasty as “a procedure to eradicate disease in the middle ear and to reconstruct the hearing mechanism with or without tympanic membrane grafting”2.Myringoplasty (tympanoplasty type I) is usually the treatment of choice for perforations of tympanic membrane in CSOM3. Transcanal Tympanoplasty Type I [TET 1] is more advantageous than post-aural approach because of lower operative time and minimal tissue injury4, 5. For decades the use of endoscopes in ear surgery was primarily for anatomical studies of the middle ear and use was limited to simple observations of tympanic cavity through perforations and an adjunctive method to aid traditional microscopic procedures6, 7. However, in the last two decades it has been used

exclusively for otologic surgical procedures which were earlier classically performed by operating microscopes, such as myringoplasty, ossiculoplasty, stapedotomies and cholesteatoma surgeries7, 8.

The endoscope is equipment used successfully in several procedures of several medical specialties. In our specialty, the endoscopes are extremely useful and currently they are very common for surgeries of nose, paranasal sinuses and cranial base. In these areas, the endoscope has practically replaced the microscope for it offers some advantages, such as the excellent viewing of structures, large angular image, viewing in several angles and magnification. Mer and colleagues introduced the middle ear endoscopy in 1967. Endoscopic ear surgery, first tried in the 1990s. Advantages of endoscopic ear surgery compared to the conventional microscopic surgery include avoiding endaural vertical and postauricular incisions.

The endoscopic approach has following advantages over microscopic approach:-

Shorter operation time,

Reduced postoperative pain level,

Better cosmetic results,

Better surgical view with minimal incision,

High success graft take up rate,

Better postoperative hearing improvement,

Provides better visualization of hidden areas in the middle ear cavity including the anterior and posterior epitympanic spaces, sinus tympani, facial recess and hypotympanum.

Thus endoscopic tympanoplasty can be a good alternative of microscopic tympanoplasty.

The endoscopic approach However, endoscopic surgery has several disadvantages.

Only one-hand surgery; in a situation of massive bleeding, the endoscopic view could be stained by blood and continuing the procedure could be difficult.

Endoscopic instrument can make direct injury.

Thermal damage by light source

MATERIAL AND METHODS

The present study was conducted in the Department Of Otolaryngology, Rajiv Gandhi Medical College and Chhatrapati Shivaji Maharaj Hospital, Thane, Maharashtra, India. The study was performed in one year period from January 2017 t0 January 2018.

Surgery was performed with endoscope held in one hand and the surgical instruments in other. We primarily used the 0-degree endoscope with the 30-degree. A total of 50 patients were selected having central perforation of tympanic membrane.

In our study, all 62 patients underwent preoperative assessment with proper history and examination, otoscopic examination, endoscopic examination, tuning fork test, pure tune audiometry, xylocaine sensitivity test, X-ray mastoid & X-ray PNS and routine blood investigations.

The present study was conducted on 62 patients of age group 12 to 60 years with dry central perforation, small and medium in size. Male to female ratio was 2:3 (20 male and 30 female).

Advantages and disadvantages of endoscopic approach

Advantages

Endoscopes provide a wider and angled view of the fine structures in the middle ear9 (Fig. 2).

Do not require large incisions (postauricular, endaural incisions).

Do not require curettage, range or canalplasty of the external ear canal.

Operation time is shorter.

Provide less postoperative pain and sooner recovery.

Provide better cosmetic outcomes10, 11.

Monitor used during endoscopic surgery provides visual content for training purposes9.

Hidden deep regions, such as the anterior tympanic perforation, facial recess and hypotympanum can be directly visualized.

Contrary to microscopy, views can be obtained from more than one angle.

High-resolution and relatively clear images can be obtained.

Disadvantages

Volume 1, Issue 2; July-August 2018; Page No. 197-206

Surgical manipulations must be performed using a single hand9.

Since the monitor provides two-dimensional views, depth perception can be difficult.

Mist may frequently accumulate over the endoscope.

Requires good hemostasis of the external ear canal.

Potential harm to surrounding structures caused by heat produced from the endoscope's light source is also a matter of concern.10, 12

The field of magnification is limited.

Requires training.

Indications for endoscopic ear surgery

Tympanic membrane perforation repair (myringoplasty and tympanoplasty),

Limited cholesteatoma, otosclerosis, round window fistula repair,

ventilation tube insertion,

Eustachian tube dilation.13, 14, 15

Contraindications for endoscopic ear surgery

Extensive middle ear cholesteatoma involving the mastoid,

Presence of obstruction and exostosis in the external ear canal preventing endoscopic access.

Insufficient equipment availability.[16]

Endoscopic ear surgery techniques

Endoscopic ear surgery should preferably be performed under hypotensive anesthesia, and the patient should be placed in an appropriate position following the administration of local anesthetics to the field of surgery and adequate local hemostasis must be obtained.

The following factors should be considered during endoscopic exploration of the middle ear:

Status of the ossicles,
Incudostapedial joint,
Eustachian tube,
Oval and round windows

Endoscopic type 1 tympanoplasty

The entire procedure can be performed using the transcanal approach. Each step of the surgical techniques is the same as the conventional transcanal microscopic myringoplasty.

Surgical technique: Rigid endoscopes of 2.7 mm and 4 mm in diameter, 0_ and 16e18 cm in length are used. The ear canal is cleaned and inspected. First, the perforation and status of middle ear mucosa are examined. Local anesthetic, including epinephrine at a concentration of 1/100,000, is injected into the four quadrants of the outer ear canal.

Perforation edges are de-epithelized, as appropriate. Calcified plaque in the tympanic membrane, if any, is removed. Tragal perichondrium, temporalis muscle fascia, conchal, or tragal cartilage graft is harvested. In the external ear canal, any one of the swing door, lateral circumferential or endaural incisions or other types of incisions can be used. Elevating the tympanomeatal flap and the annulus provides access to the middle ear. Continuity and movements of the ossicles and integrity of the middle ear are checked. The malleus is separated from the tympanic membrane using a pick. Ossicular chain repair can be performed if required. The prepared graft is placed lateral to the malleus and medial (over-underlay) to the membrane remnant. To complete the operation, sponges are placed in middle ear and outer ear canal.17, 18, 19, 20(Fig 3)

Endoscopic butterfly myringoplasty

First defined by Eavey (1998), butterfly myringoplasty is an inlay technique using a cartilage graft.21 It is performed for nonmarginal perforations. The ossicular chain should be intact. It can even be performed in the presence of near total perforation.21, 22

Surgical technique: The procedure is carried out under general anesthesia. Perforation in the tympanic membrane is first evaluated by a 0_ rigid endoscope of 2.7 mm or 4 mm in diameter. Perforation edges are de-epithelized. The status of the middle ear and ossicles is checked through the perforation. The size of the perforation is measured by an angled pick. From the tragal cartilage graft is prepared, with perichondrium on both sides. A 0.5e1 mm groove is opened all around the cartilage. This graft should be 0.5 mm wider than the perforation. The graft is placed medial to the membrane transcanally under the endoscope and its position is carefully checked using an aspirator and pick. Before terminating the

Volume 1, Issue 2; July-August 2018; Page No. 197-206

operation, gel-foam is placed at the borders of the graft and the membrane. The endoscopic inlay cartilage butterfly myringoplasty technique does not require tympanomeatal flap or a postauricular incision. Tympanosclerotic plaque in the tympanic membrane may not be removed.23 (Fig. 4).

Surgical steps:

All operations were performed under local anesthesia except in children below 15 years of age.The patients were pre-medicated with intramuscular injections of 1 ampule fortwin and 1 ampule phenergan.

The external auditory canal was then anesthetized using 2 % xylocaine mixed with 1 in 10,000 adrenaline injection. About 1/2 cc is infiltrated at 3 - o clock, 6 - o clock, 9 - o clock, and 12 - o clock positions about 3mm from the annulus.

Step I: Freshening the margins of perforation, Step II: elevation of tympanomeatal flap, Step III: Elevation of the annulus and incising the middle ear mucosa. Step IV: Freeing the tympano meatal flap from the handle of malleus. Step V: Placement of graft (underlay technique). Step: VI The tympano meatal flap is repositioned and gel foam fill in external auditory canal.

RESULTS

The overall Graft take up rate was 90 % in our study with endoscopic approach. There were only 2 cases of graft failure. Complete graft uptake rate was 97.29% and 92.30% respectively for temporalis fascia and tragal cartilage. The average time taken for endoscope assisted tympanoplasty was around 60-70 minutes. At three months follow up 30 patients had postop A-B gap in the range of 0 to 10 dB, while 20 patients had postop A-B gap in the range of 11-20 db.

In our study, according to PTA finding, 43 patients had pure conductive hearing loss (average 35-40dB) & 7 patients had mixed hearing loss (30-35dB). In 37 patients we used temporalis fascia and in 13 patients tragal cartilage was used as graft material.

DISCUSSION

Endoscopic ear surgery was first applied to cholesteatoma removal and myringoplasty. Indications are increasing and include middle ear tumor, ossiculoplasty, tympanoplasty, and cochlear implantation.27 Several meta-analyses and review articles of endoscopic ear surgery support the safety of the approach, with minimal morbidity evident26, 27, 28. Since the endoscopic technique was introduced for middle ear surgery, the concept of minimally invasive surgery has developed. This could avoid mastoidectomy, external incisions, and soft tissue dissection in selected cases as compared with the conventional microscopic approach24, 25.

Endoscopic approach to the middle ear and tympanic cavity is a practical, minimally invasive and conservative technique in comparison to the traditional surgical approaches. In this method, there will be no more need to use several flaps or performing canaloplasty. As a result, there will be no disturbance in the external ear blood circulation. Postoperative ear packing in conventional surgeries, which leads to considerable hearing loss and causes a transient activity limitation to the patient, is not applied in endoscopic method since all the procedure is done with only few stiches in cartilage harvesting site without any other post-auricular incisions.7

Endoscopic tympanoplasty is time saving and anatomy of the middle ear will be preserved. This procedure does not require surgical exposure such as canal drilling and skin incision, and avoids the substantial risk of unnecessary injury to the chorda tympani, in contrast to conventional methods. Less pain, reduced demand for analgesics and reduced time of operation and a shorter period of follow-up are the other advantages of the endoscopic method. Something that makes this procedure unique is the possibility of performing bilateral tympanoplasty at the same time without a necessarily general anesthesia. Three of our cases in this study received sedation and the other six patients received general anesthesia. In the cases of the selected patients with underlying medical problems or patients' own preference, intravenous sedation can be done instead of general anesthesia. Endoscopic tympanoplasty is possible to be performed with 0 or 30 degree telescopes with no need to any bone drilling. Since microscope is not used during the procedure and it is possible to see the ossicular chain and the middle ear through a 30 degree telescope. This method is particular useful in cases of anterior canal overhang without need to remove the overhang.29

Endoscopes can provide magnified views of the surgical field. Microscopes require image adjustment during operation. Visualization of deep and hidden

Volume 1, Issue 2; July-August 2018; Page No. 197-206

spaces involving sinus tympani, epitympanum, facial recess, and the attic area are limited with a microscope.

An endoscopic approach to the middle ear can improve visualization of structures, such as the tubal orifice, incudostapedial joint and oval/ round window niches.

The endoscopic technique have following advantages compared with microscopic tympanoplasty:-Shorter operation time, reduced post-operative pain level, Better cosmetic results ,Better surgical view with minimal incision, High success graft take up rate and Better post-operative hearing improvement.

There are some major drawbacks with endoscopic ear surgery.

Heat generated by xenon light sources. As a solution to this problem, the routinely used light source can be adjusted to operate at a lower power level.

The second drawback is the trauma, which may result from unintentional head movements by the patient.

Only one-handed surgery is feasible with the endoscopic technique, which is less efficient; in a situation of massive bleeding.

CONCLUSION

The endoscopic approach has introduced a new perspective to ear surgery. When compared with microscopes, endoscopes can provide larger and better images of the middle ear. Using this method, both improved cosmetic outcomes and reduced postoperative morbidity can be achieved.

It can be performed and taught in academic institutions in the residency program in department of Otorhinolaryngology. It can replace the conventional microscopic surgery in future.

Bilateral endoscopic transcanal cartilage tympanoplasty is a safe minimally invasive procedure that can be performed in a same-day surgery. It reduces the costs and operation time and is practical with a low rate of postoperative complications.

REFERENCES

1. Wullstein H. Die Tympanoplastik als gehorverbessernde Operation bei Otitis Media chronica und ihr Resltate. In: Proceedings of the Fifth International Congress on Otorhinolaryngology. 1953.
2. Committee on Conservation of Hearing, America Academy of Ophthalmology and Otolaryngology: standard classification for surgery of chronic ear disease. Arch. Otol. 1965; 81: 204.
3. Tawab A, Gharib F, El Sharkawy L, Algarf T. Myringoplasty with and without cortical
4. Mastoidectomy in treatment of non-cholesteatomatous chronic otitis media: a comparative study. Clin Med Insights, Ear Nose Throat. 2014; 7: 19- 23.
5. Hong P, Bance M, Gratzer PF. Repair of tympanic membrane perforation using novel adjuvant therapies: a contemporary review of experimental and tissue engineering studies. Int J Pediatr Otorhinolaryngol. 2013; 77: 3-12.
6. Ayache S. Cartilaginous myringoplasty: the endoscopic transcanal procedure. Eur Arch Otorhinolaryngol. 2013; 270:853- 60.
7. Marchioni D, Molteni G, Presutti L. Endoscopic anatomy of the middle ear. Indian J Otolaryngol Head Neck Surg. 2011; 63:101-13.
8. Tarabichi M. Endoscopic transcanal middle ear surgery. Indian J Otolaryngol Head Neck Surg. 2010; 62: 6- 24.
9. Mohindra S, Panda NK. Ear surgery without microscope: is it possible? Indian J Otolaryngol Head Neck Surg, 2010; 62: 138-41.
10. Kojima, H., Komori, M., Chikazawa, S., Yaguchi, Y., Yamamoto, K., Chujo, K., Moriyama, H., Comparison between endoscopic and microscopic stapes surgery. Laryngoscope. 2014 124 (1), 266- 71.
11. Badr-El-Dine, M., James, A.L., Panetti, G., Marchioni, D., Presutti, L, Nogueira, J.F., 2013 Apr. Instrumentation and technologies in endoscopic ear surgery. Otolaryngol. Clin. North Am. 46 (2), 211- 25.
12. Surmelioglu O, Ozdemir S, Tarkan O, Tuncer U. Transcanal endoscopic tympanoplasty in

Volume 1, Issue 2; July-August 2018; Page No. 197-206

the treatment of chronic otitis media.Kulak Burun Bogaz Ihtis Derg. 2014; 24: 330- 3.

13. Furukawa, T., Watanabe, T., Ito, T., Kubota, T., Kakehata, S., Apr. Feasibility and advantages of transcanal endoscopic myringoplasty. Otol. Neurotol. 2014, 35: 4: 140- 5.
14. Tarabichi, M., Jun. Endoscopic management of cholesteatoma: long-term results. Otolaryngol. Head Neck Surg. 2000, 122: 6: 874- 81.
15. El-Guindy A. Endoscopic transcanal myringoplasty. The Journal of Laryngology and Otology. 1992;106: 493–5.
16. Karhuketo TS, Ilomaki JH, Puhakka HJ. Tympanoscope-Assisted Myringoplasty. Otorhinolaryngology. 2001; 63: 353– 7.
17. Nogueira JF. Endoscopic ear surgery. Dissection manual.
18. Sheehy, J.L., Anderson, R.G., JuleAug. Myringoplasty. A review of 472 cases. Ann. Otol. Rhinol. Laryngol, 1980, 4: 1: 331- 34.
19. Halim, A., Borgstein, J., 2009 Nov. Pediatric myringoplasty: postaural versus transmeatal approach. Int. J. Pediatr. Otorhinolaryngol. 2009, 73: 11; 1580- 83.
20. Sakagami, M., Mishiro, Y., Tsuzuki, K., Seo, T., Sone, M, Bilateral same day surgery for bilateral perforated chronic otitis media. Auris Nasus Larynx. 2000, 27: 1: 35- 38.
21. Awad, O.G., Hamid, K.A., Endoscopic type 1 tympanoplasty in pediatric patients using tragal cartilage. JAMA Otolaryngol. Head Neck Surg. 2015, 141: 6: 532- 38.
22. .Eavey, R.D., Inlay tympanoplasty: cartilage butterfly technique Laryngoscope, 1998, 108: 5: 657- 61.
23. Hod R., Buda, I., Hazan, A., Nageris, B.I., Inlay “butterfly” cartilage tympanoplasty. Am. J. Otolaryngol. 2013, 34: 1: 41- 43
24. Akyigit, A., Karlidag, T., Keles, E., Kaygusuz, I., Yalcın, S., Polat, C., Eroglu, O., Endoscopic cartilage butterfly myringoplasty in children. Auris Nasus Larynx. 2016, 16: 30: 154-7.
25. Presutti L, Marchioni D, Mattioli F, Villari D, Alicandri-Ciufelli M. Endoscopic management of acquired cholesteatoma: our experience. J Otolaryngol Head Neck Surg. 2008; 37: 4: 481-7.
26. Marchioni D, Mattioli F, Alicandri-Ciufelli M, Presutti L. Endoscopic approach to tensor folds in patients with attic cholesteatoma. Acta Otolaryngol. 2009; 129: 9: 946-54.
27. Presutti L, Gioacchini FM, Alicandri-Ciufelli M, Villari D, Marchioni D. Results of endoscopic middle ear surgery for cholesteatoma treatment: a systematic review. Acta Otorhinolaryngol Ital. 2014, 34: 3:153-7.
28. Kozin ED, Gulati S, Kaplan AB, Lehmann AE, Remenschneider AK, Landegger LD, et al. Systematic review of outcomes following observational and operative endoscopic middle ear surgery. Laryngoscope. 2015; 125: 5:1205-14.
29. Marchioni D, Alicandri-Ciufelli M, Gioacchini FM, Bonali M, Presutti L. Transcanal endoscopic treatment of benign middle ear neoplasms. Eur Arch Otorhinolaryngol. 2013; 270: 12: 2997-3004.
30. Alicandri-Ciufelli M, Marchioni D, Grammatica A, Soloperto D, Carpeggiani P, Monzani D, et al. Tympanoplasty: an up-to-date pictorial review. J Neuroradiol. 2012; 39: 149- 57
31. Daneshi A, Jahandide H, Daneshvar A, Safdarian M. Bilateral same-day endoscopic transcanal cartilagetympanoplasty: initial results. Braz J Otorhinolaryngol. 2017; 83: 411-5.
32. Raghuwanshi SK, Asati DP. Outcome of single sitting bilateral type 1 tympanoplasty in Indian patients. Indian J Otolaryngol Head Neck Surg. 2013; 65: 622- 6.
33. Yu MS, Yoon TH. Bilateral same day surgery for bilateral perforated chronic otitis media: inlay butterfly cartilage myringoplasty. Otolaryngol Head Neck Surg. 2010; 143:669-72.

Volume 1, Issue 2; July-August 2018; Page No. 197-206

34. Palva T, Karja J, Palva A. High-tone sensorineural losses following chronic ear surgery. Arch Otolaryngol. 1973; 98: 176- 8.

35. Smyth GD. Sensorineural hearing loss in chronic ear surgery. Ann Otol Rhinol Laryngol. 1977; 86: 3- 8.

36. Tos M, Lau T, Plate S. Sensorineural hearing loss following chronic ear surgery. Ann Otol Rhinol Laryngol. 1984; 93: 403-9.

37. Tos M. Cartilage tympanoplasty methods: proposal of a classification. Otolaryngol Head Neck Surg. 2008; 139: 747-58.

38. Bottrill I, Perrault DF Jr, Poe D. In vitro and in vivo determination of the thermal effect of middle ear endoscopy. Laryngoscope. 1996 Feb; 106: 2: 1:213-6.

39. Lempert J. Endaural, antauricular surgical approach to the temporal bone principles involved in this new approach: summary report of 1,780 cases. Arch Otolaryngol. 1938; 27: 5: 555-87.

40. Gulya AJ, Minor LB, Poe DS. Glasscock-Shambaugh's surgery of the ear. 6th ed. Shelton, CT: People's Medical Publishing House-USA; 2010.

41. Dundar R, Kulduk E, Soy FK, Aslan M, Hanci D, Muluk NB, et al. Endoscopic versus microscopic approach to type 1 tympanoplasty in children. Int J Pediatr Otorhinolaryngol. 2014; 78: 7: 1084-9.

42. Tarabichi M. Transcanal endoscopic management of cholesteatoma. Otol Neurotol. 2010; 31: 4: 580- 8.

43. Tarabichi, M., Endoscopic management of acquired cholesteatoma. Am. J. Otol. 1997, 18: 5: 544- 49.

44. Sarkar, S., Dec. A review on the history of tympanoplasty. Indian J. Otolaryngol. Head Neck Surg. 2013: 65: 3, 455- 60.

45. Tarabichi M. Endoscopic Middle Ear Surgery. Annals of Otology, Rhinology and Laryngology 1999; 108: 39– 46.

46. Usami S, Iijima N, Fujita S, et al. Endoscope-assisted Myringoplasty. Otorhinolaryngology. 2001; 63: 287– 90.

47. Raj A, Meher R. Endoscopic transcanal myringoplasty– A study. Indian Journal of Otolaryngology and Head and Neck Surgery. 2001: 53: 47–9.

48. Tarabichi M. Endoscopic management of limited attic cholesteatoma. Laryngoscope. 2004; 114: 7:1157-62.

49. Glasscock and Shambaugh. "Tympanoplasty", In Glasscock and Shambaugh, Surgery of the Ear 5th edition, chapter, 2003; 16: 350–70

Volume 1, Issue 2; July-August 2018; Page No. 197-206

TABLES, GRAPHS AND FIGURES

Table : 1 According to age

Age (years)	No of cases
<15	6
20-30	12
31-40	14
41-50	17
51-60	15
Total cases	62

Table 2: According to gender

Gender	No of cases
Male	20
Female	30

Table 3: According to PTA finding

Type of hearing loss	PTA finding (average db loss)	No of cases
Pure conductive hearing loss	35-40 db	43
Mixed hearing loss	30-35 db	07

Volume 1, Issue 2; July-August 2018; Page No. 197-206

Table 4: According to graft material used

Type of graft material	No of cases
1.Temporalis fascia	36
2. Tragal cartilage	26

Graph 1: Gender Distribution

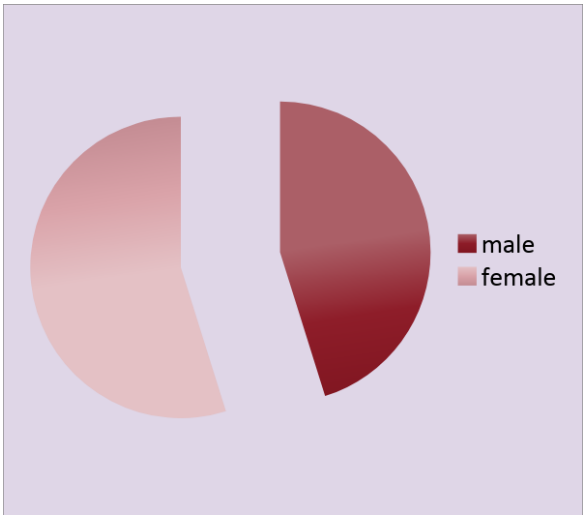

Graph 2: According to graft material used

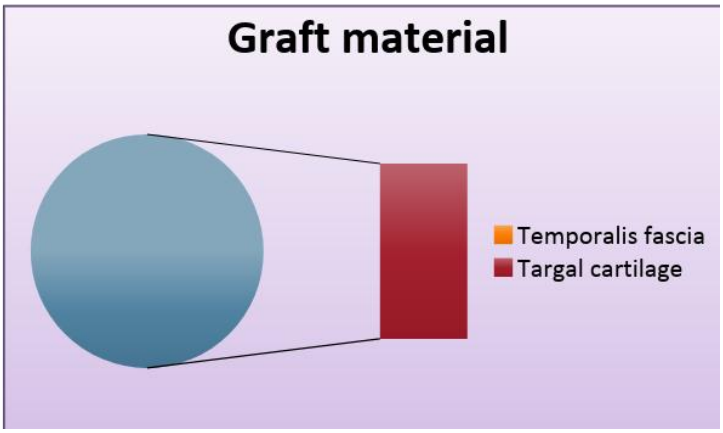

Volume 1, Issue 2; July-August 2018; Page No. 197-206

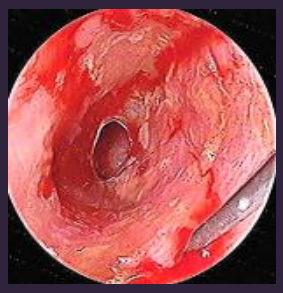		
A. Local Anesthesia infiltration at 3 o'clock, 6 o'clock, 9 o' clock and 12 o'clock positions.	**B. Freshening the margins of perforation**	**C. Inscison and elevation of tympanomeatal flap.**
		
D. Freeing of tympanomeatal flap from the handle of malleus.	**E. Placement of graft (underlay technique).**	**F. The tympanomeatal flap is repositioned and gel foam filled.**

Volume 1, Issue 2; July-August 2018; Page No. 197-206